

CLASSIFICATION OF THE CUTANEOUS MANIFESTATIONS OF COVID-19: A RAPID PROSPECTIVE NATIONWIDE CONSENSUS STUDY IN SPAIN WITH 375 CASES.

Supplementary material: Photographic atlas

C. Galván Casas* , A. Català* , G. Carretero Hernández , P. Rodríguez-Jiménez , D. Fernández Nieto , A. Rodríguez-Villa Lario , I. Navarro Fernández , R. Ruiz-Villaverde , D. Falkenhain , M. Llamas Velasco , J. García-Gavín , O. Baniandrés , C. González-Cruz , V. Morillas-Lahuerta , X. Cubiró , I. Figueras Nart , G. Selda-Enriquez , J. Romaní , X. Fustà-Novell , A. Melian-Olivera , M. Roncero Riesco , P. Burgos-Blasco , J. Sola Ortigosa , M. Feito Rodriguez , I. García-Doval

British Journal of Dermatology 2020

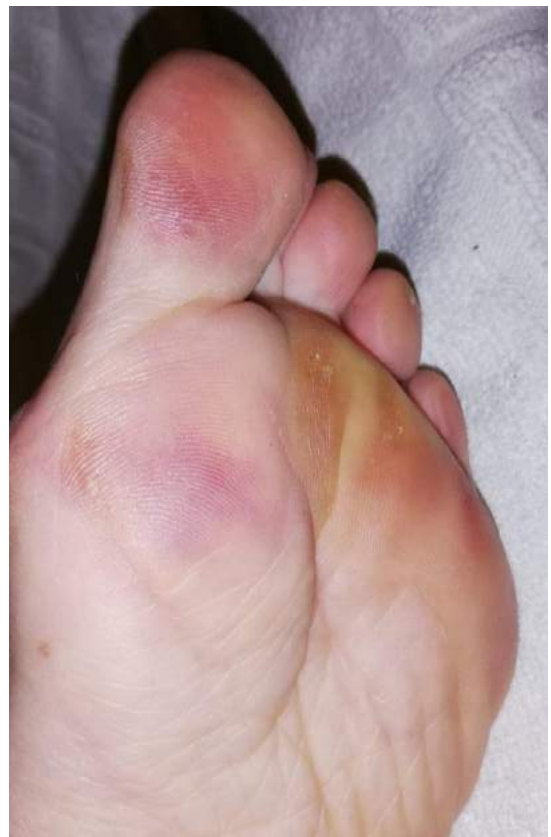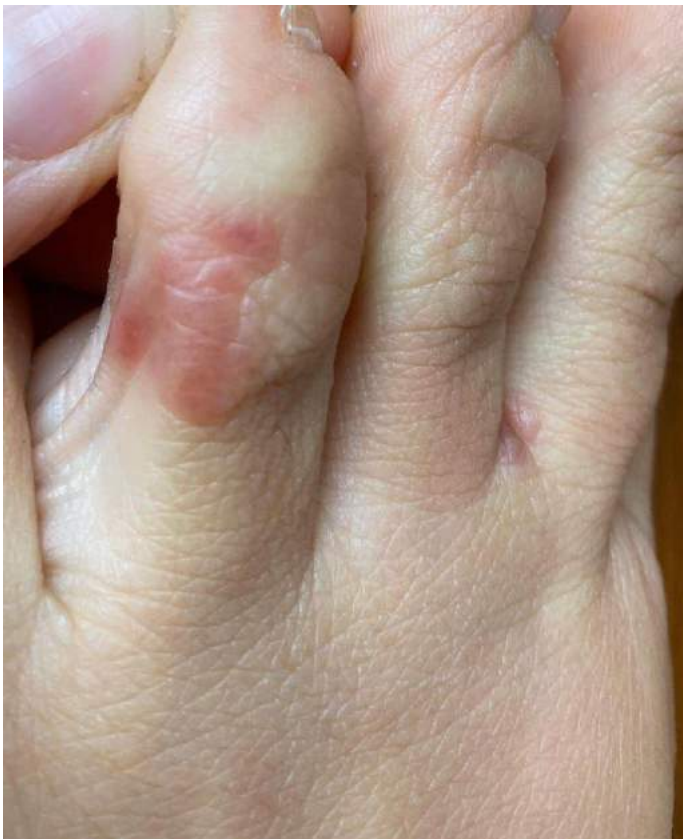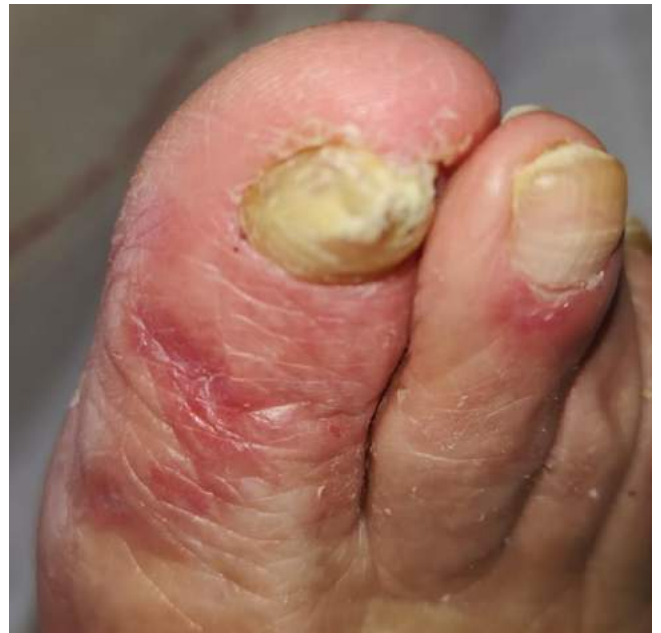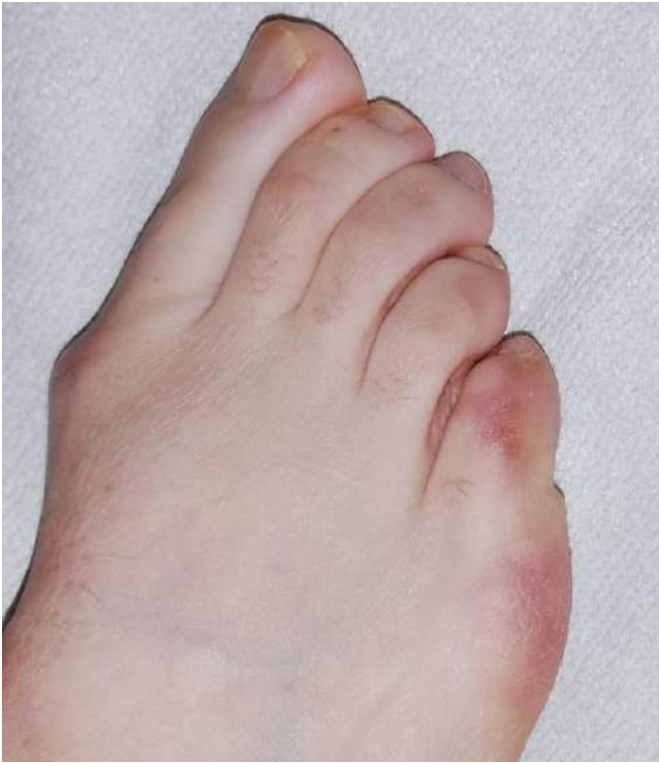©This material is subject to copyright (19th April 2020). Patients
have authorized the reproduction for research and teaching.

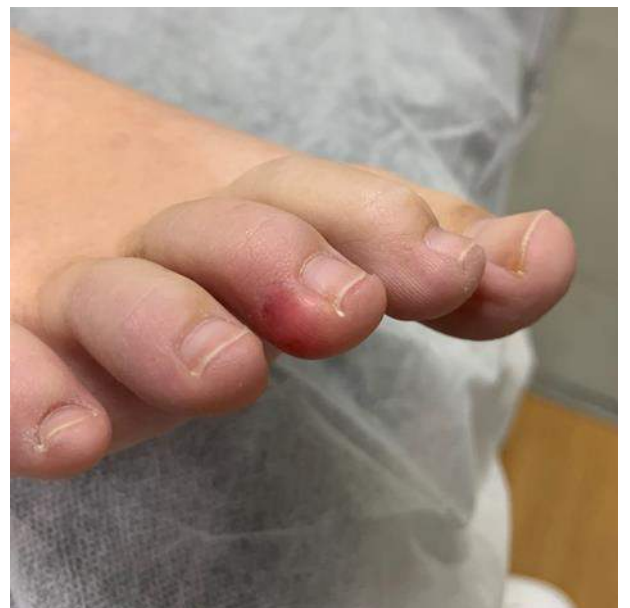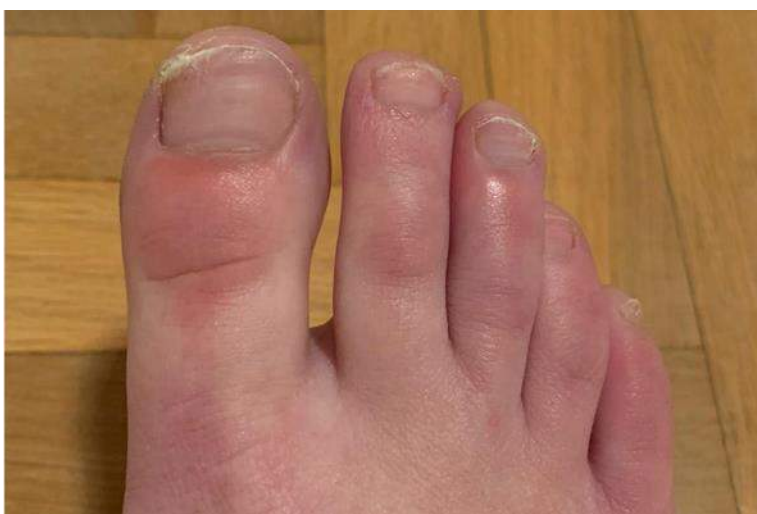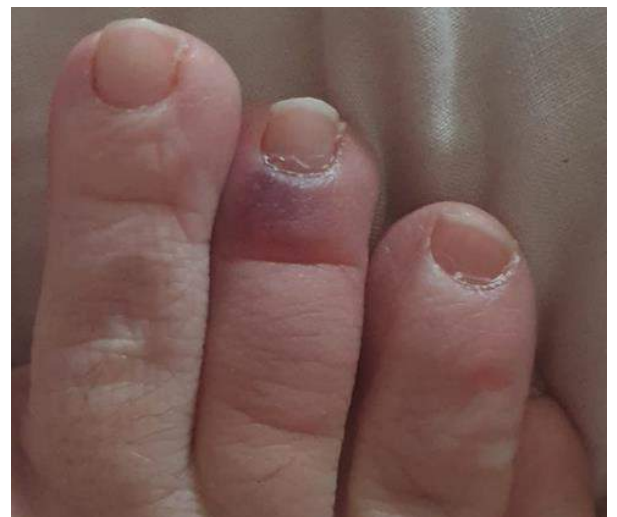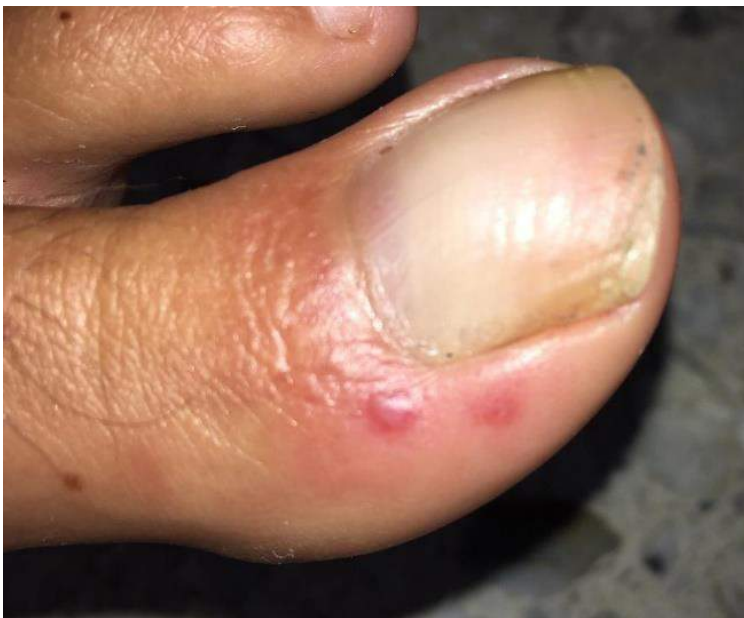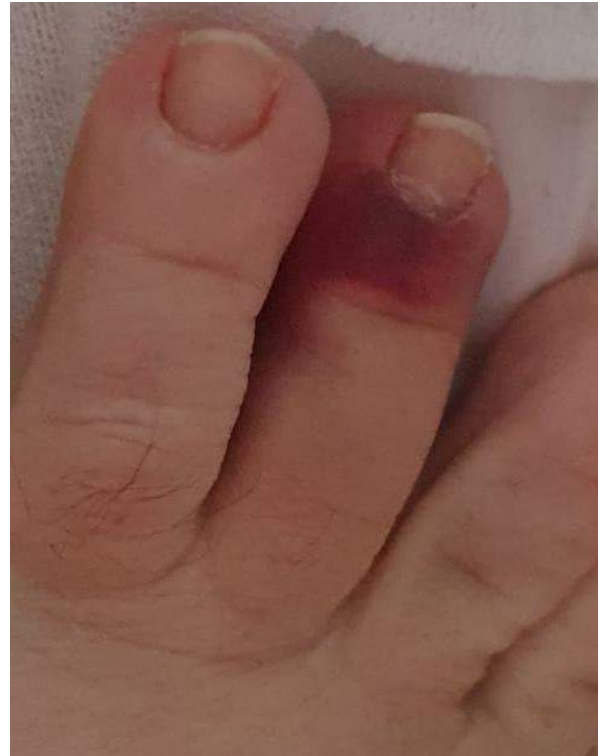
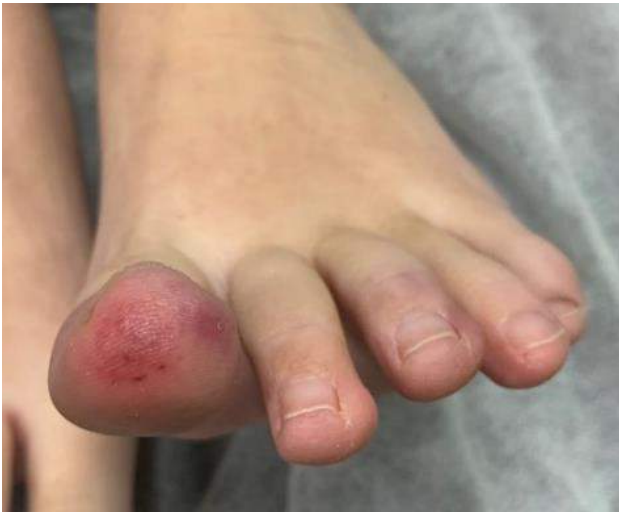Any other use is forbidden.

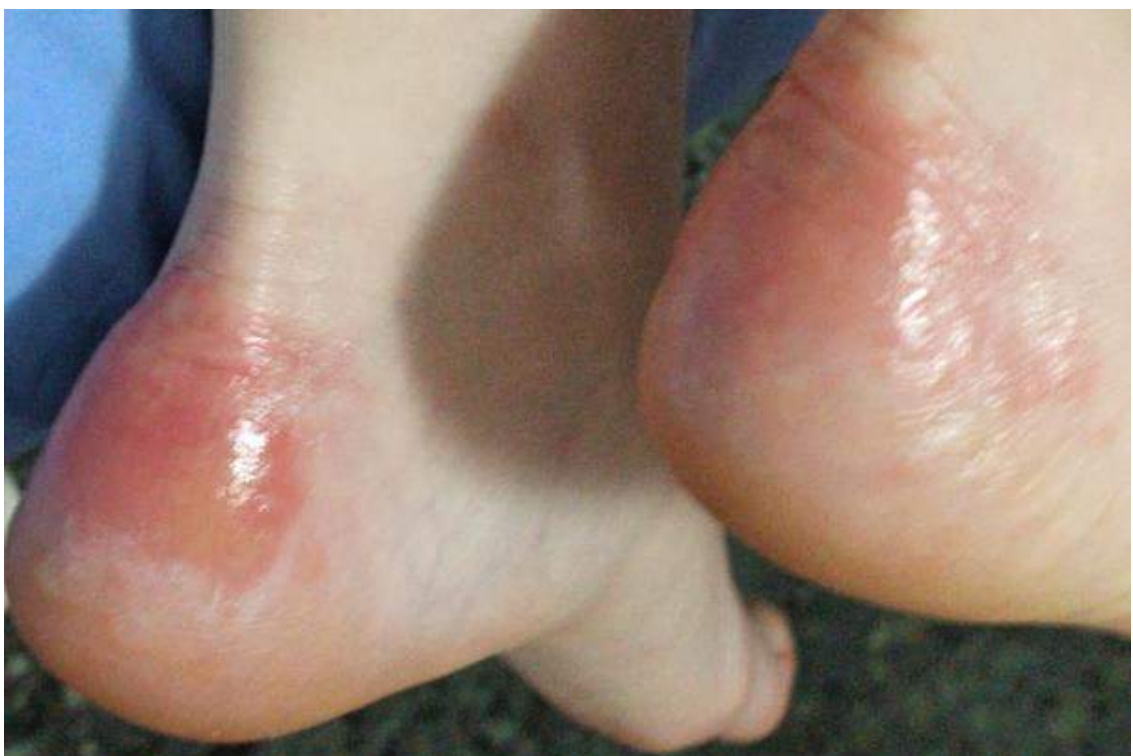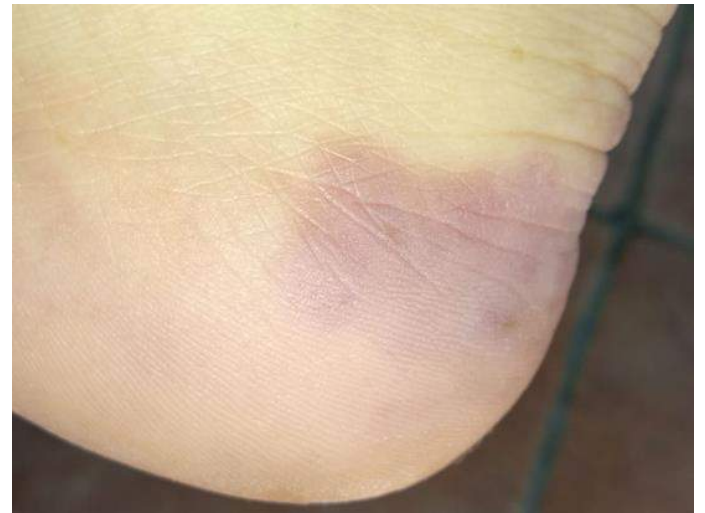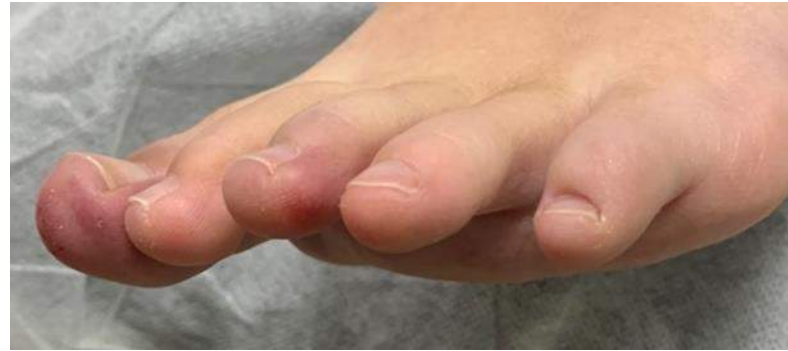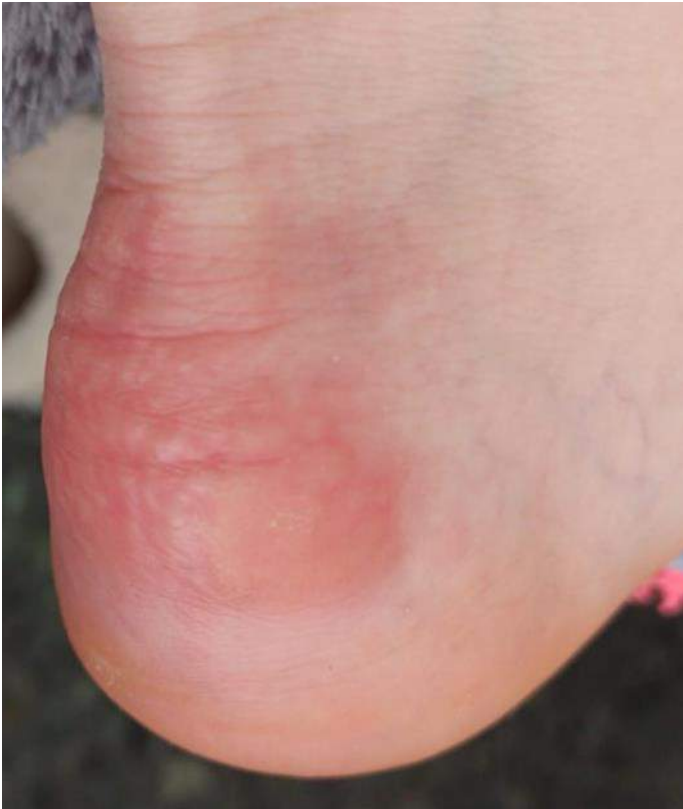Index

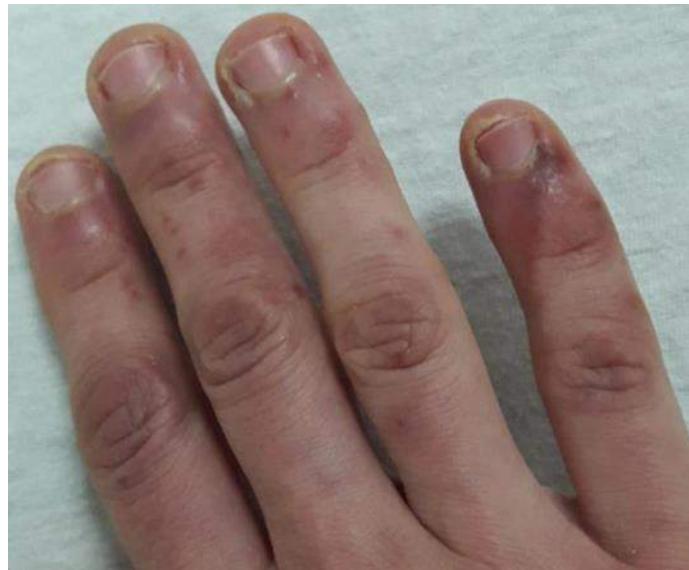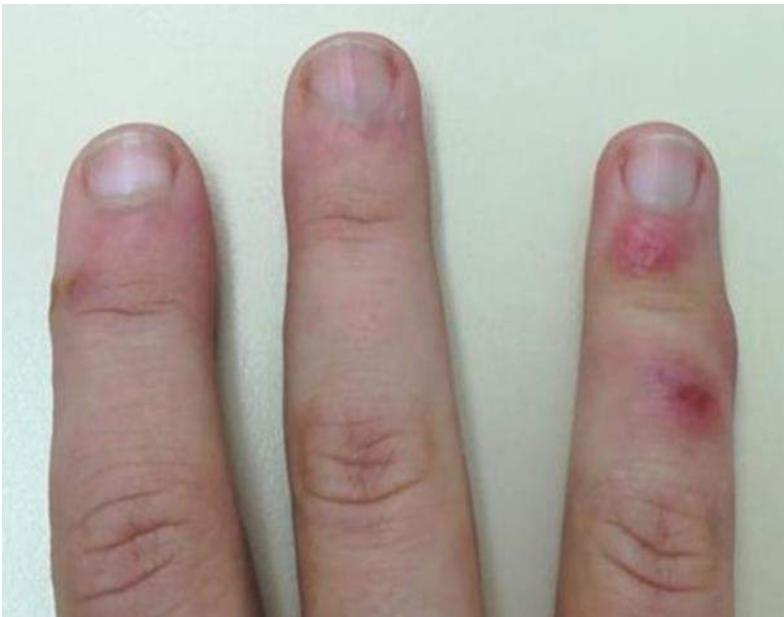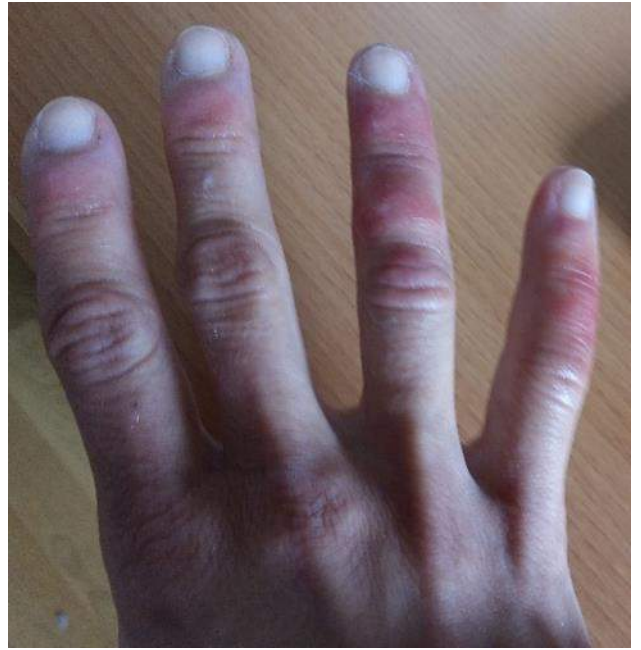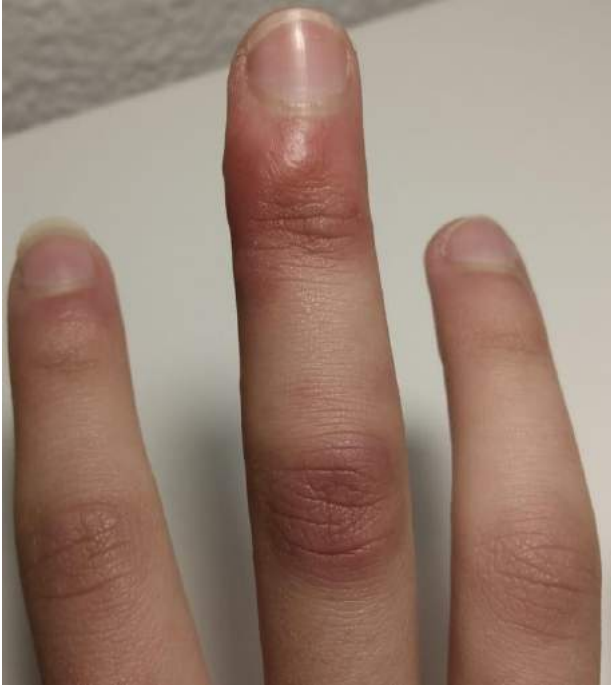Pseudo-chilblain – Confirmed cases.....	2
Pseudo-chilblain – Suspected cases	7
Vesicular Eruption – Confirmed cases.....	17
Vesicular Eruption – Suspected cases	26
Urticarial Eruption – Confirmed cases	39
Urticarial Eruption – Suspected cases.....	48
Maculopapular eruption – Confirmed cases.....	52
Pityriasis rosea-like	52
Perifollicular eruption	55
Erythema multiforme-like	57
Pseudovesicular or resembling erythema elevatum diutinum	59
Purpuric eruptions.....	60
Bilateral axillary purpuric eruption	62
Morbilliform eruptions.....	64
Palmar erythema.....	66
Erythema	67
Maculopapular eruption – Suspected cases	68
Pityriasis rosea-like.....	68
Perifollicular eruption	72
Erythema multiforme-like	74
Pseudovesicular or resembling erythema elevatum diutinum	77
Purpuric eruption	82
Bilateral axillary purpuric eruption	83
Morbilliform eruptions.....	84
Palmar erythema.....	86
Erythema	87
Livedoid or necrotic lesions - Confirmed cases.....	88
Livedoid or necrotic lesions - Suspected cases	94

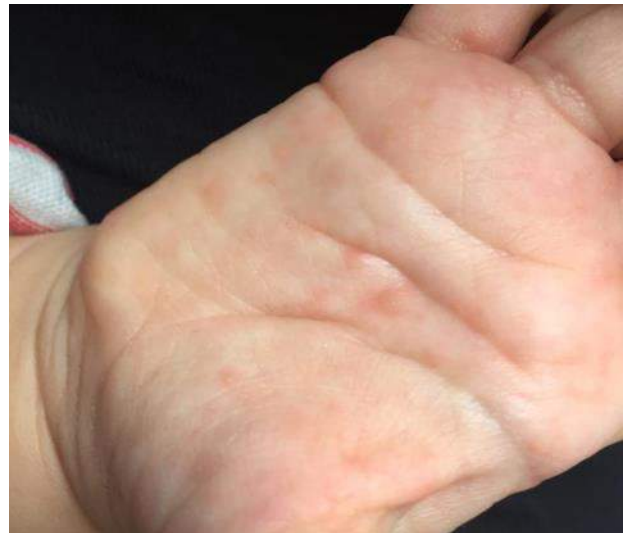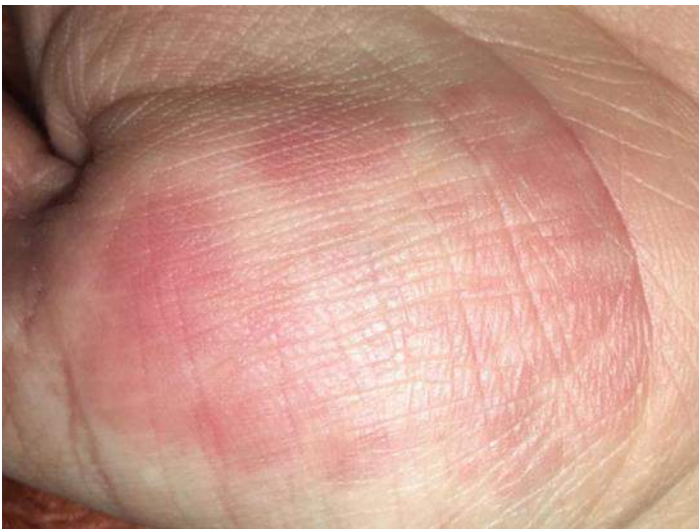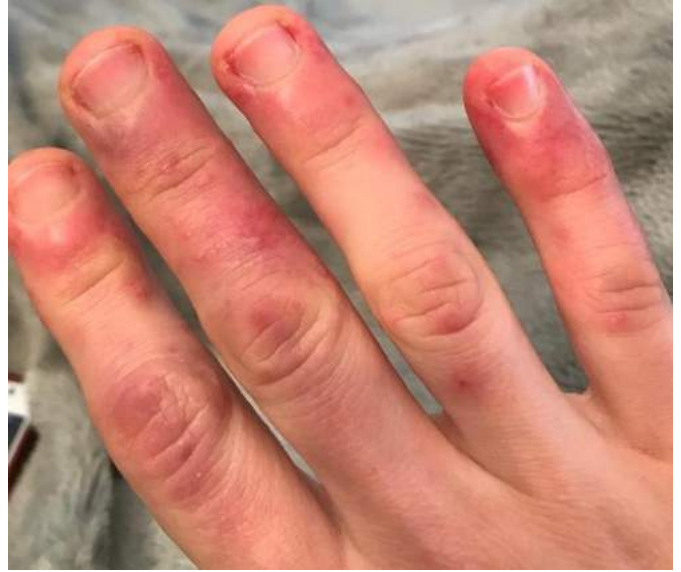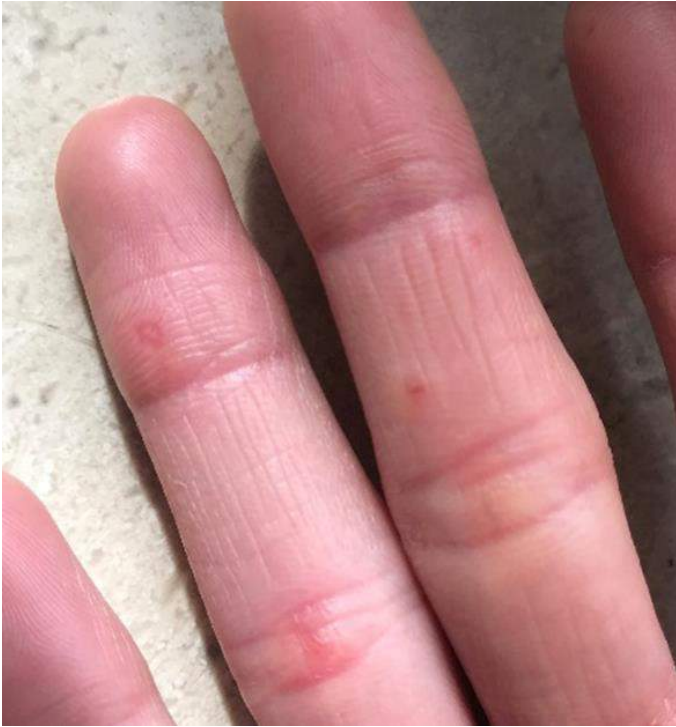Pseudo-chilblain – Confirmed cases



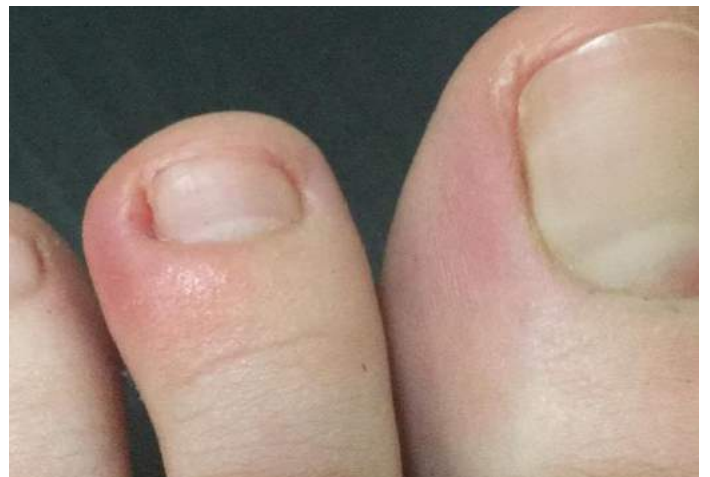
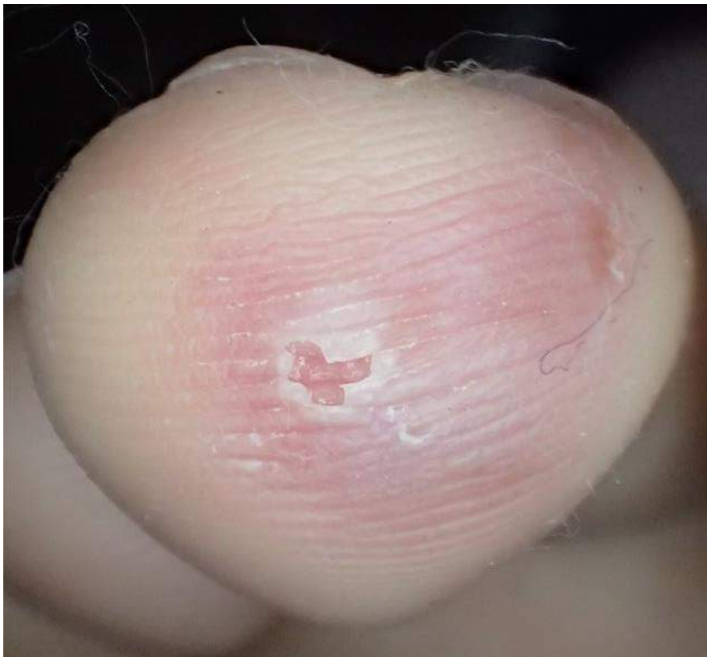
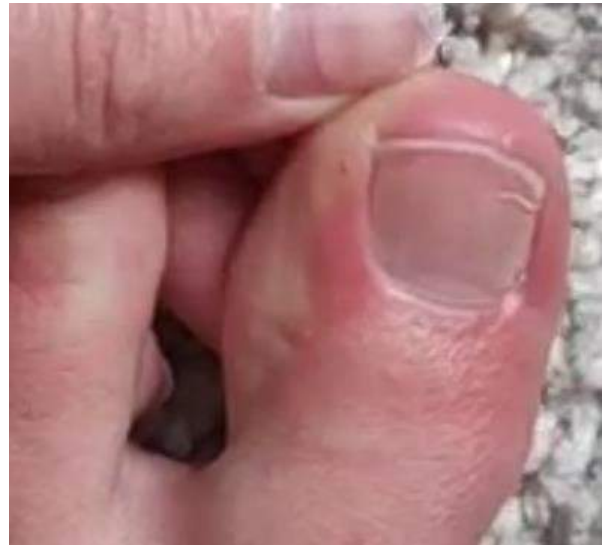
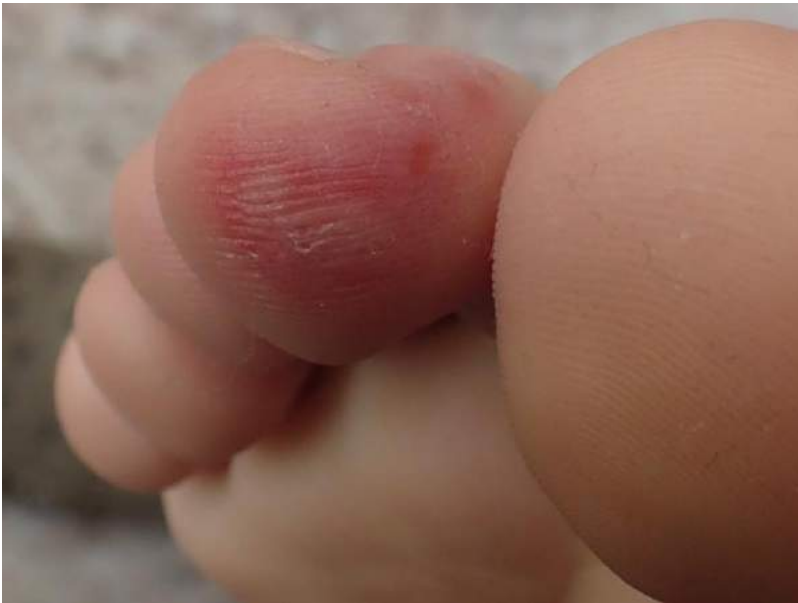


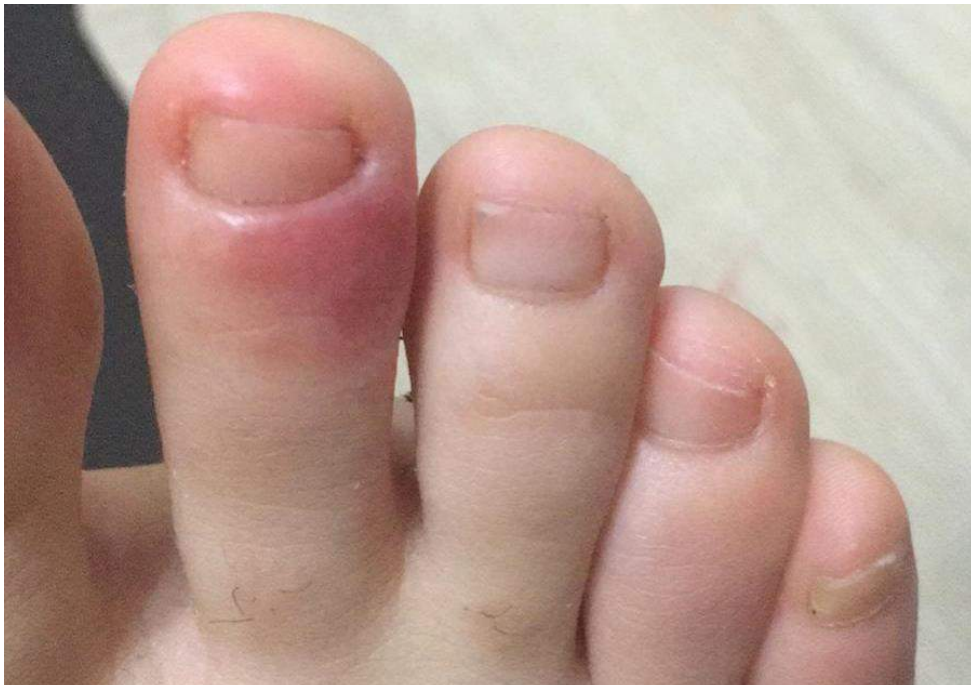
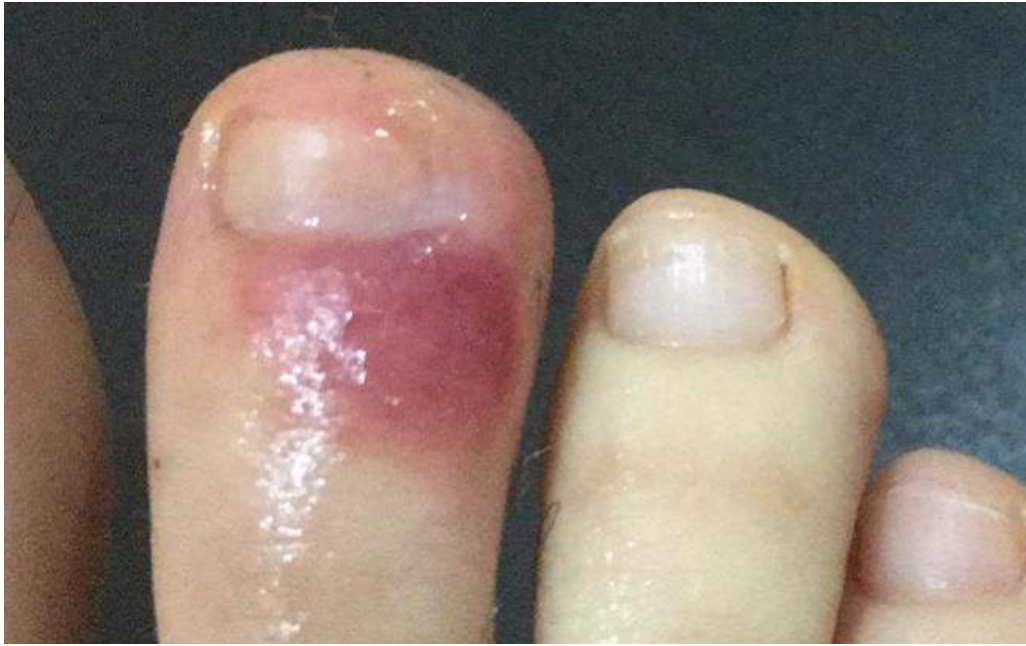
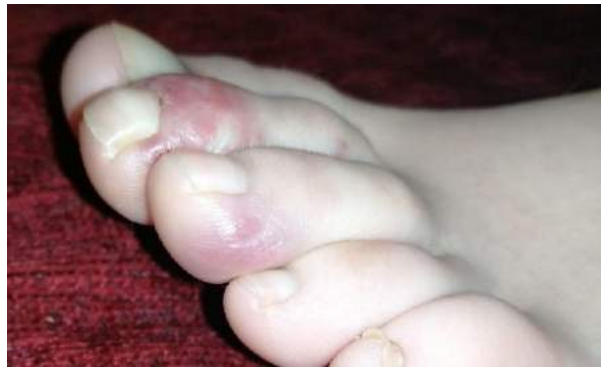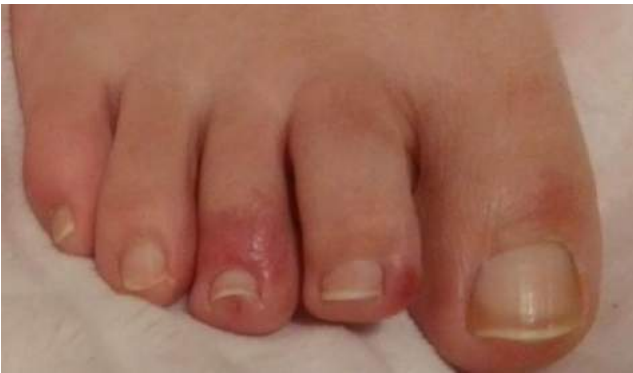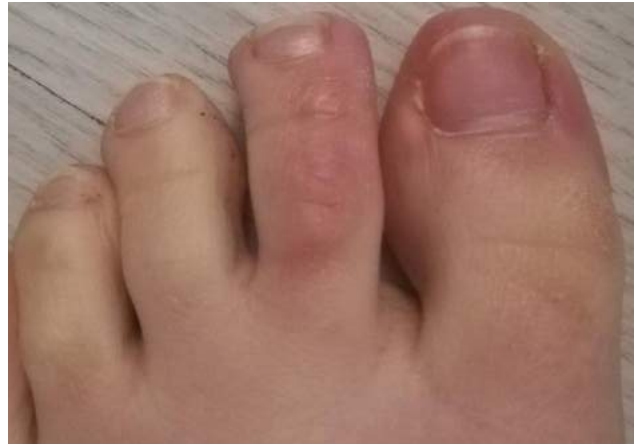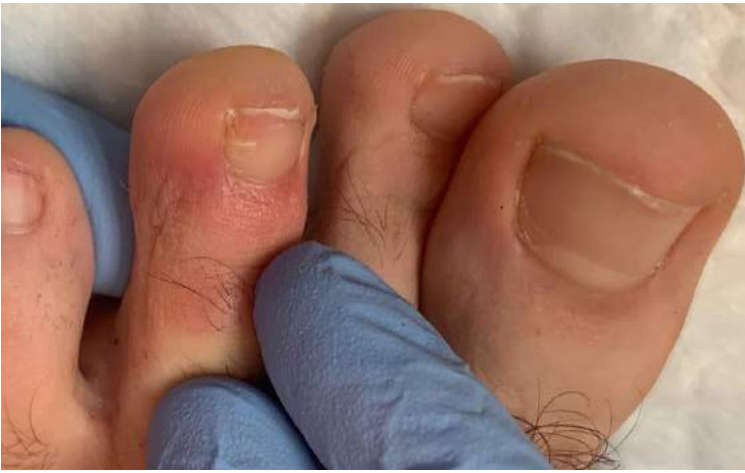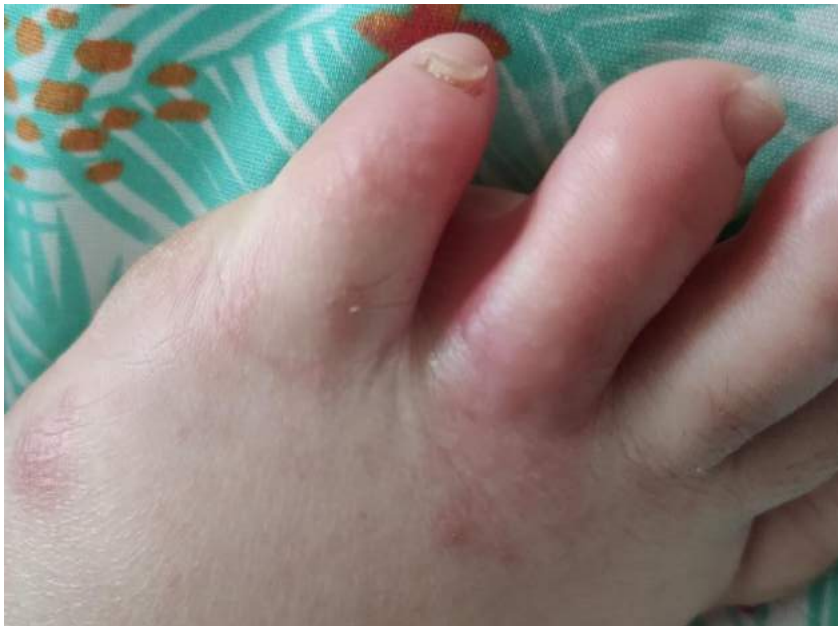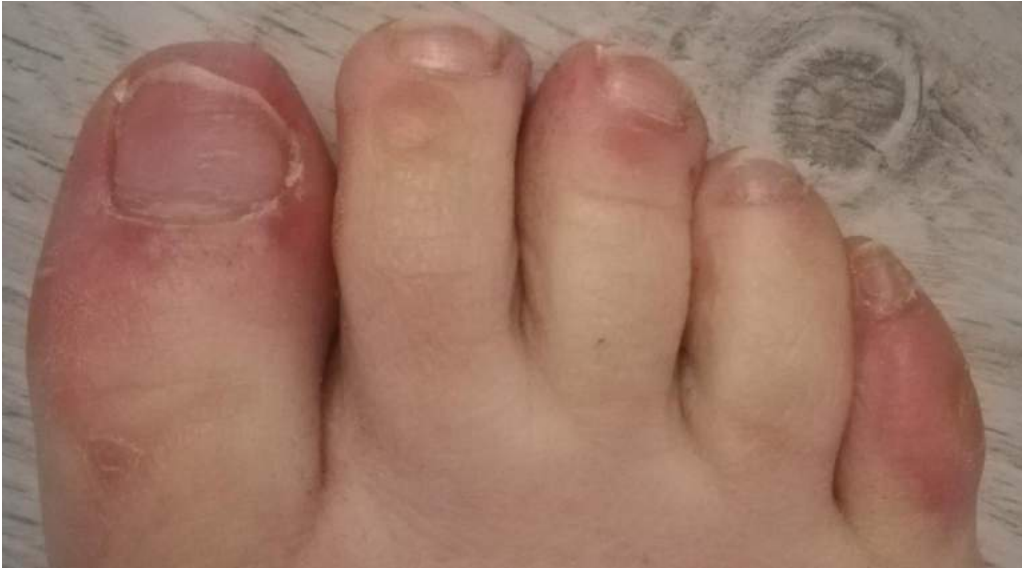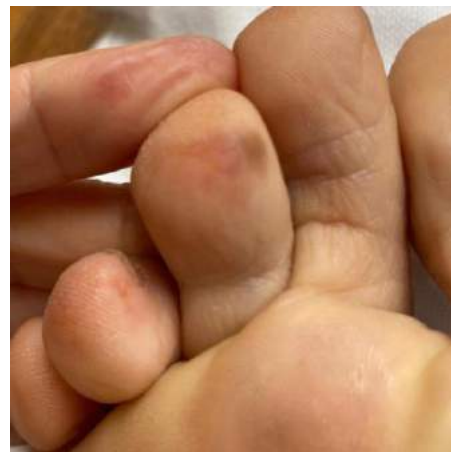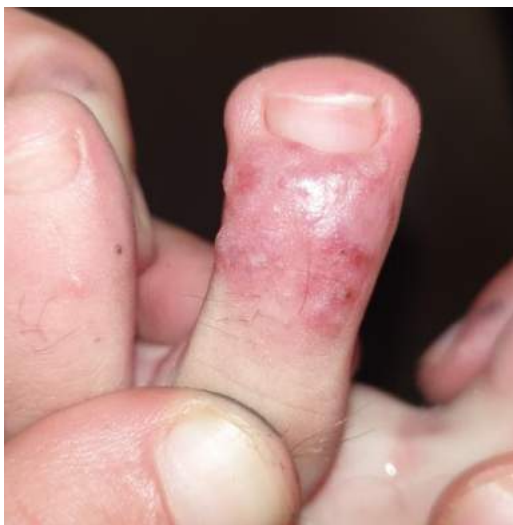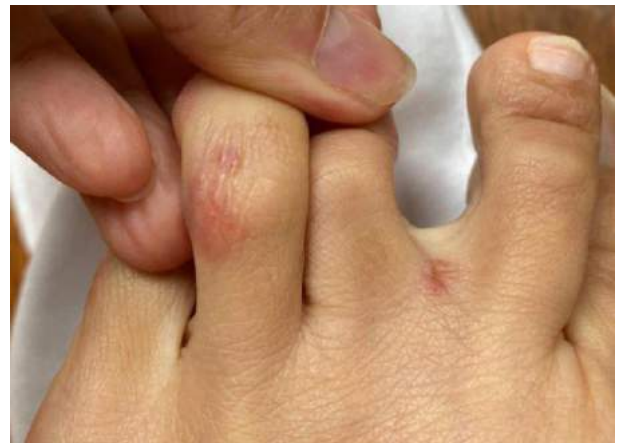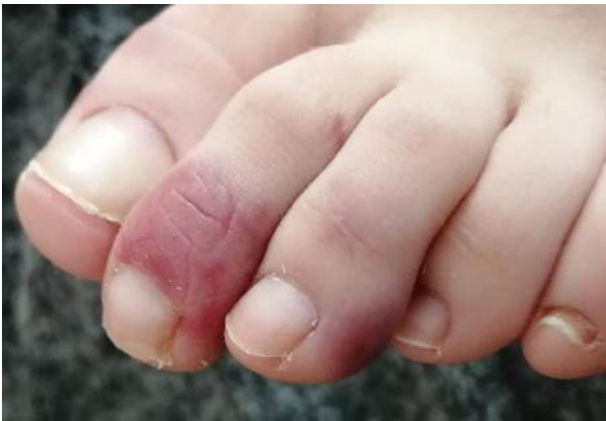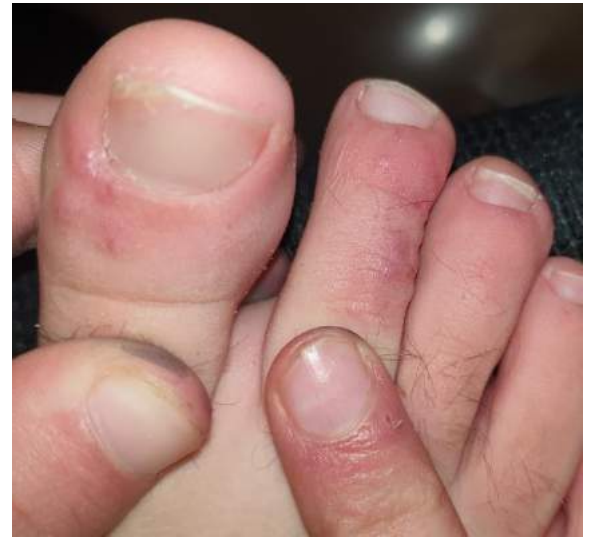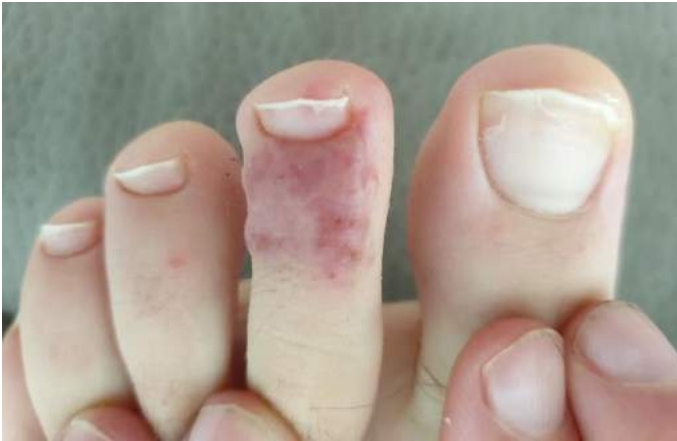Pseudo-chilblain – Suspected cases

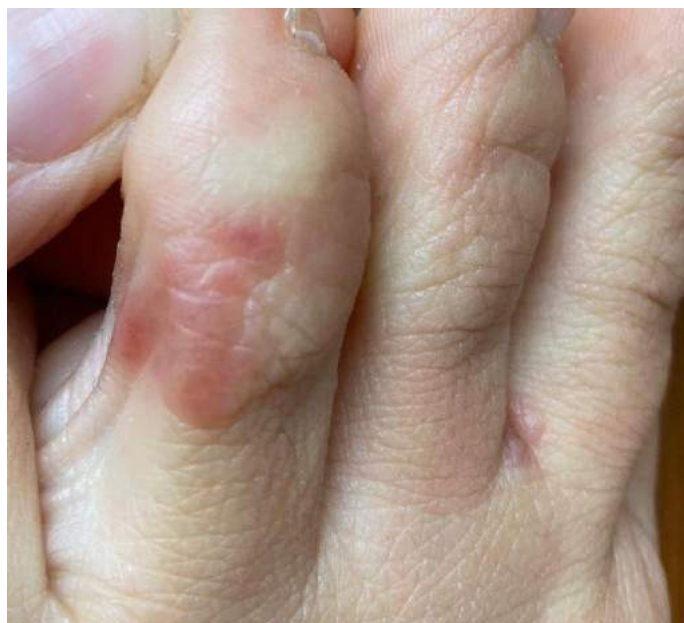
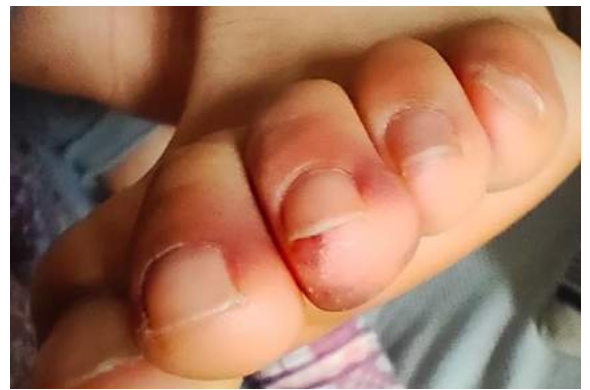
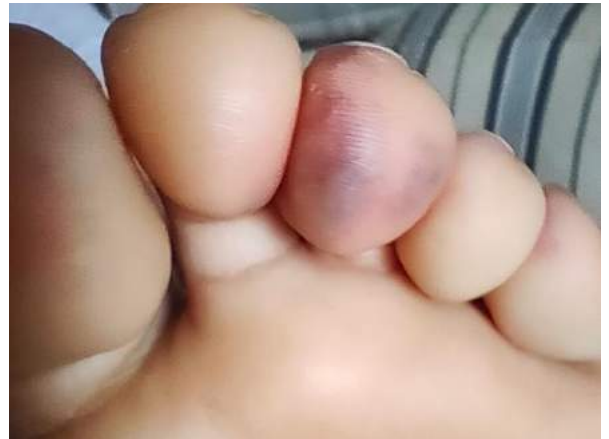
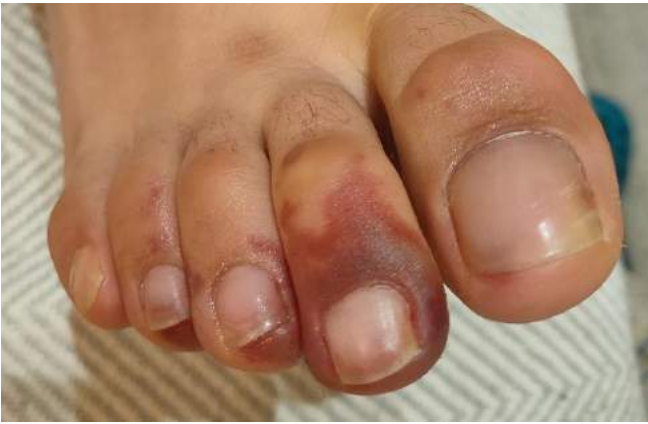


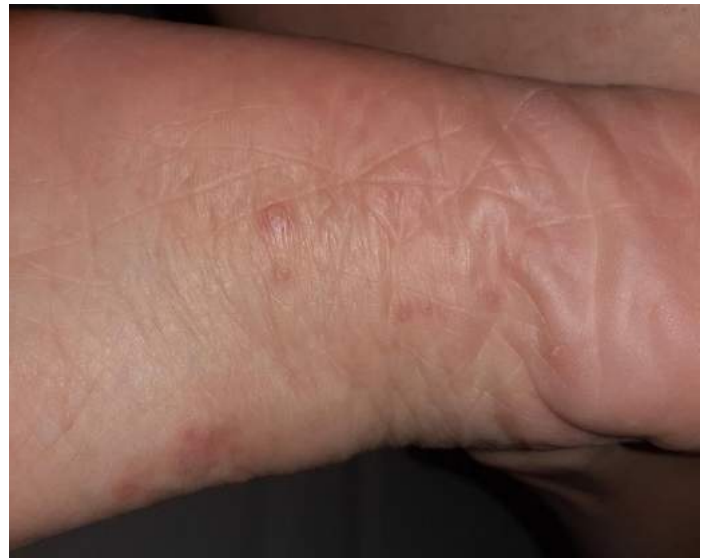
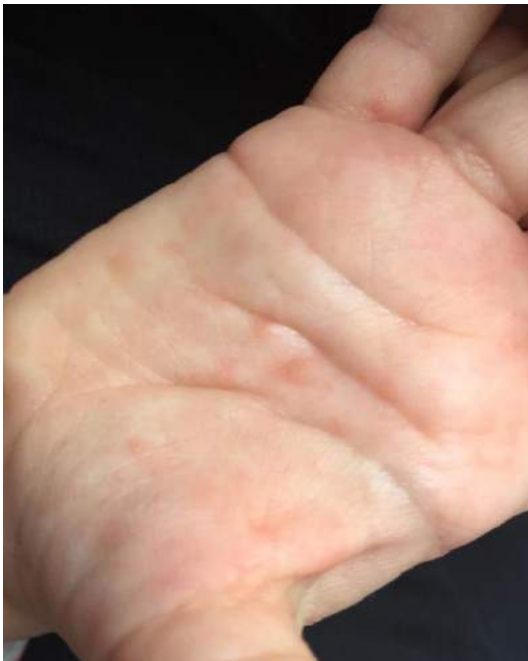
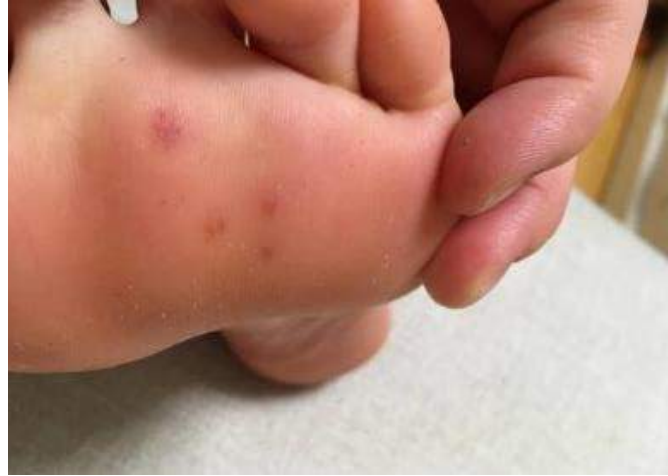
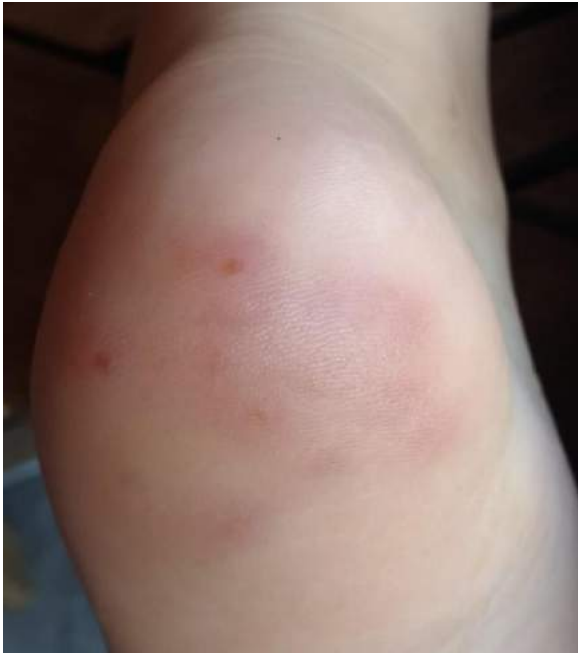


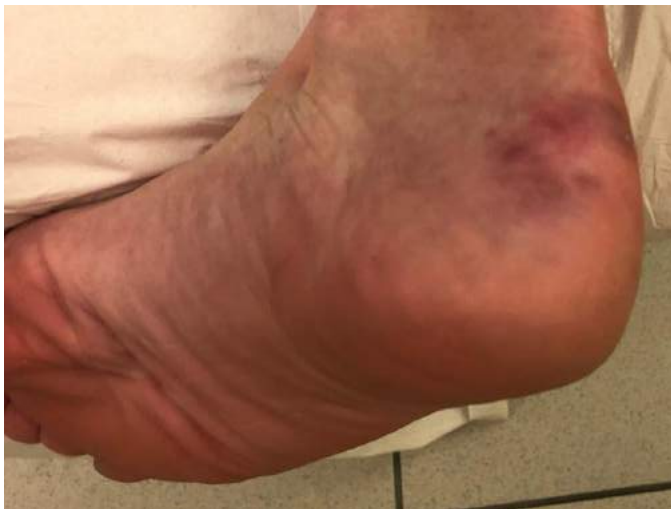
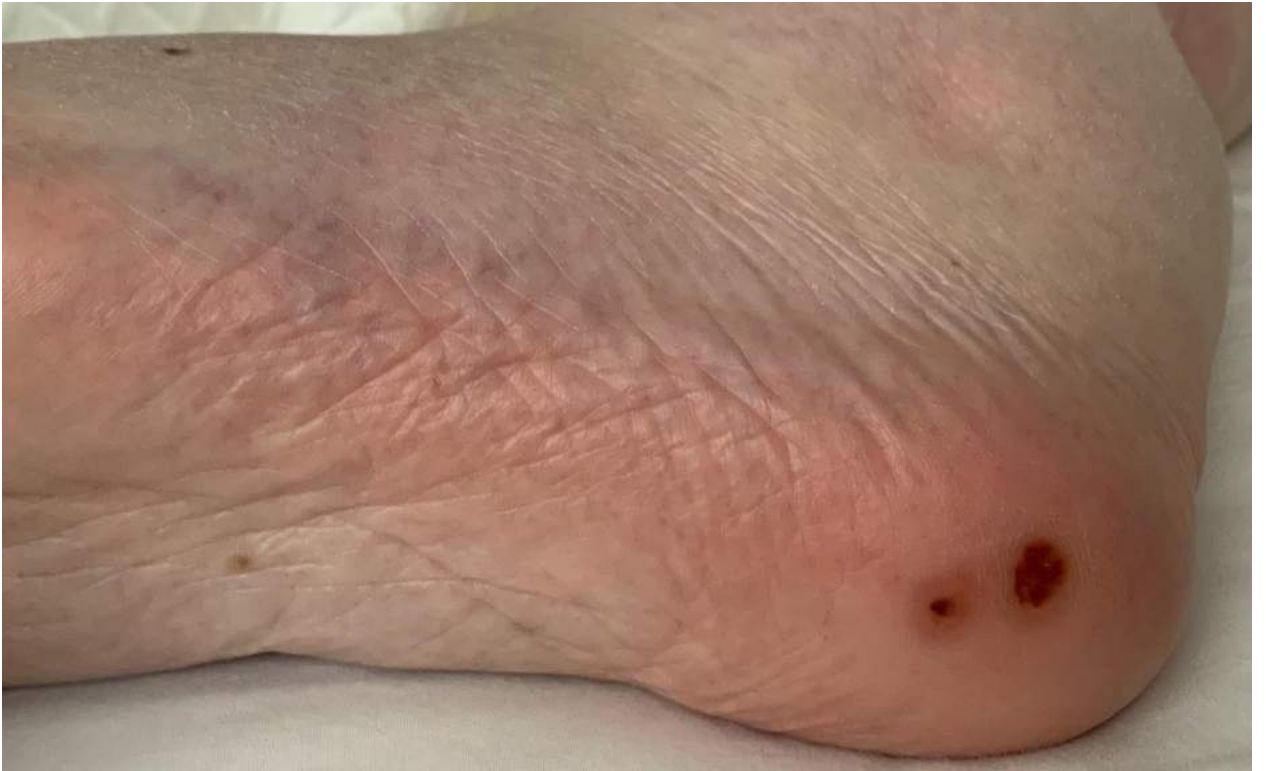


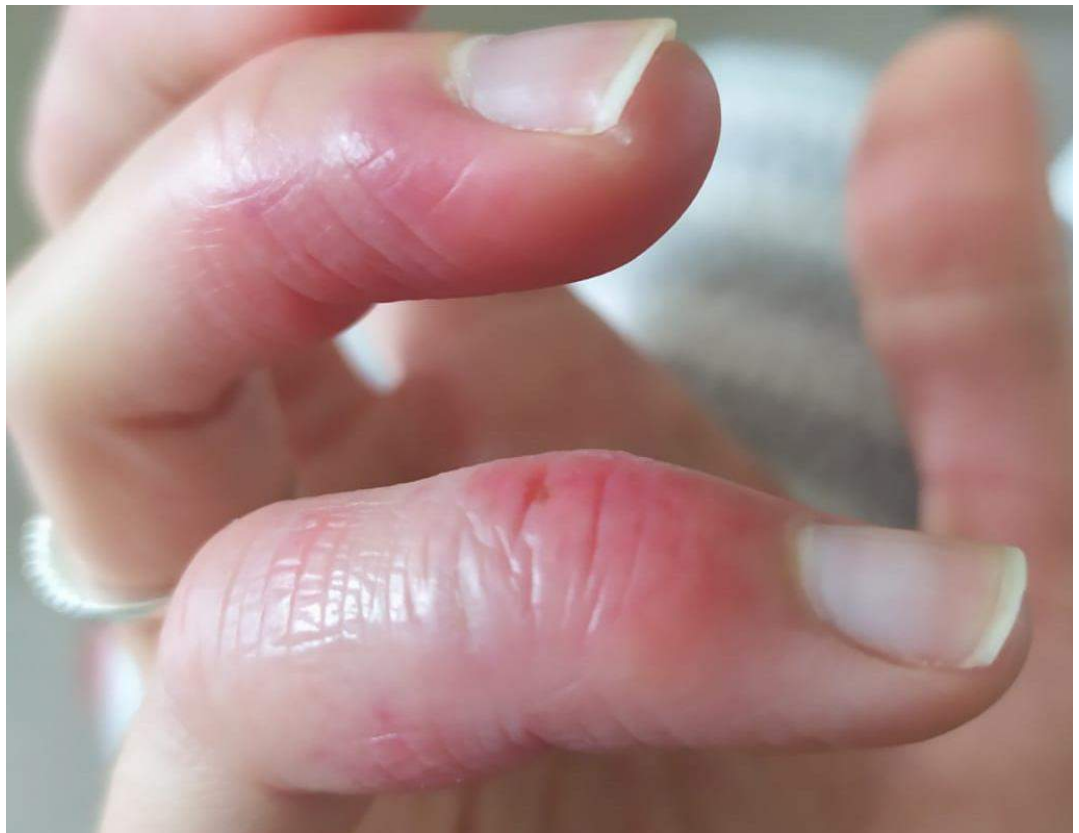
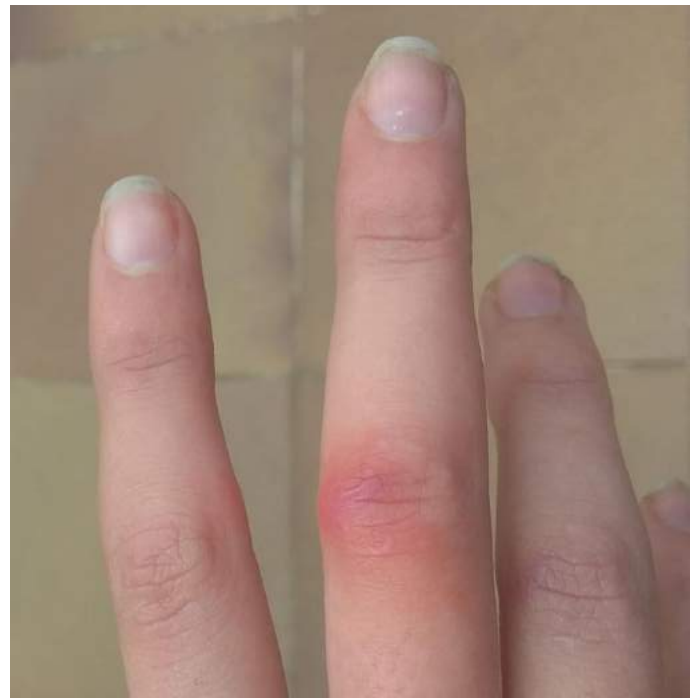
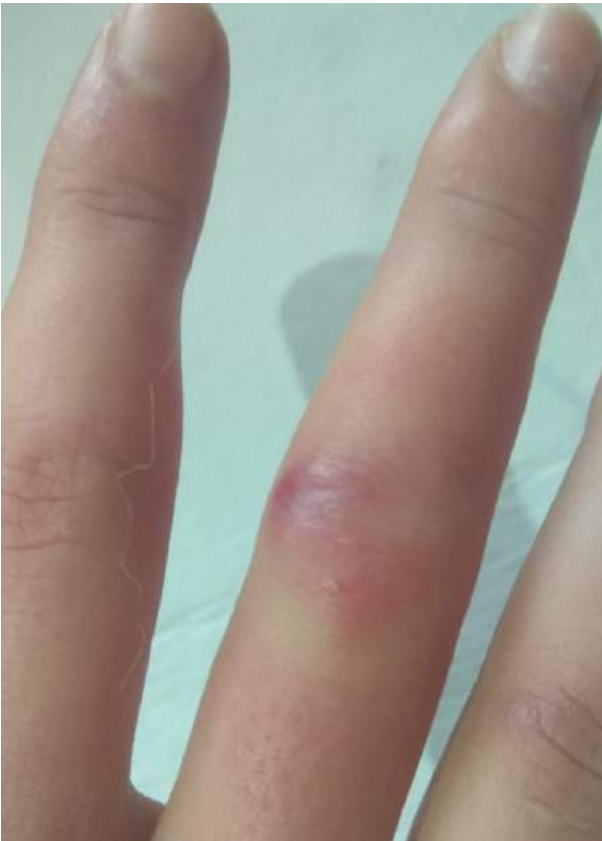

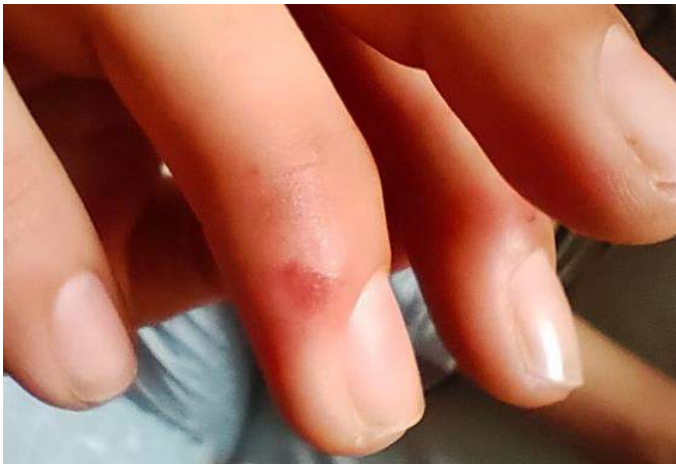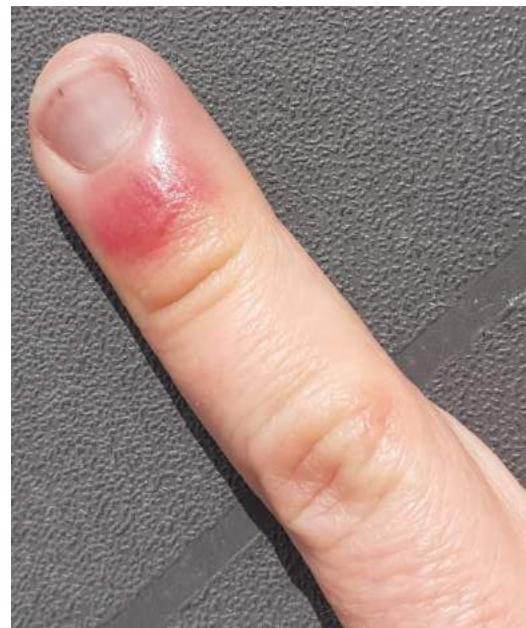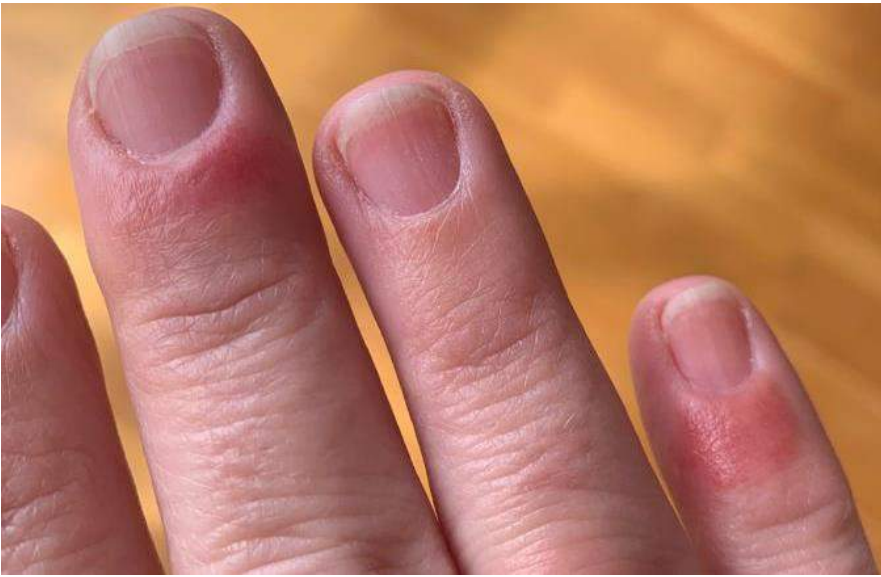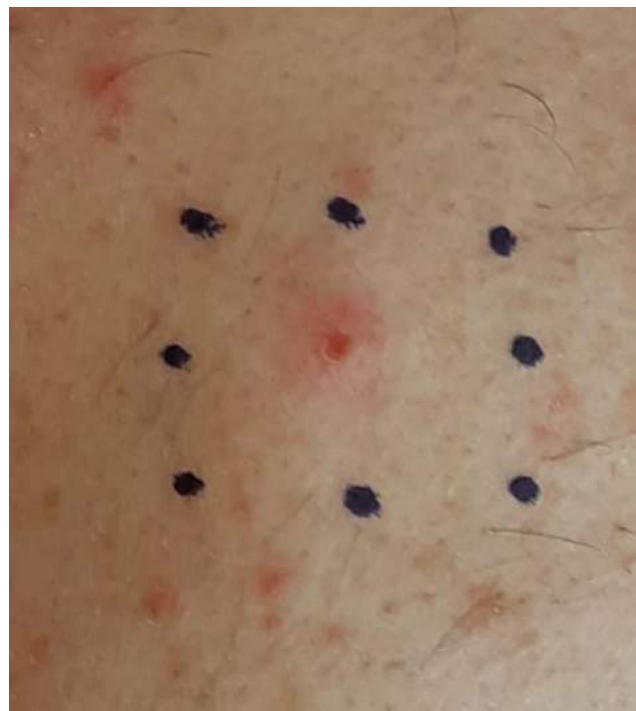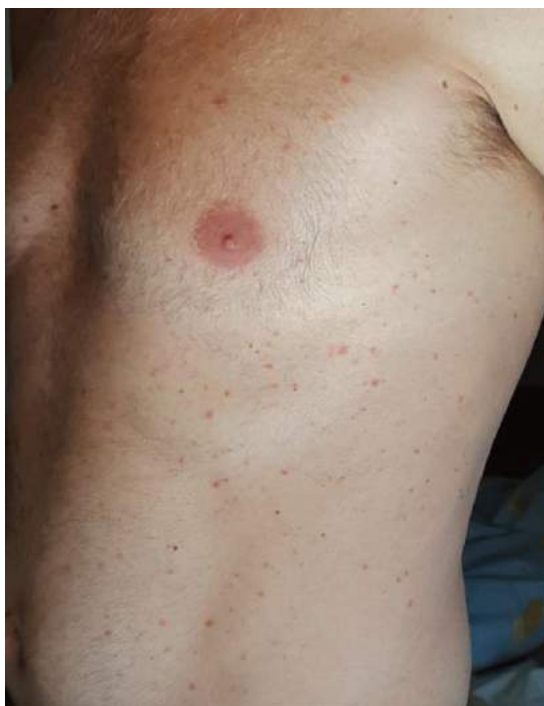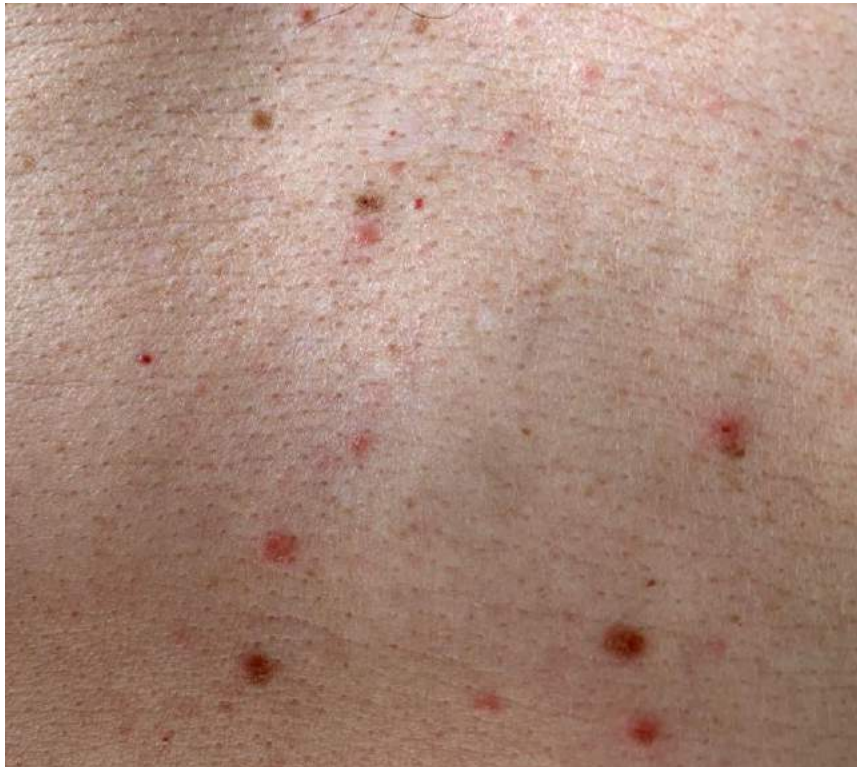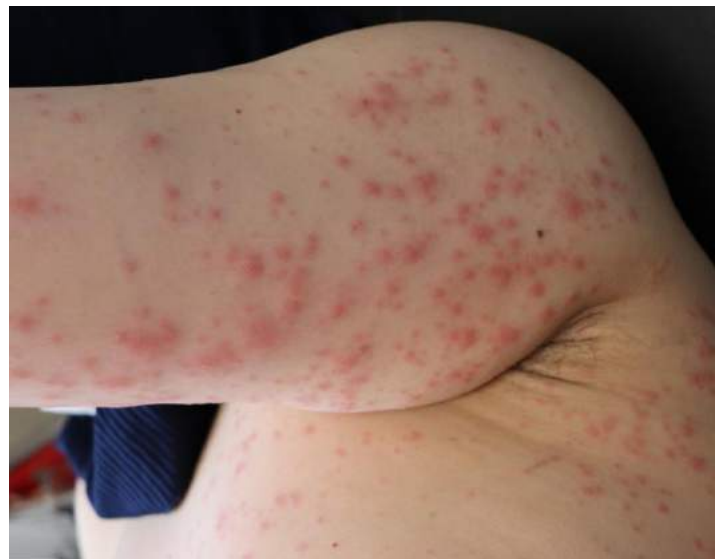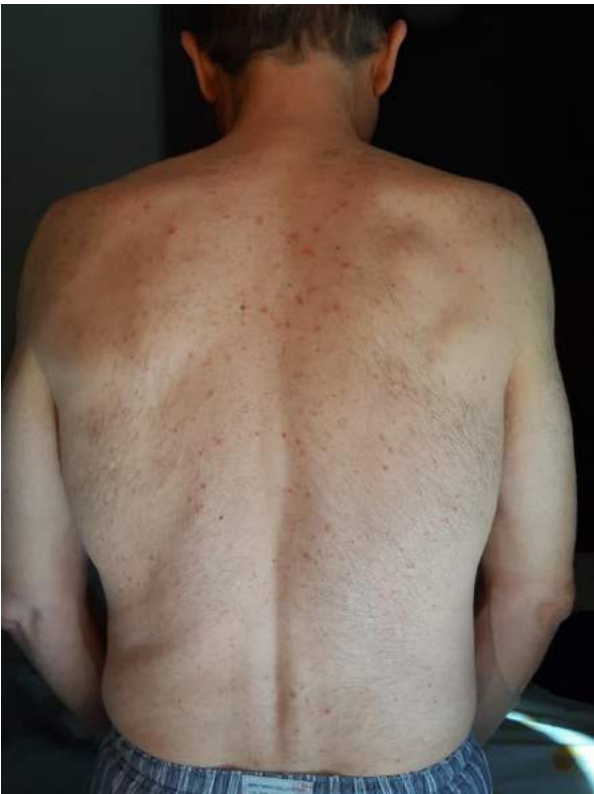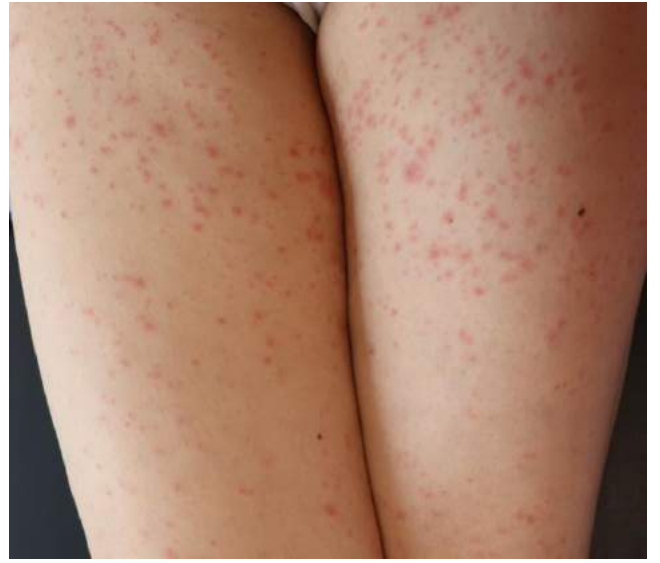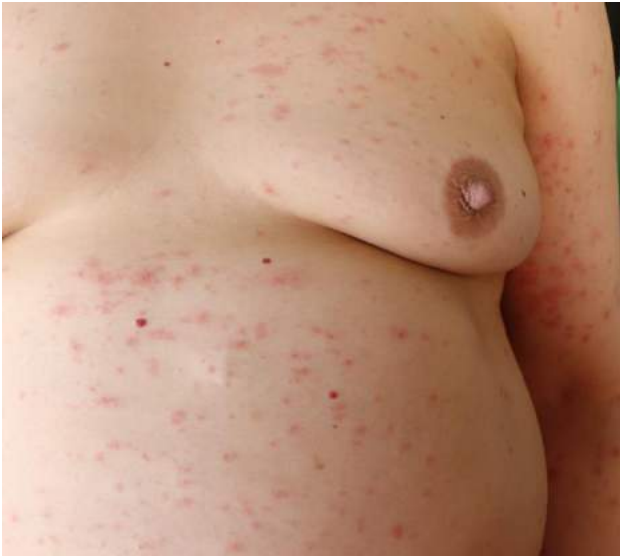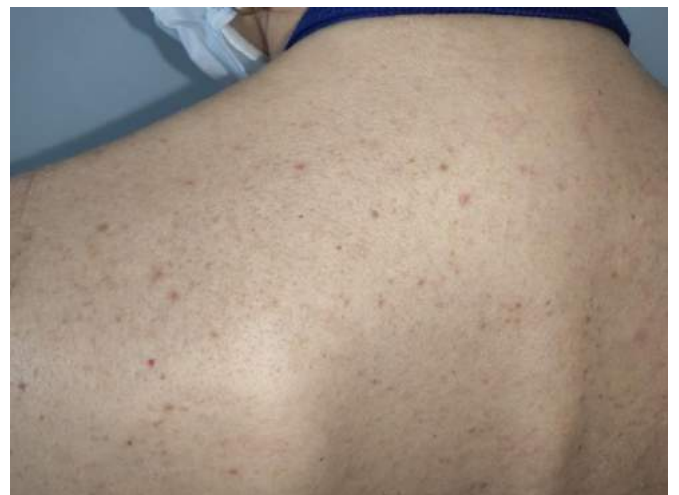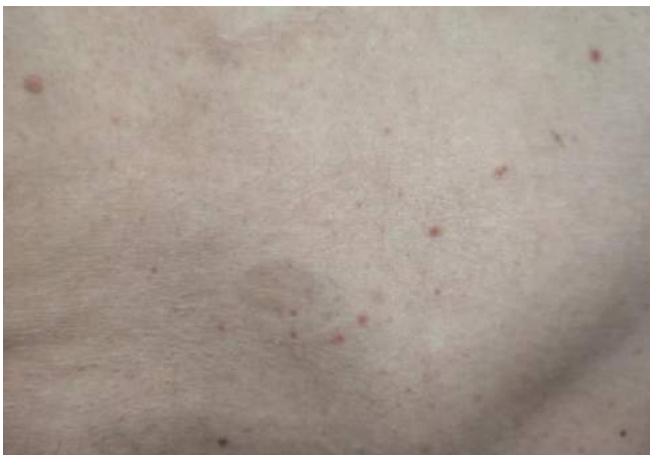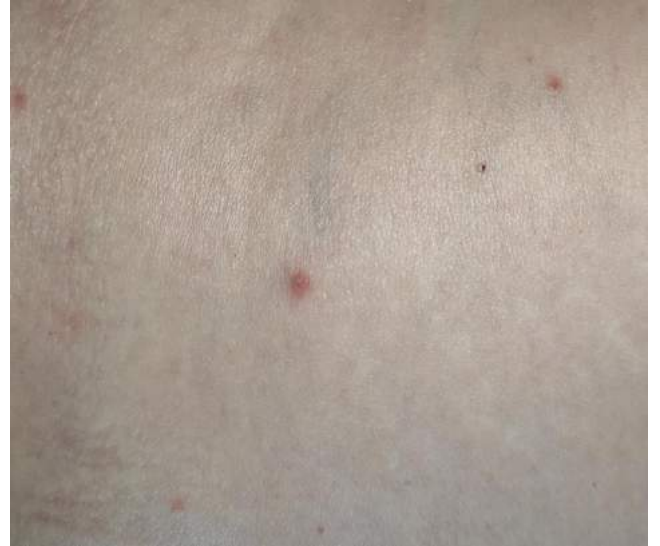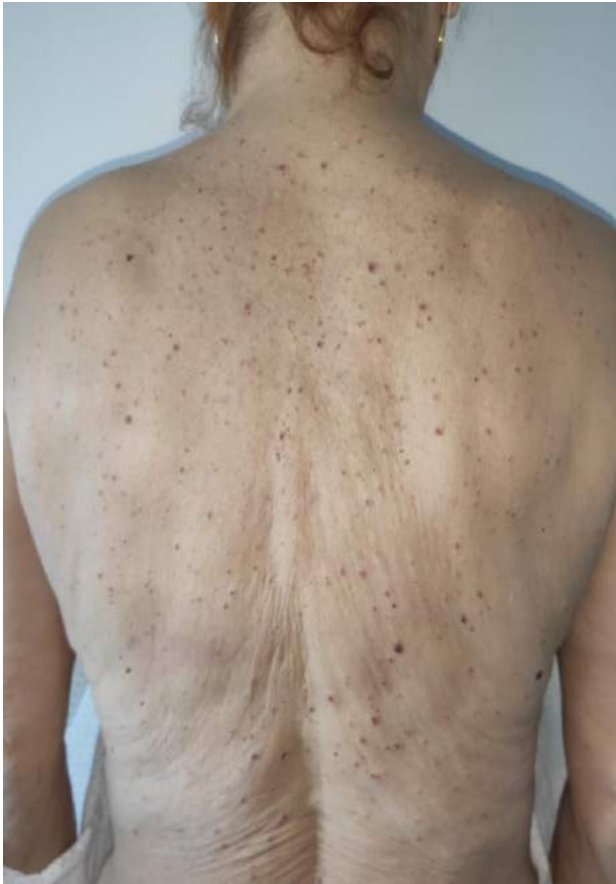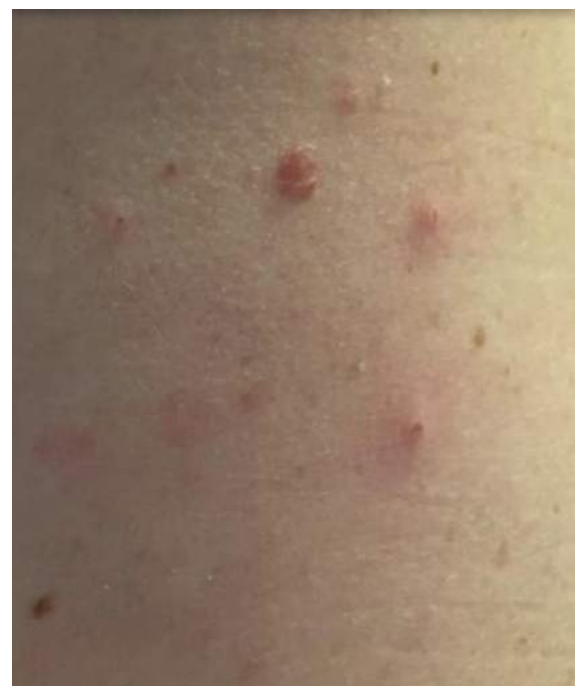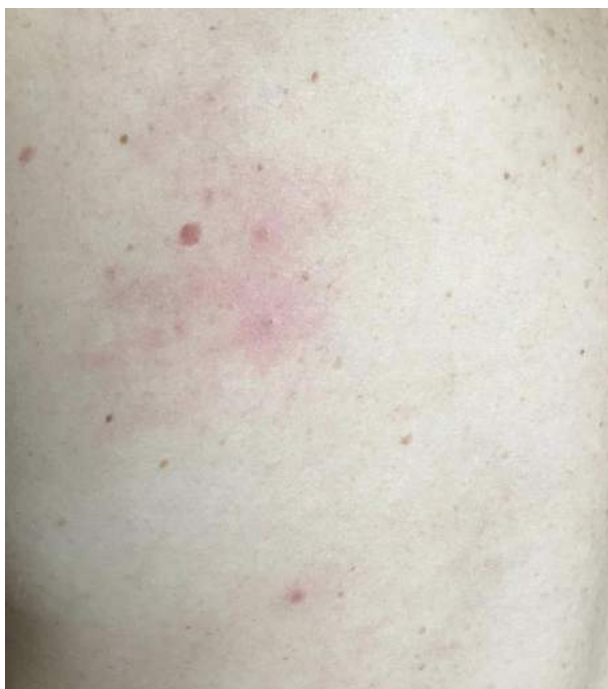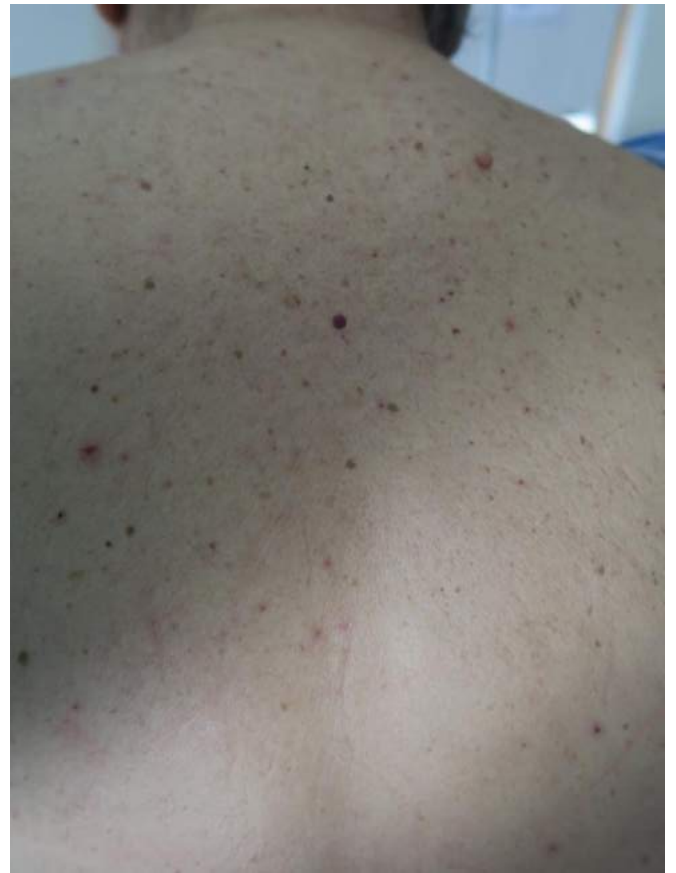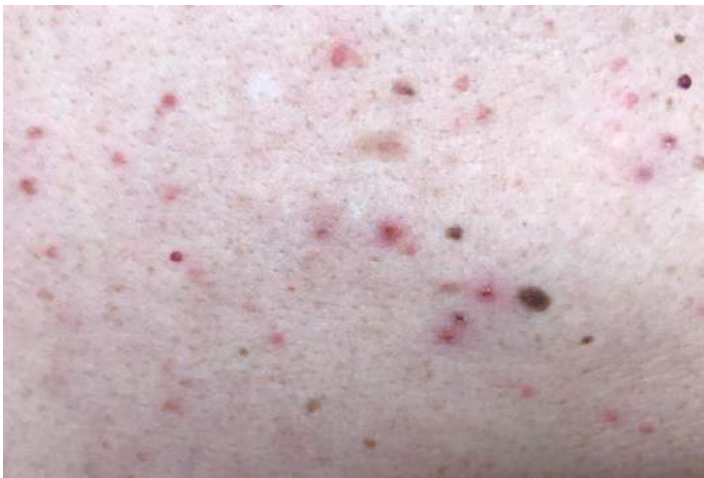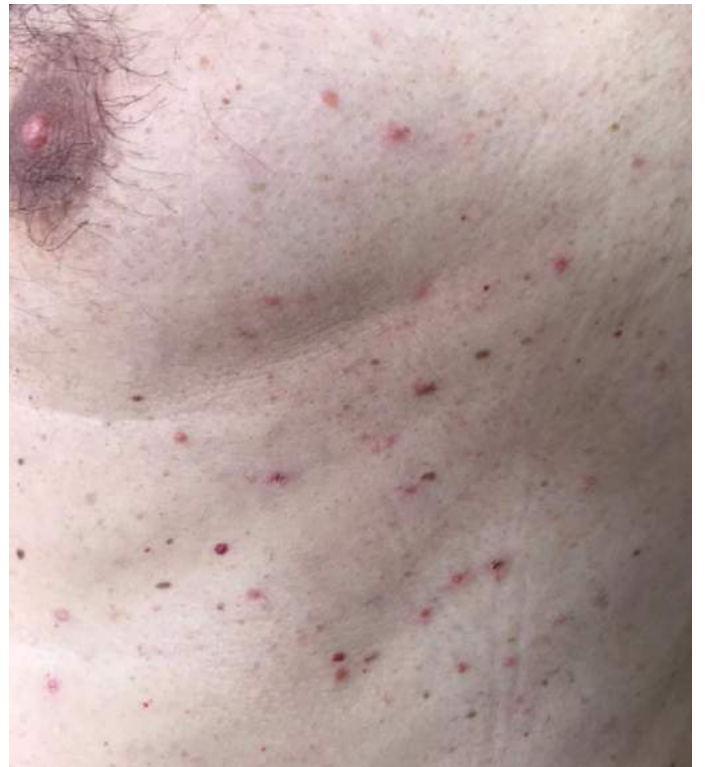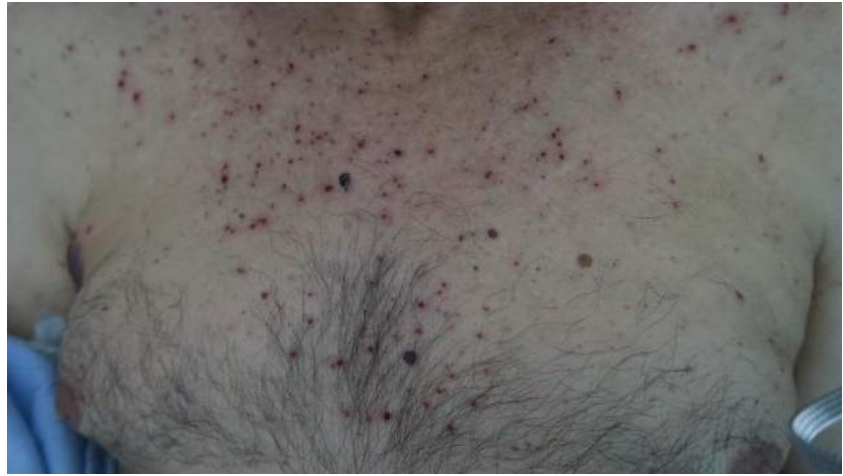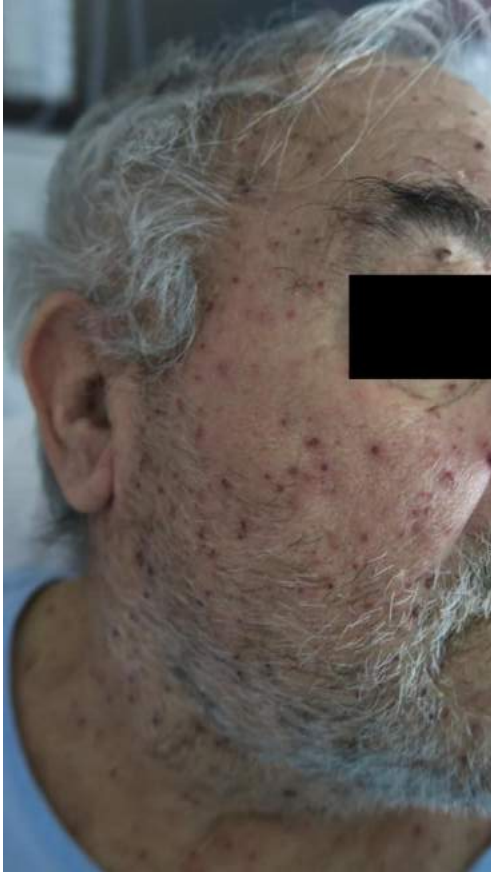Vesicular Eruption – Confirmed cases

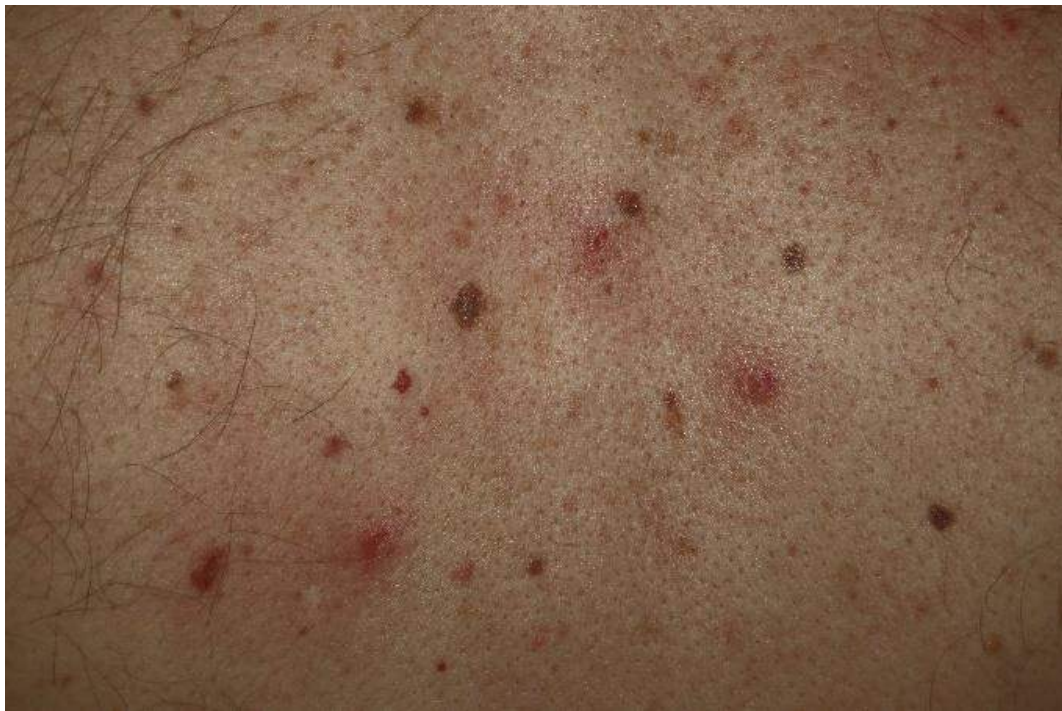
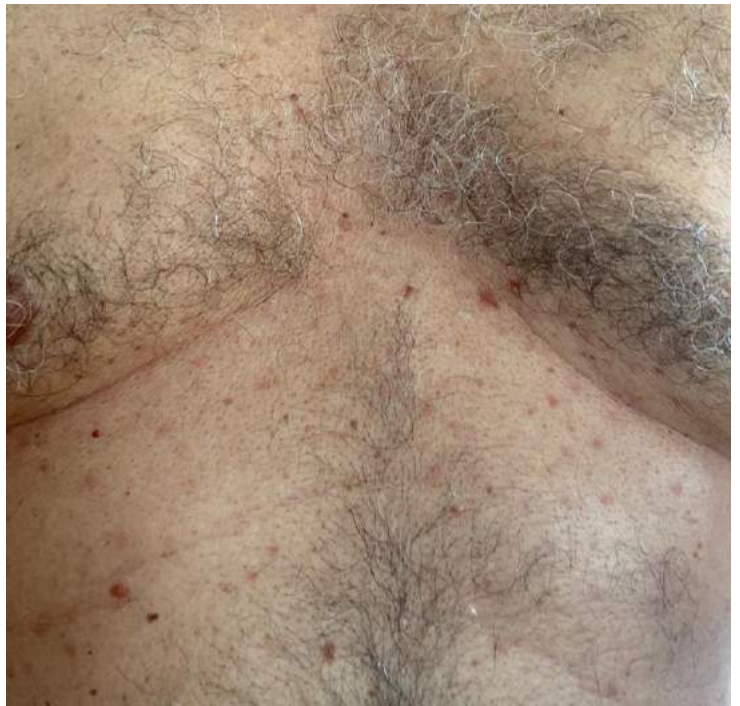
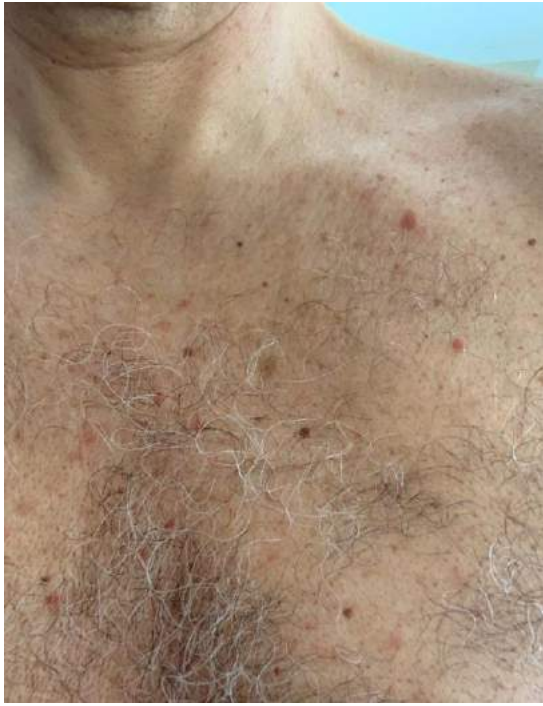


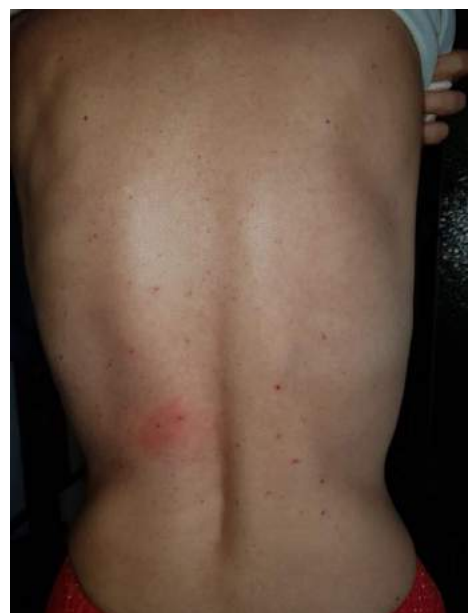
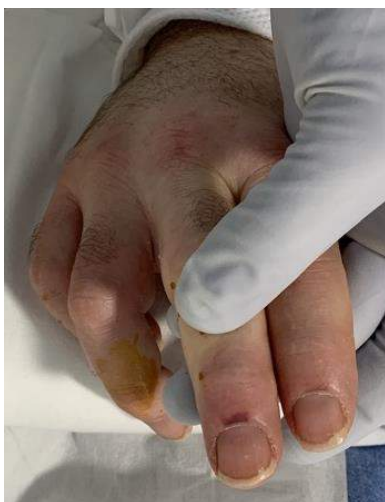
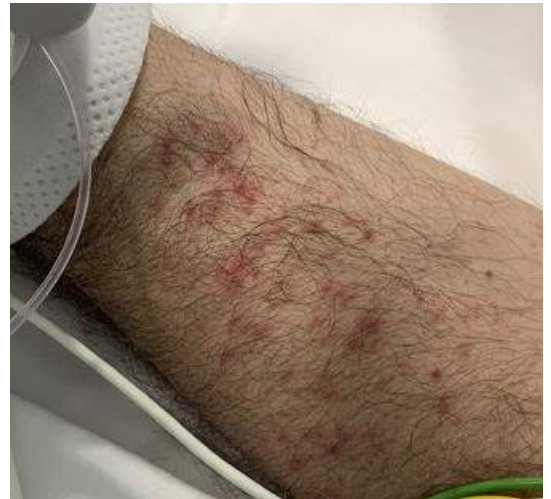
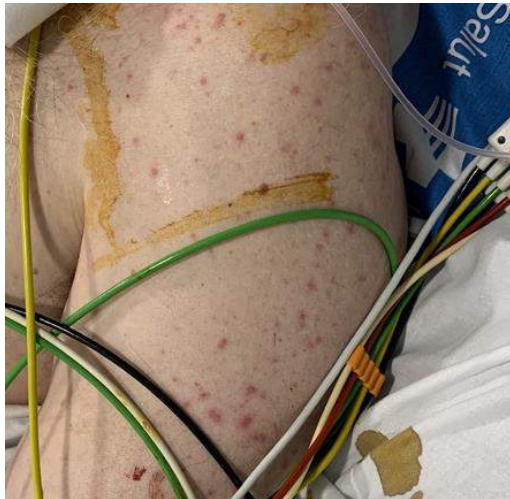
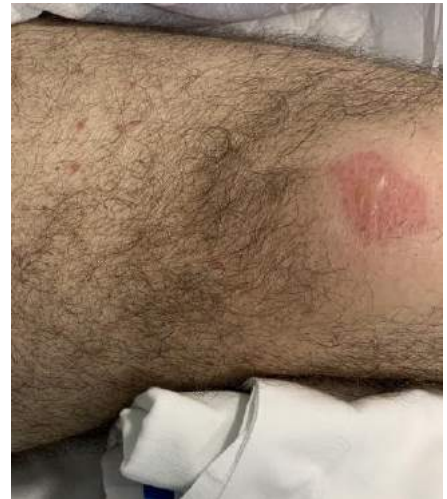
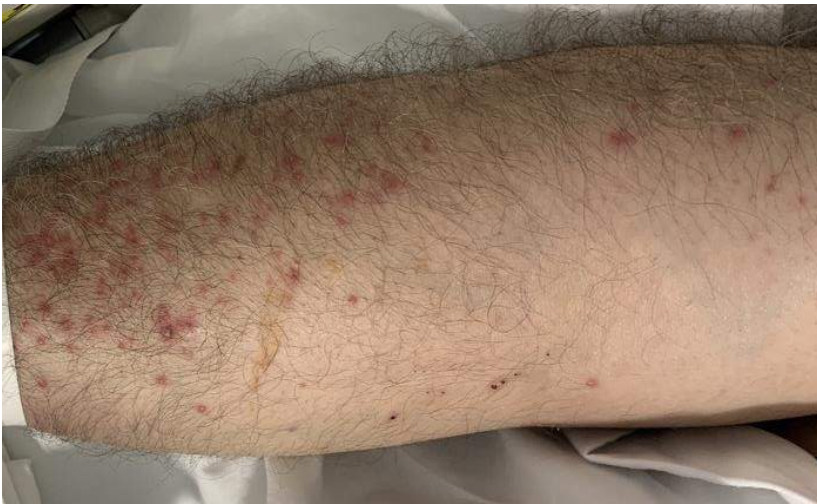

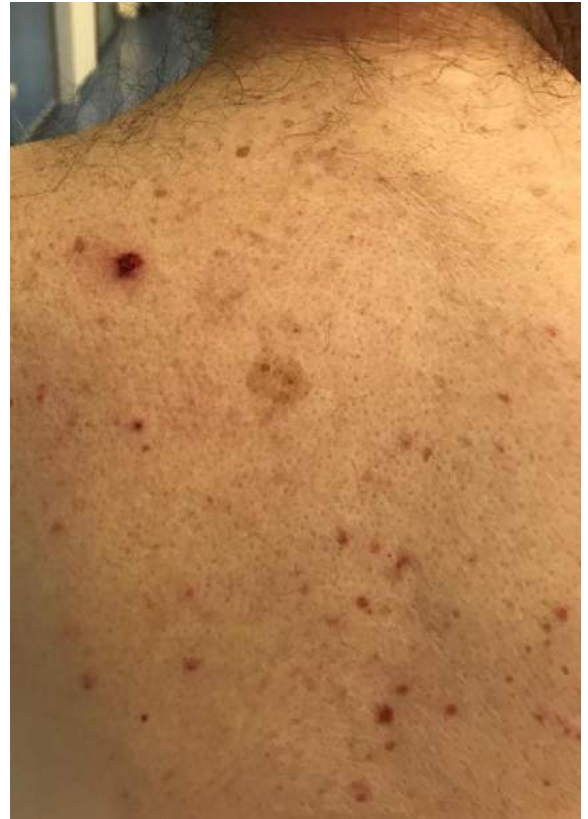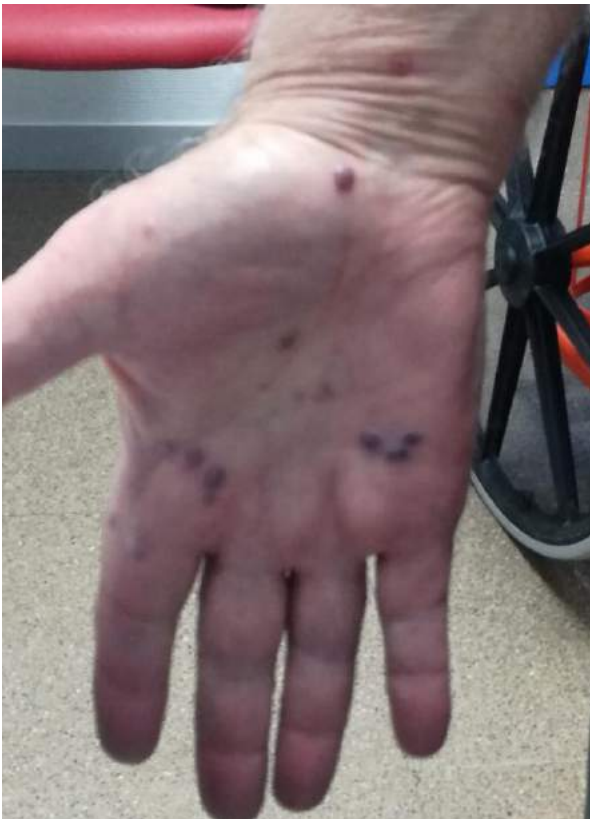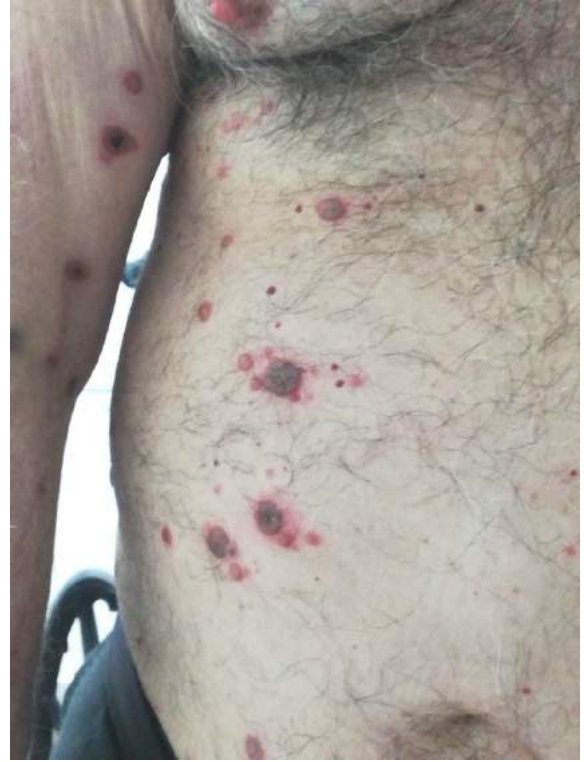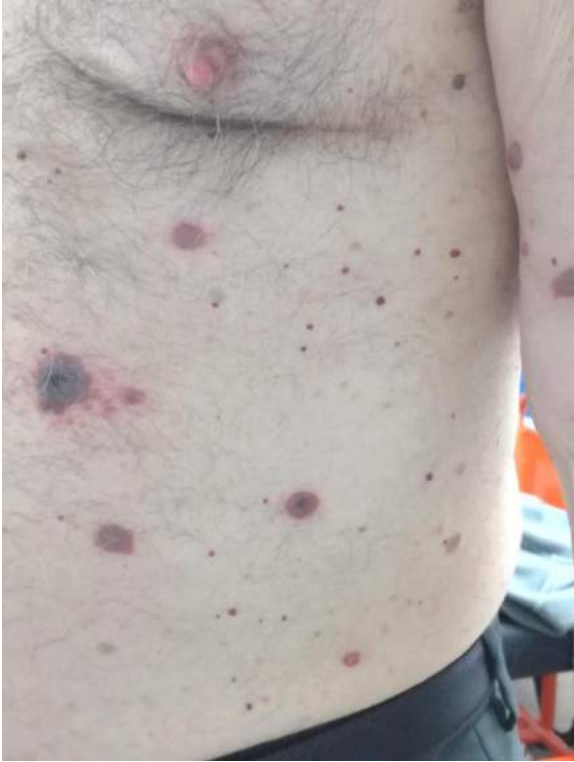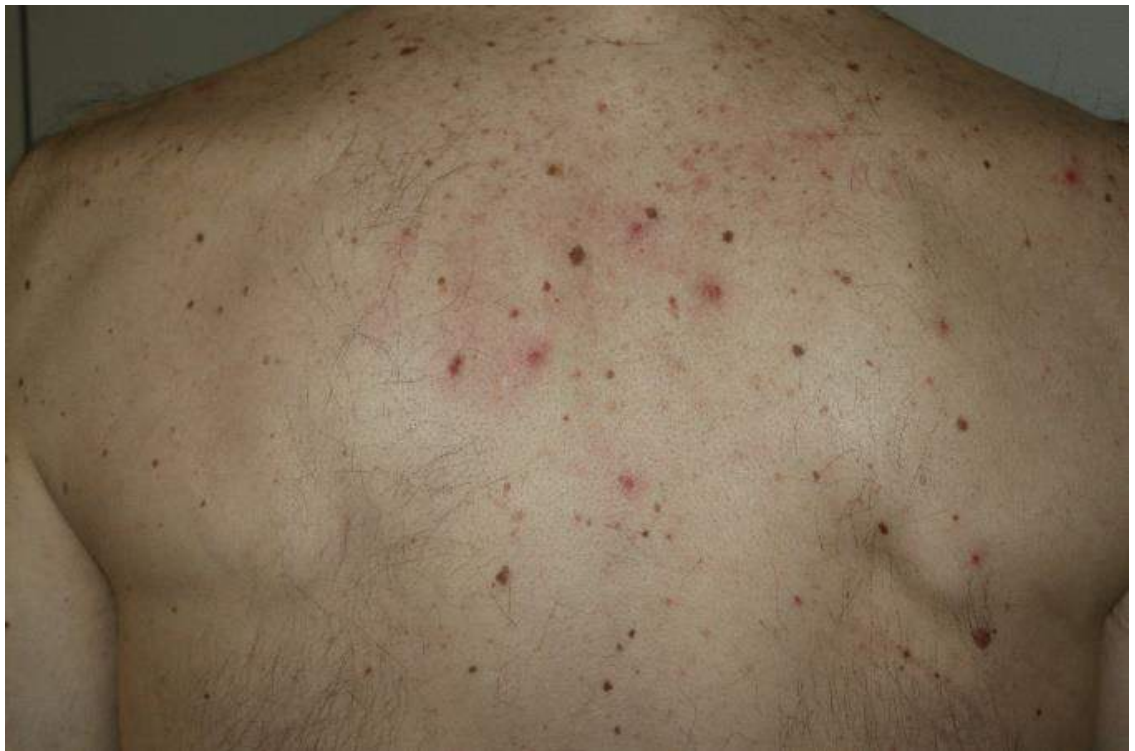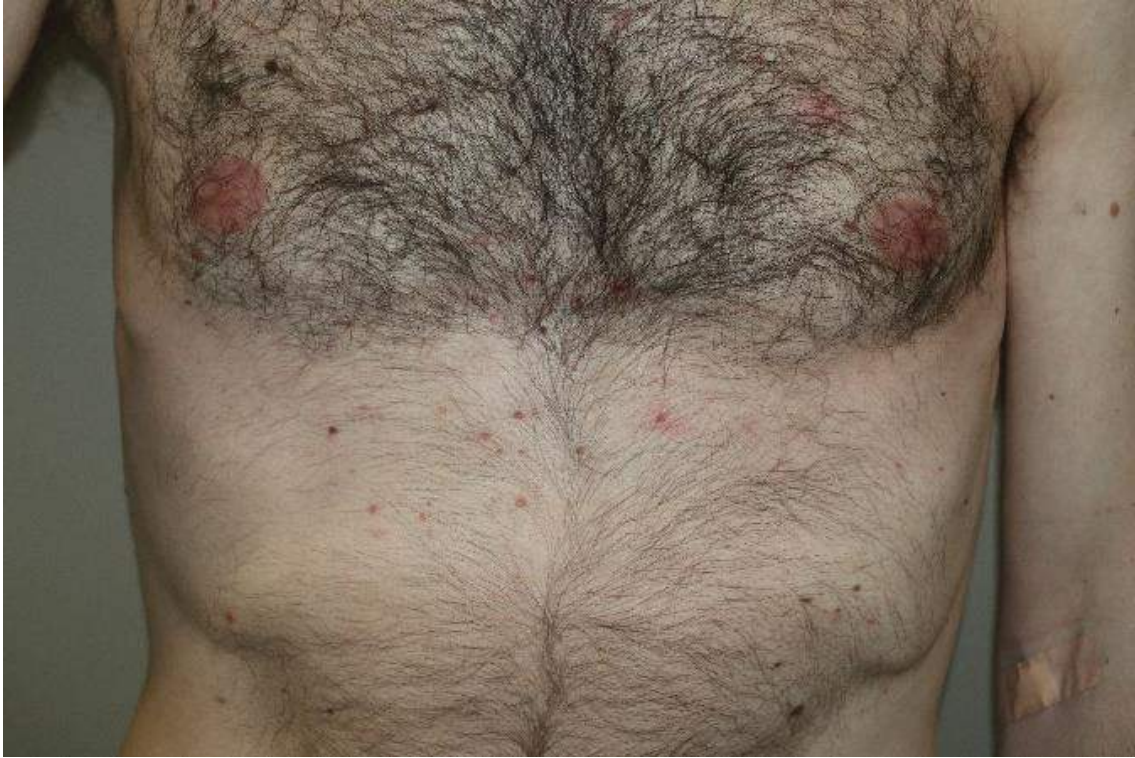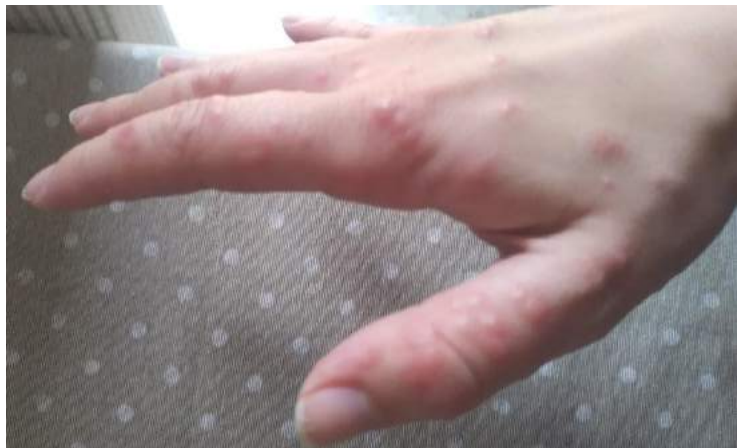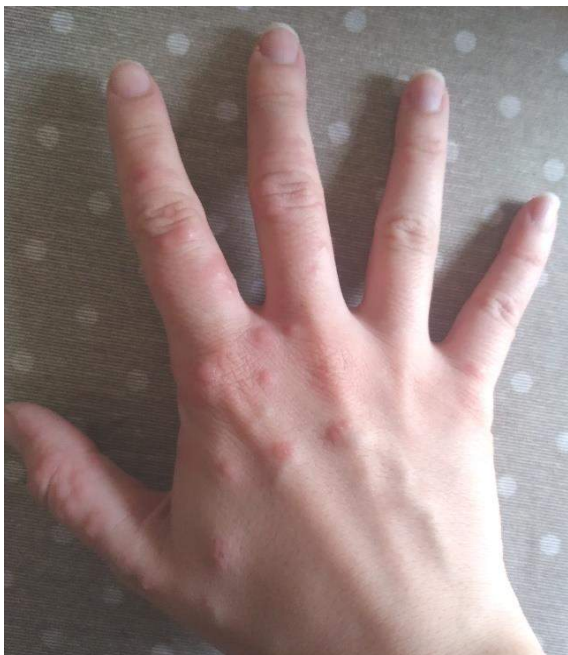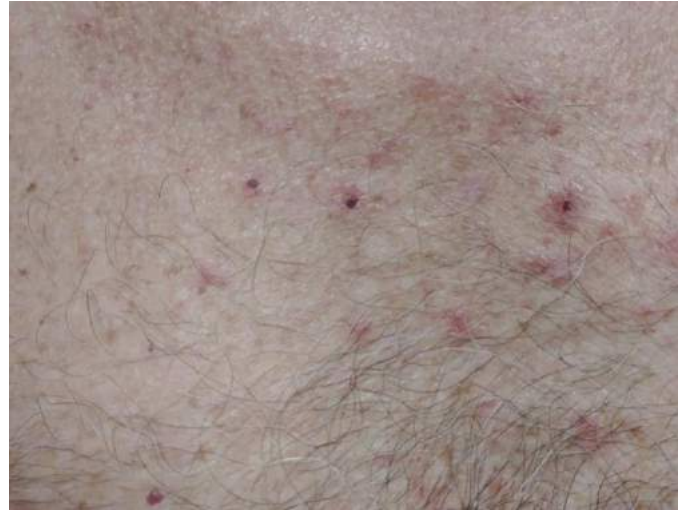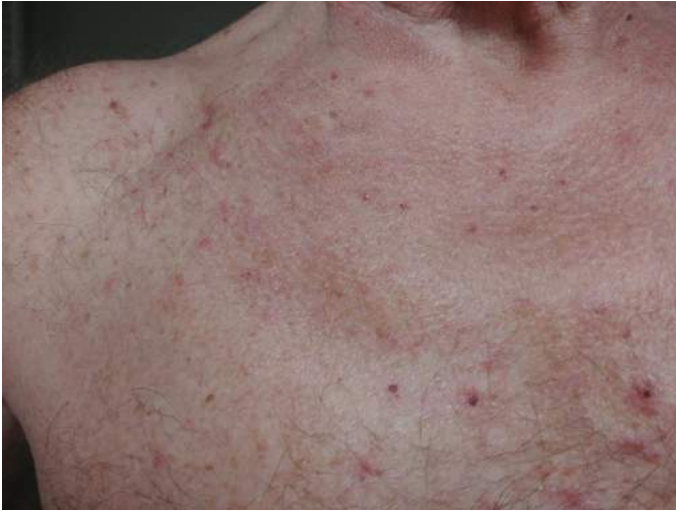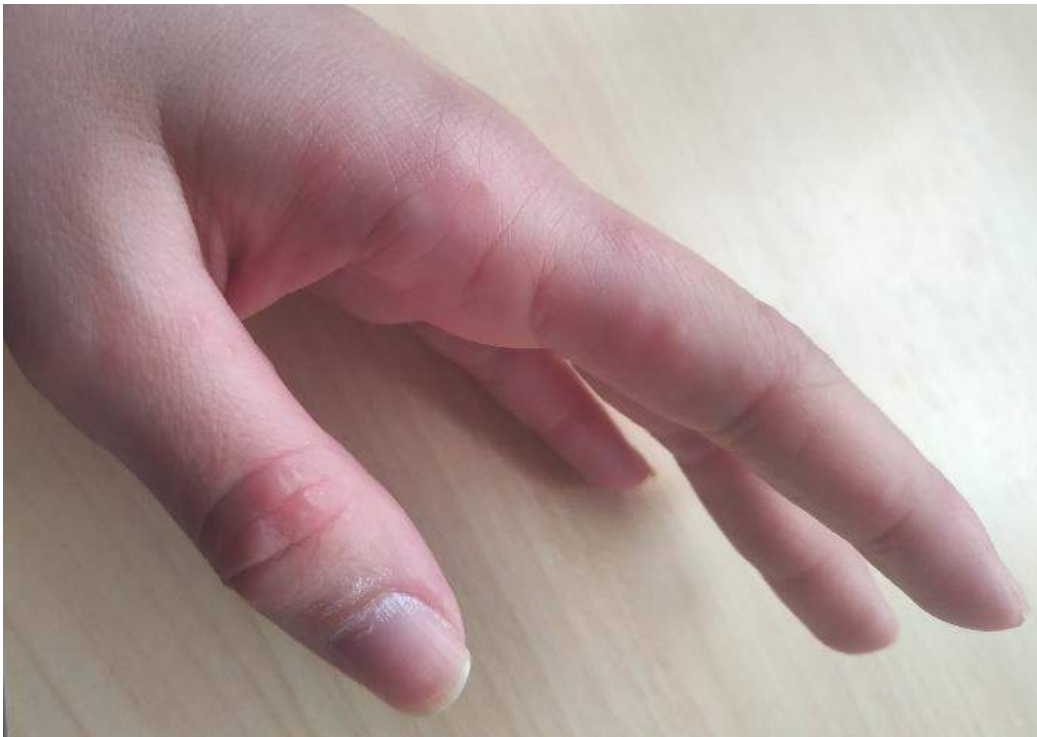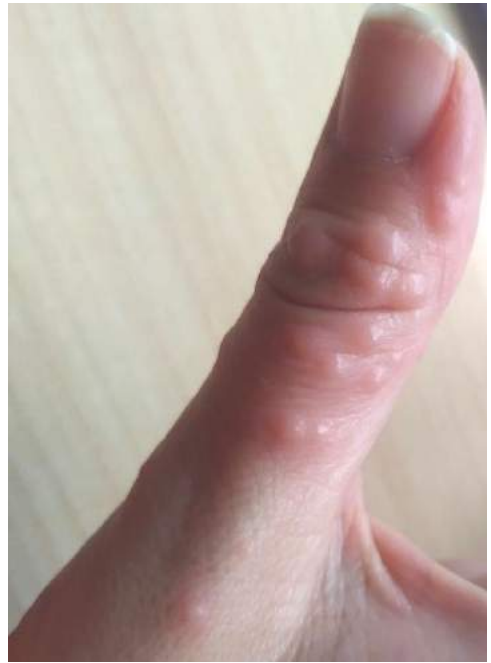






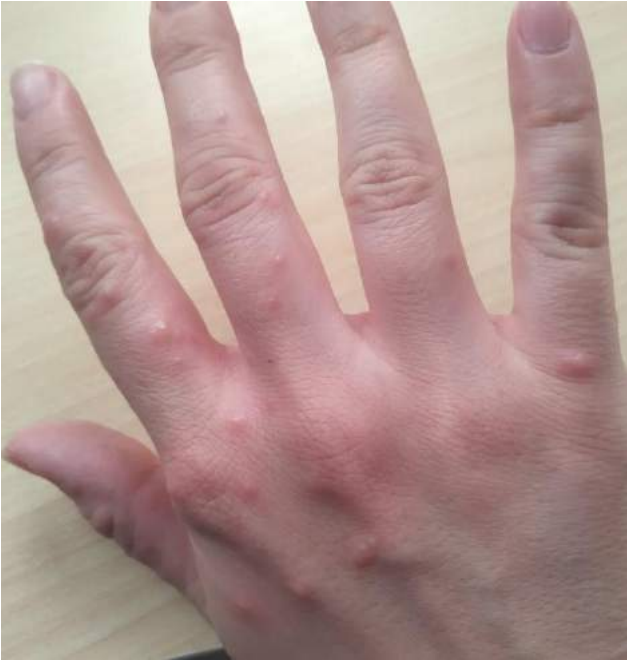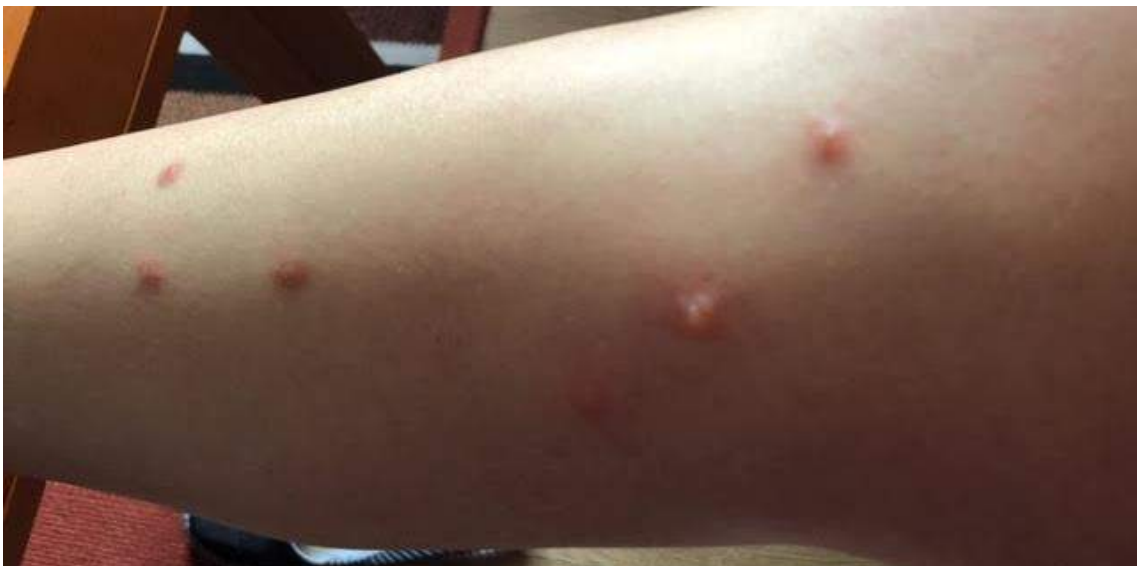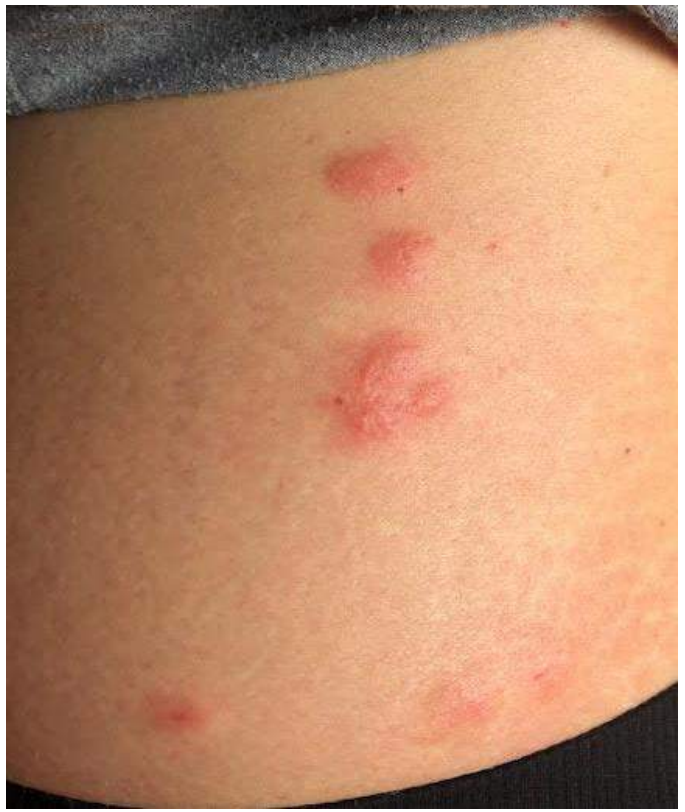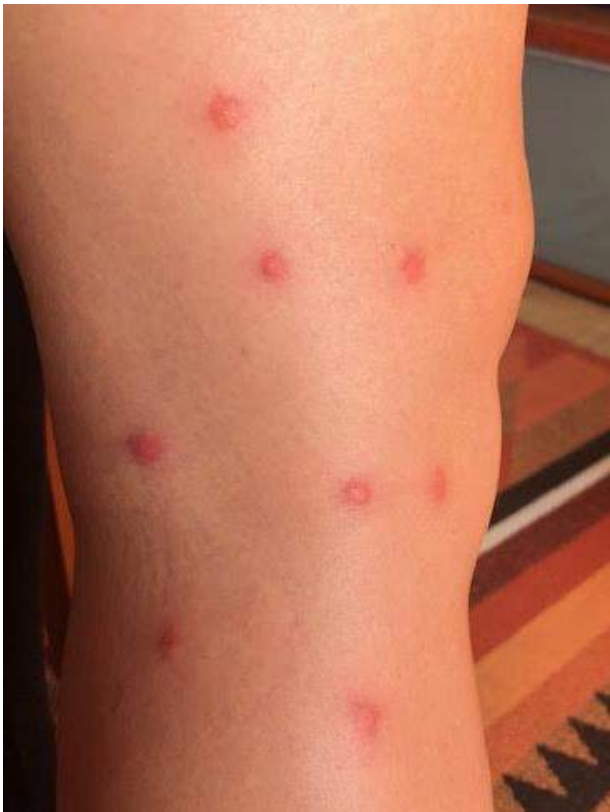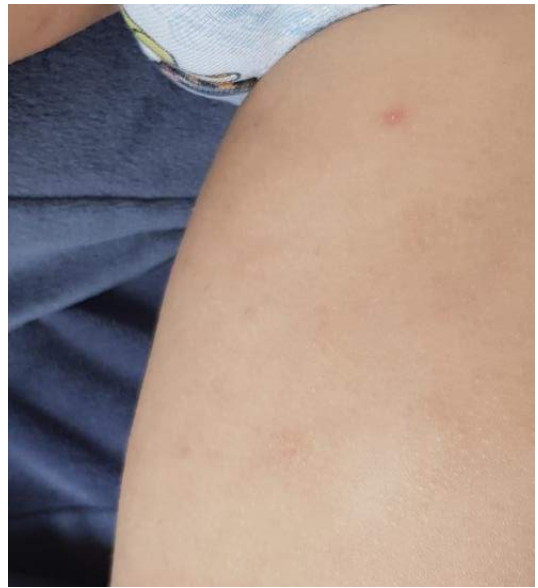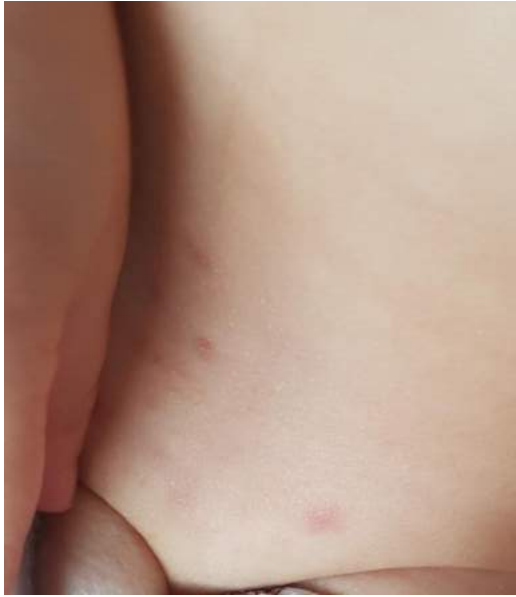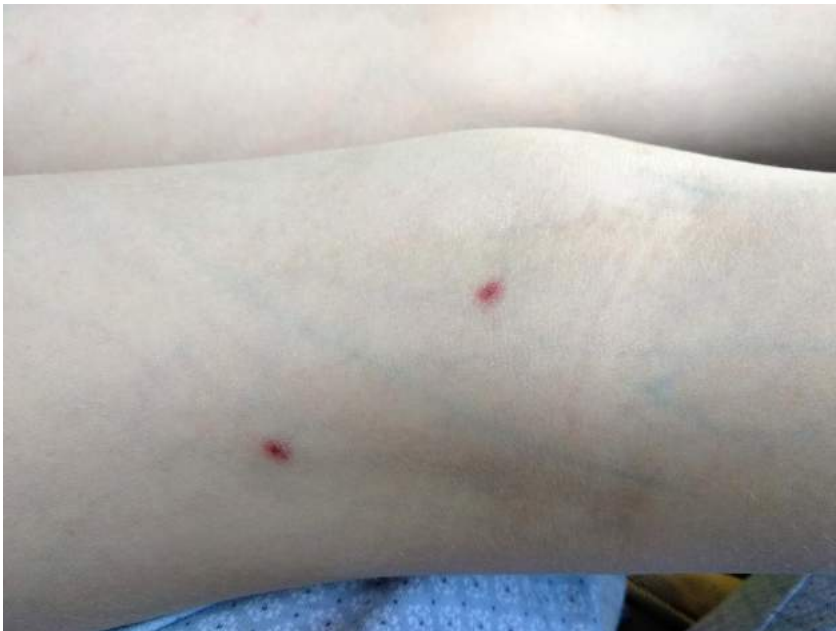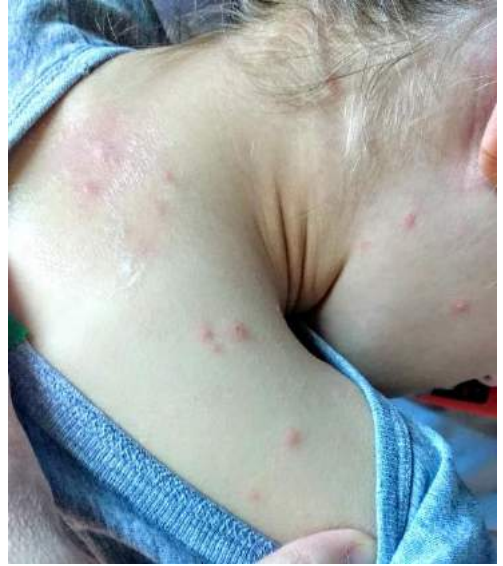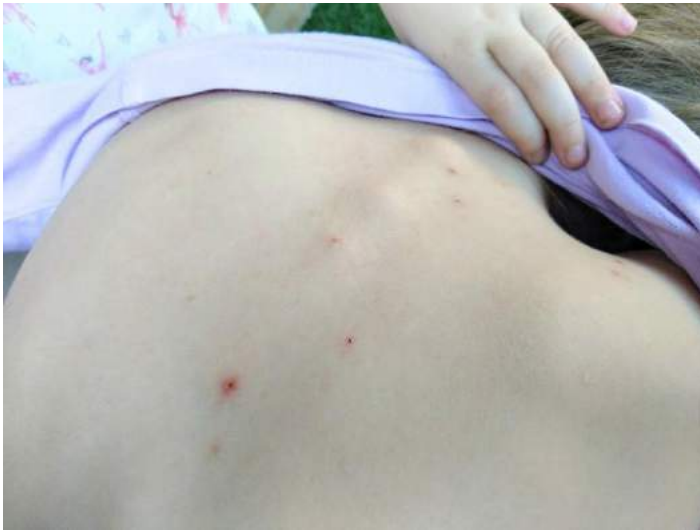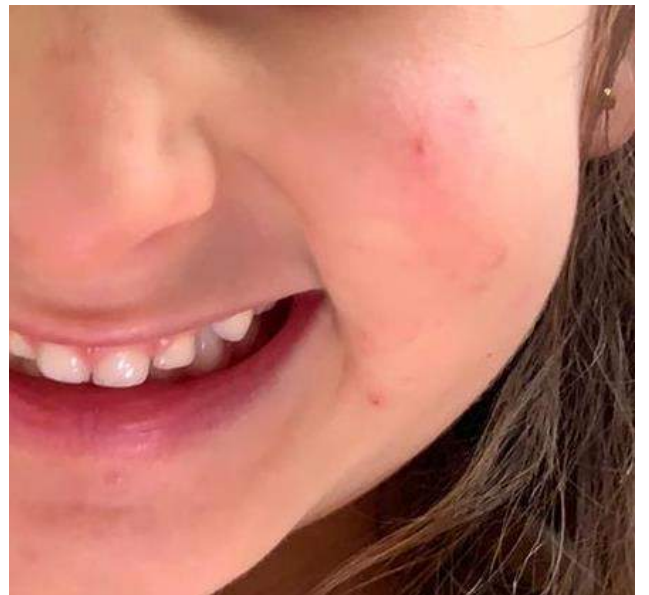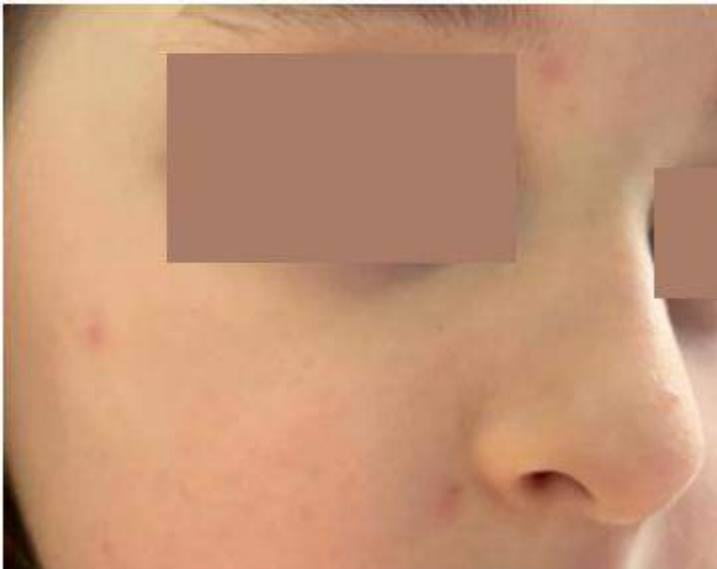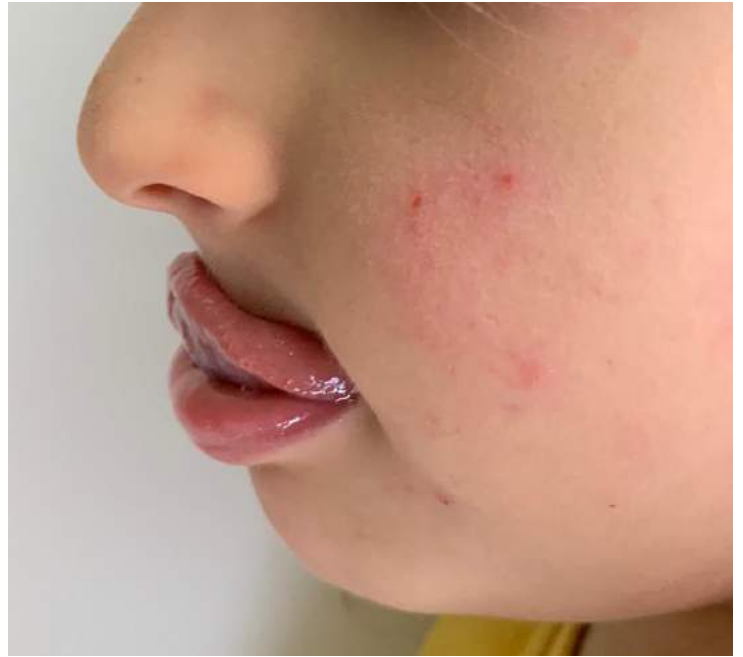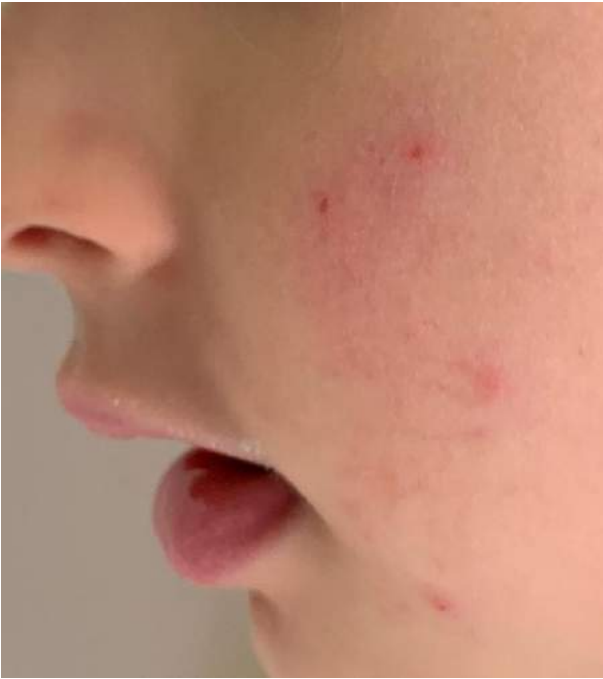Vesicular Eruption – Suspected cases

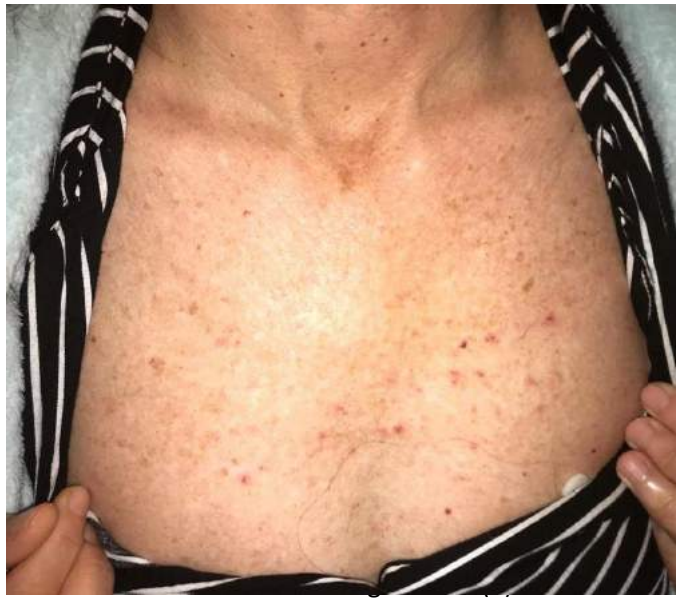
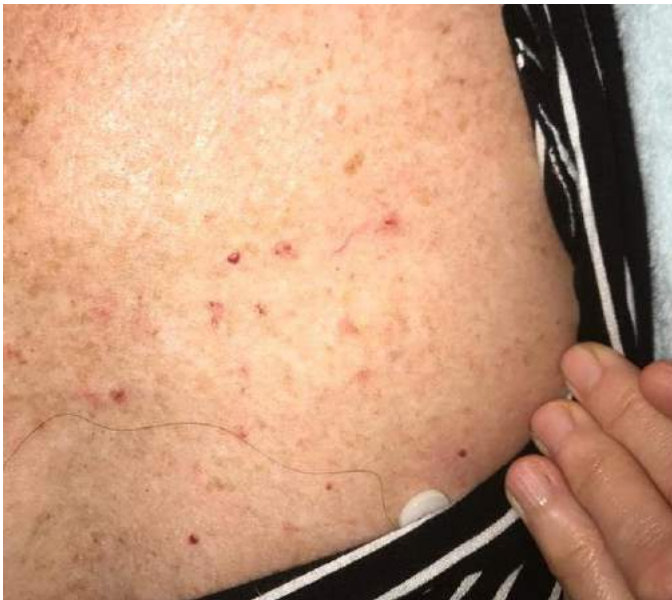
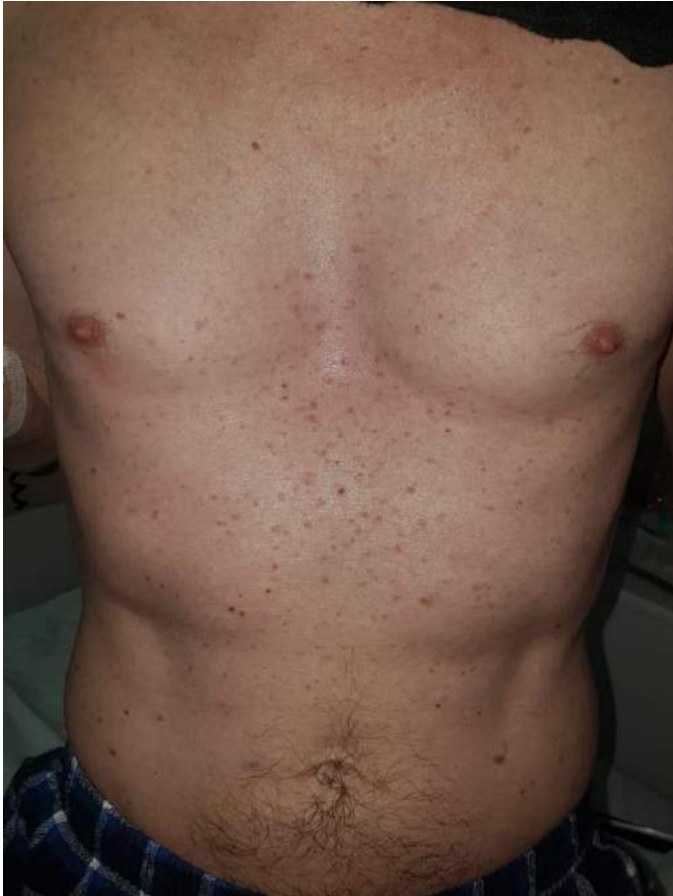


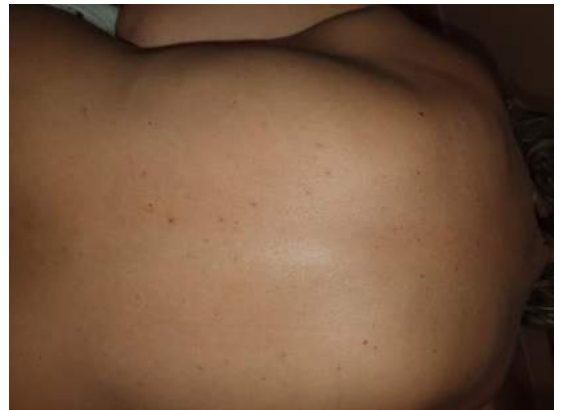
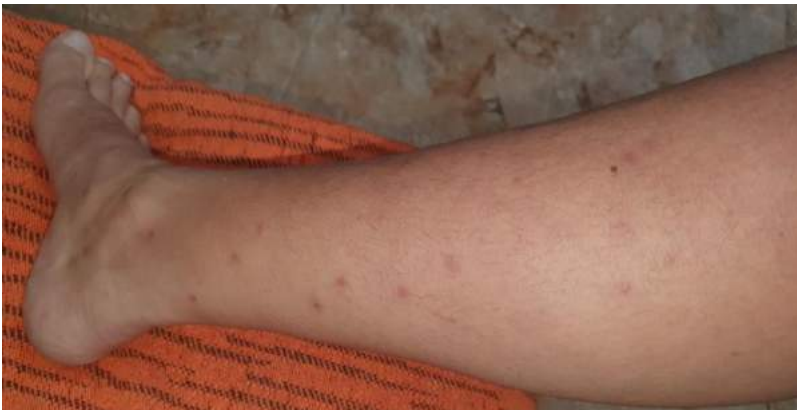
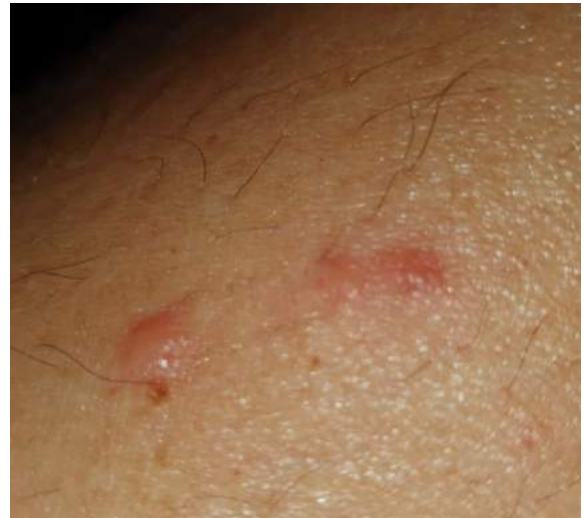
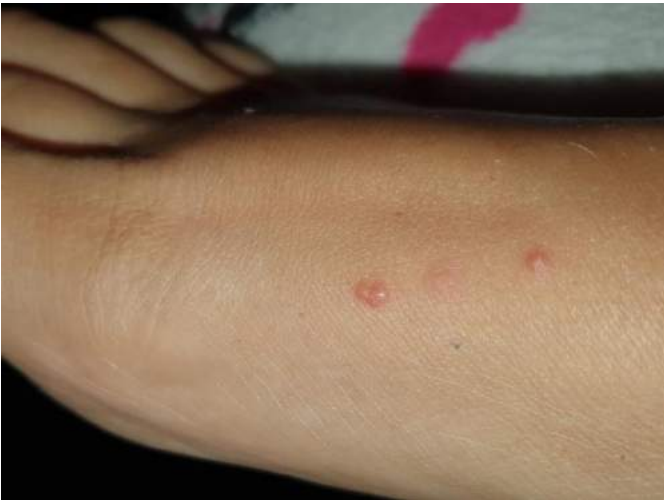
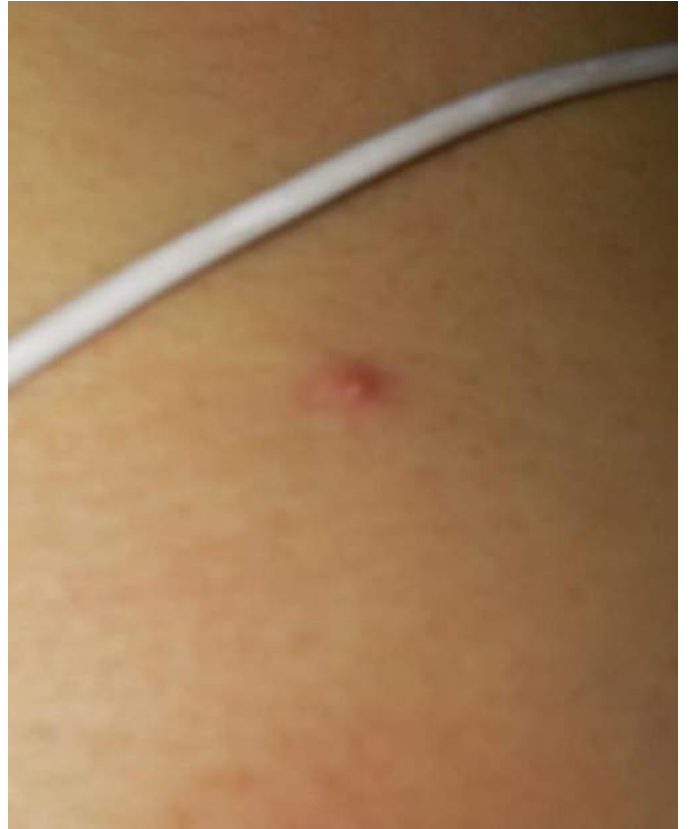
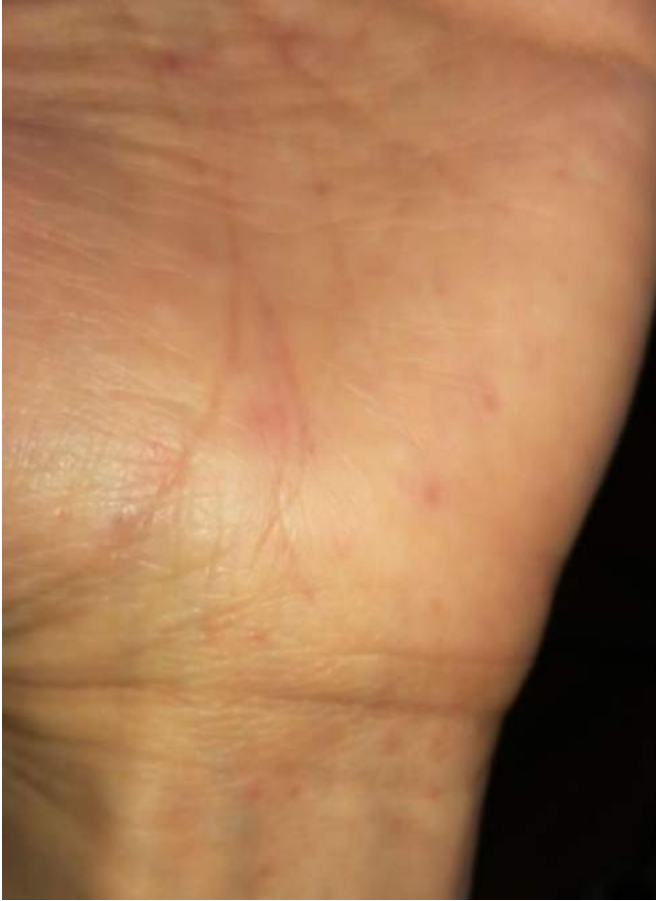


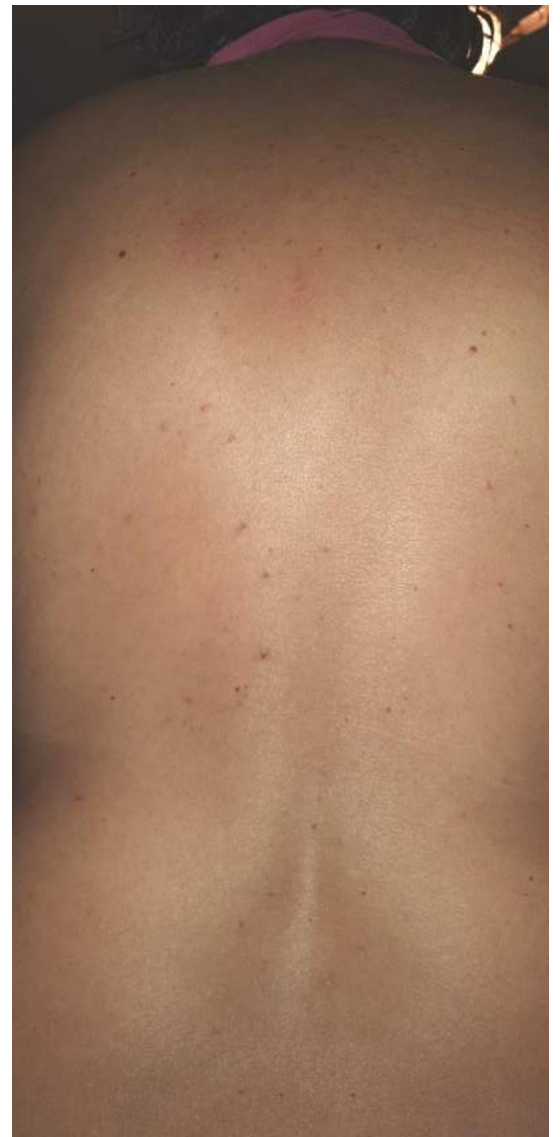
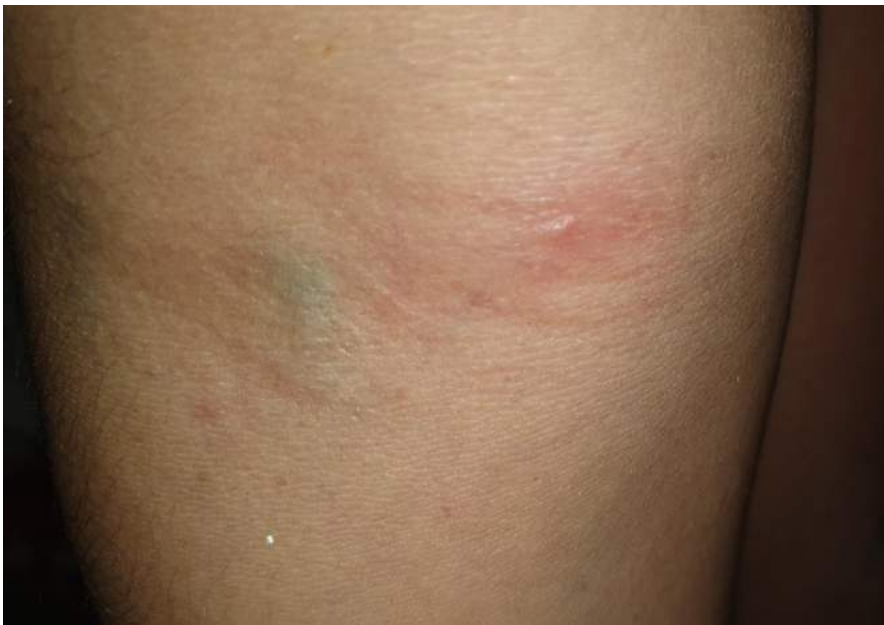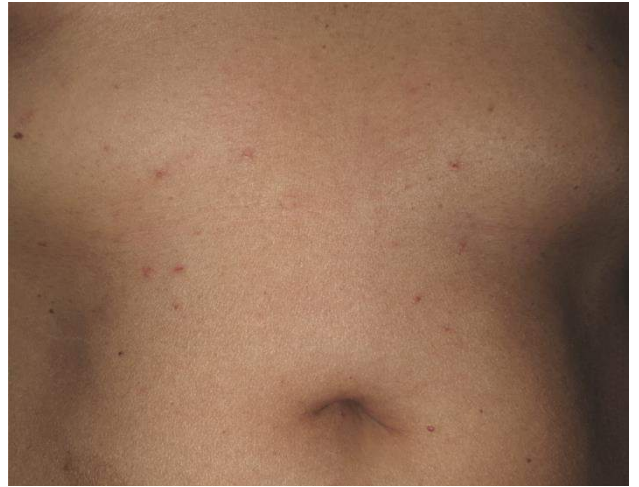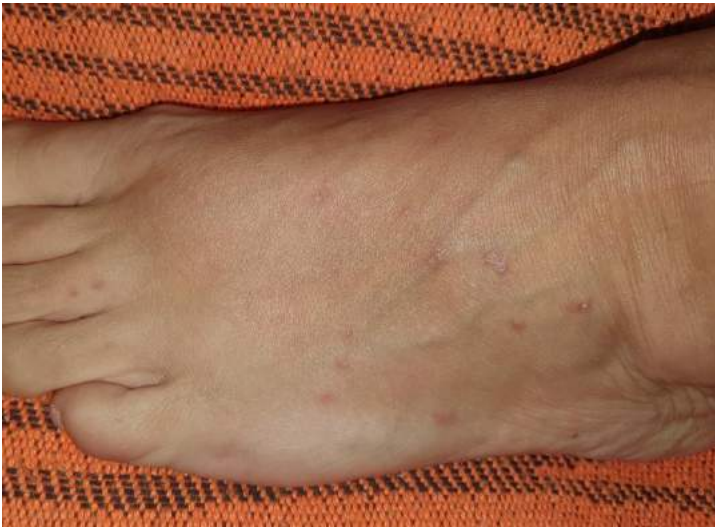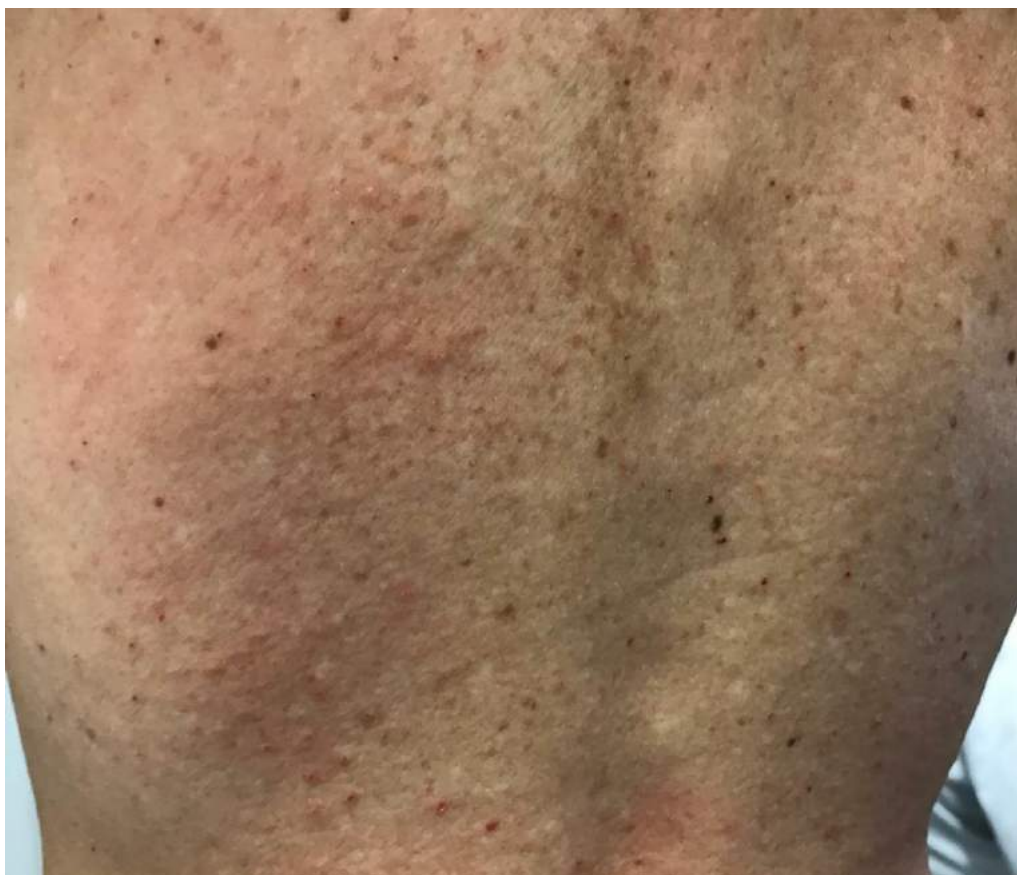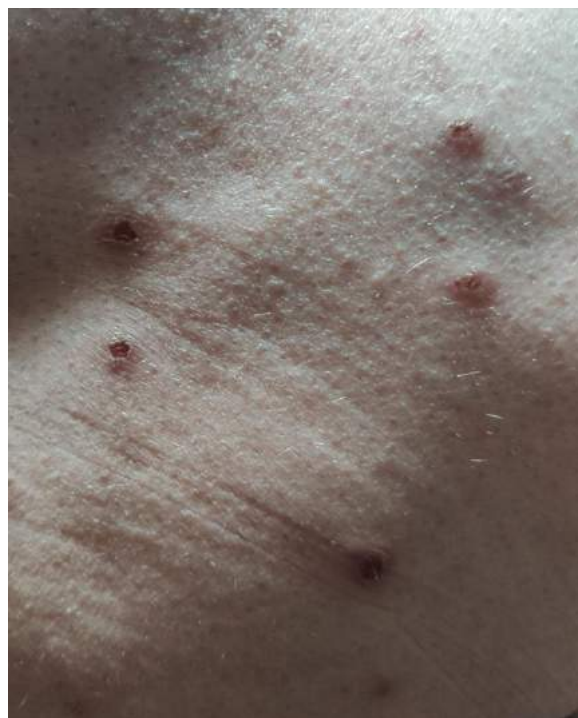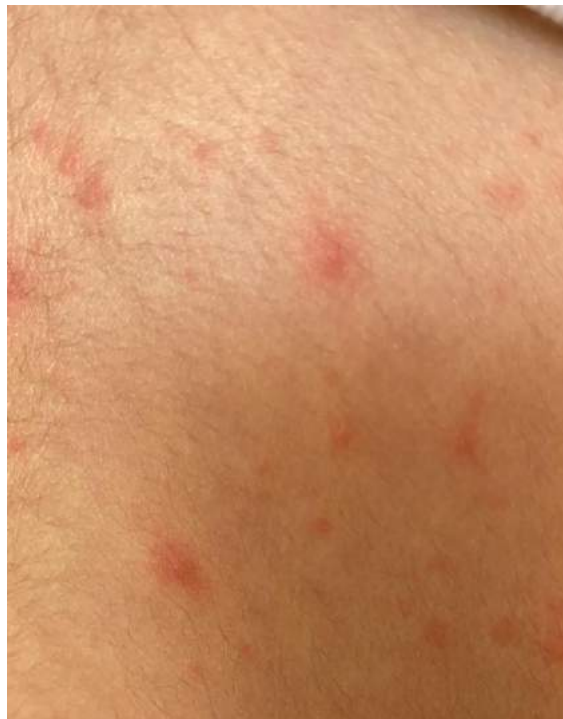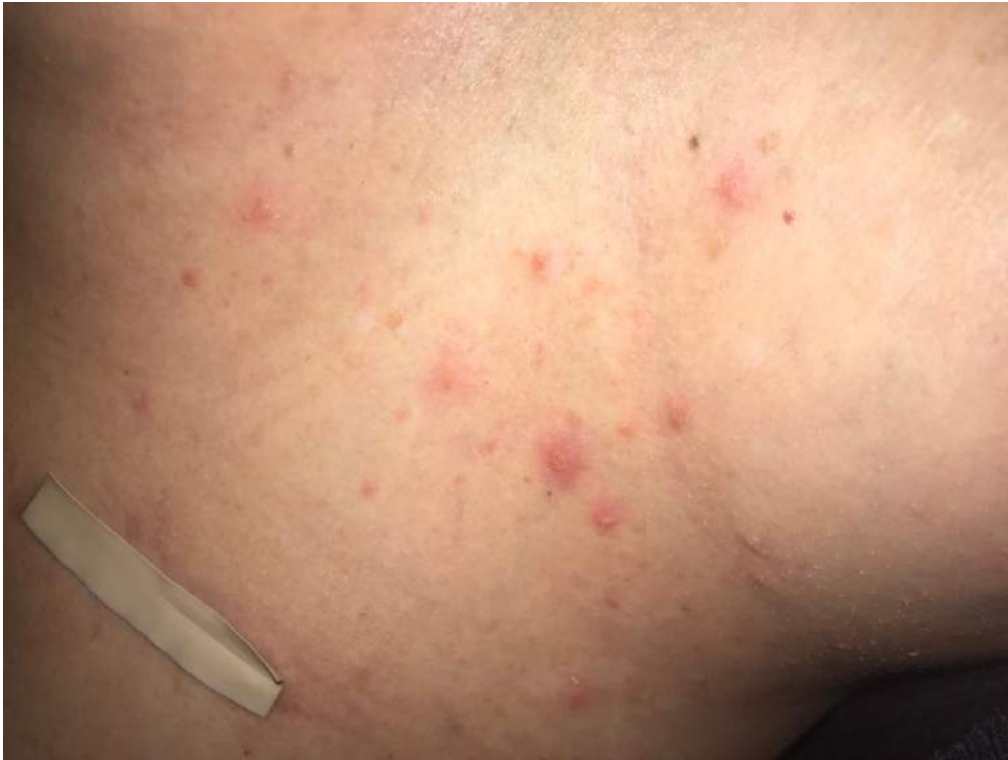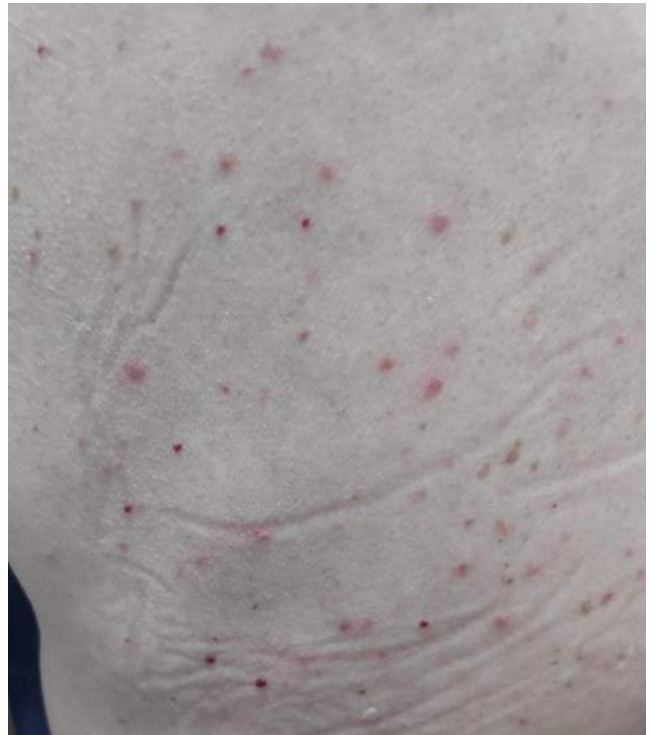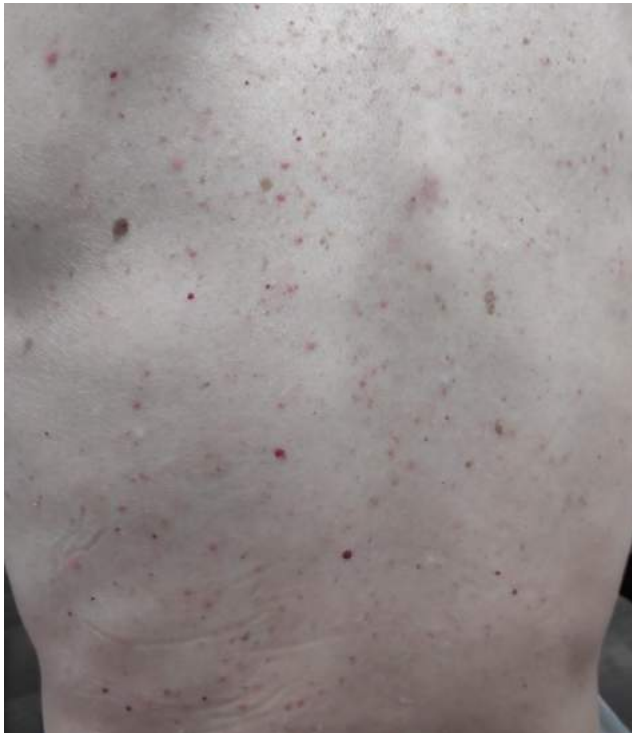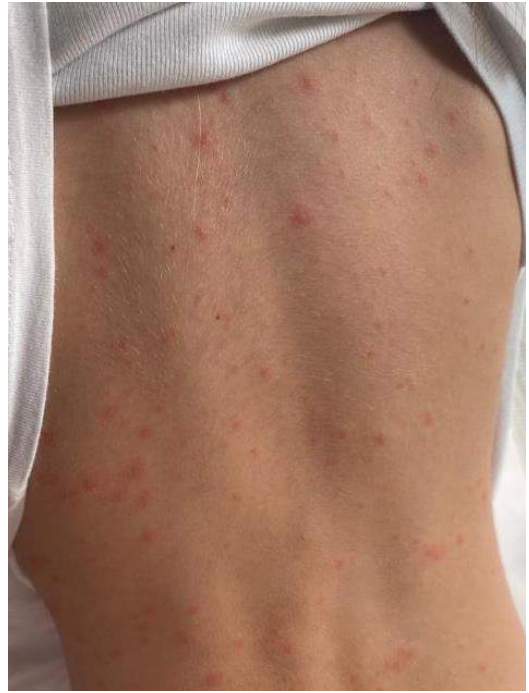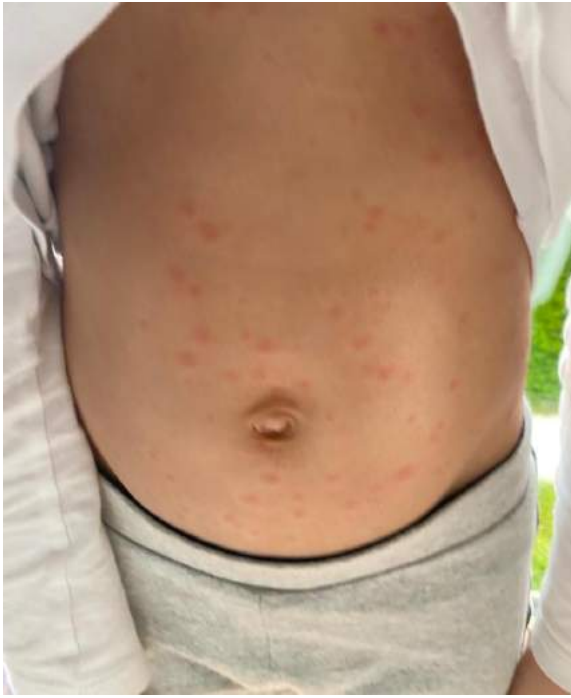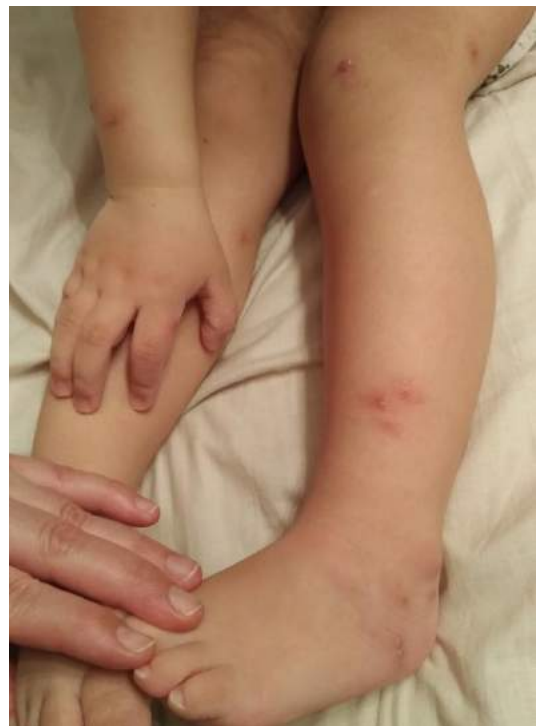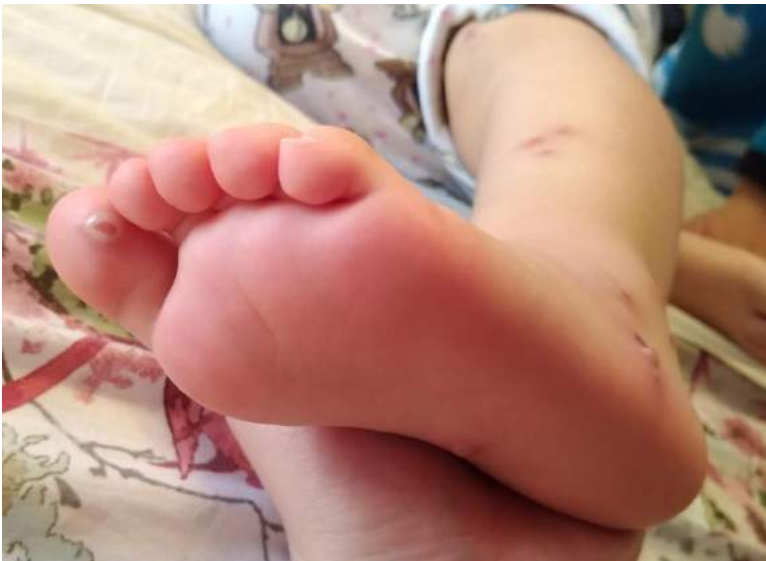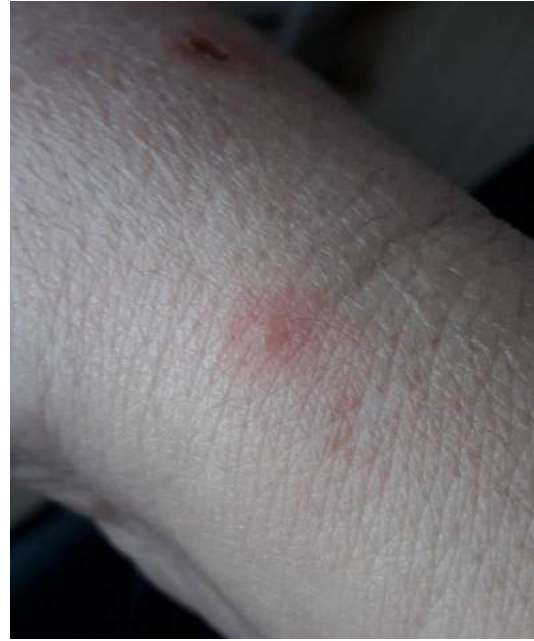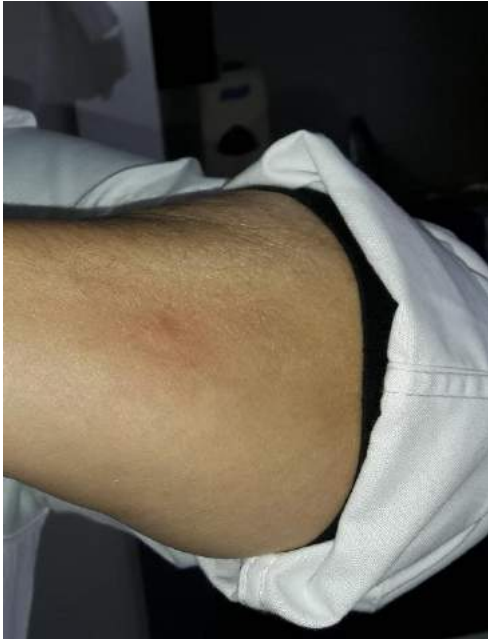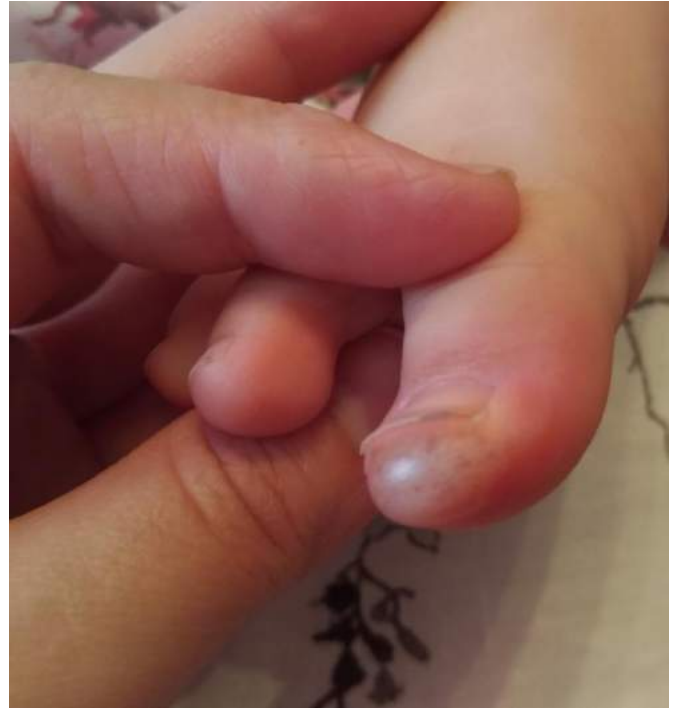












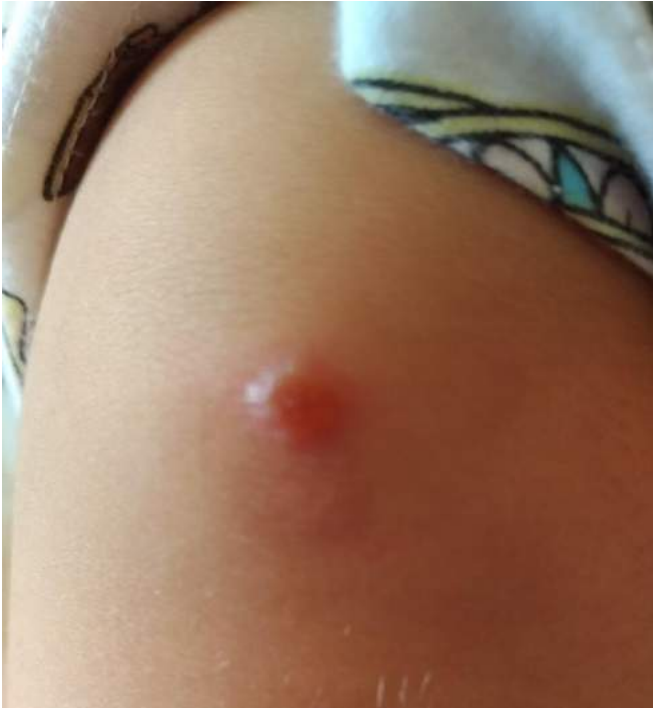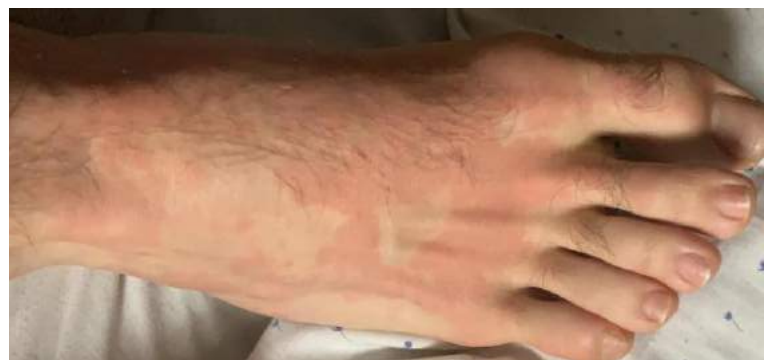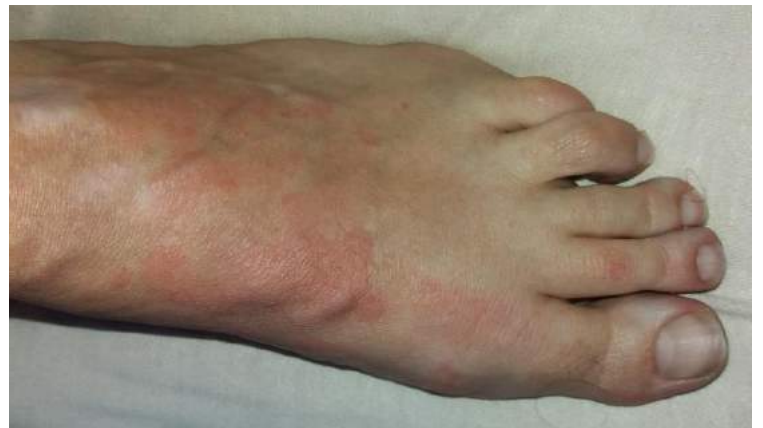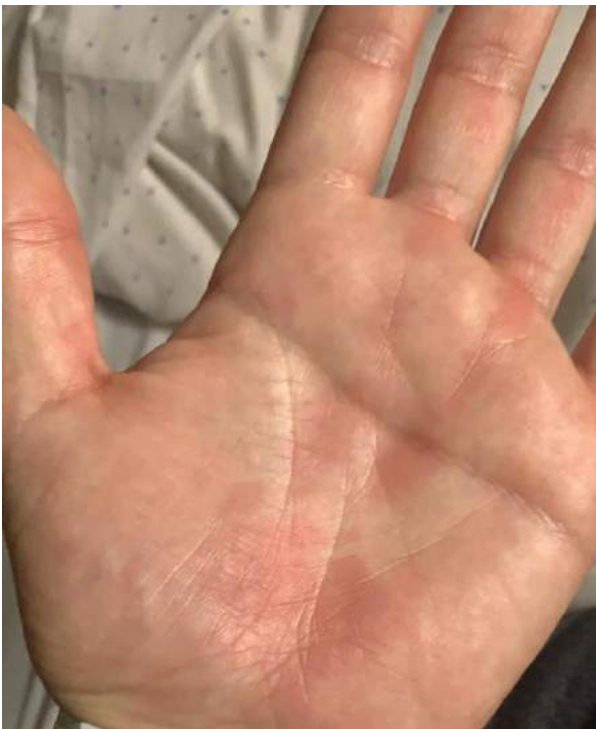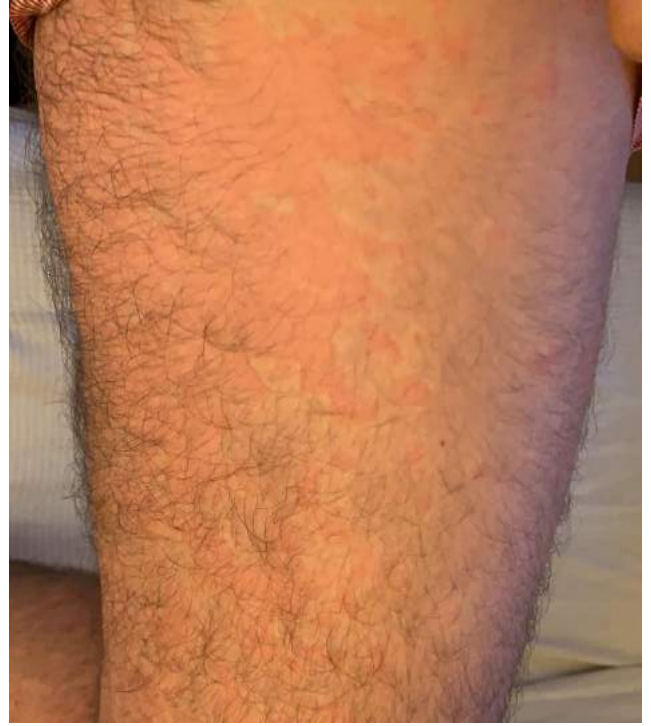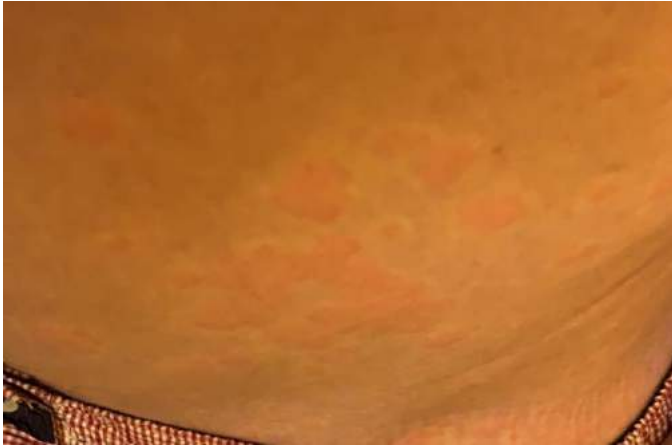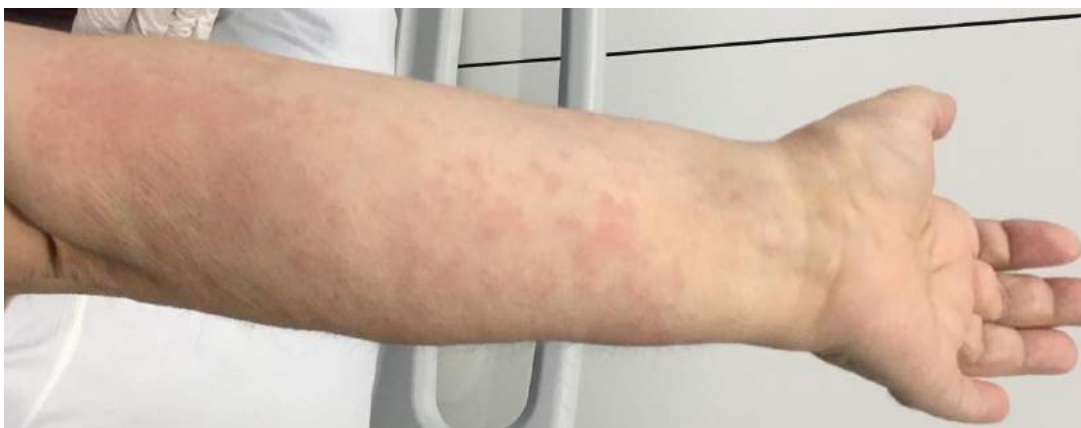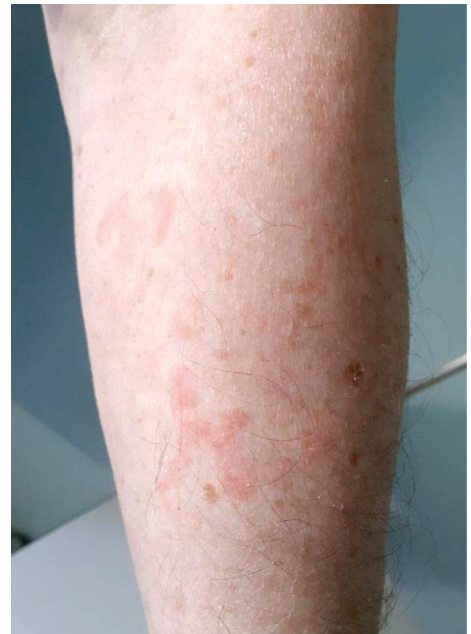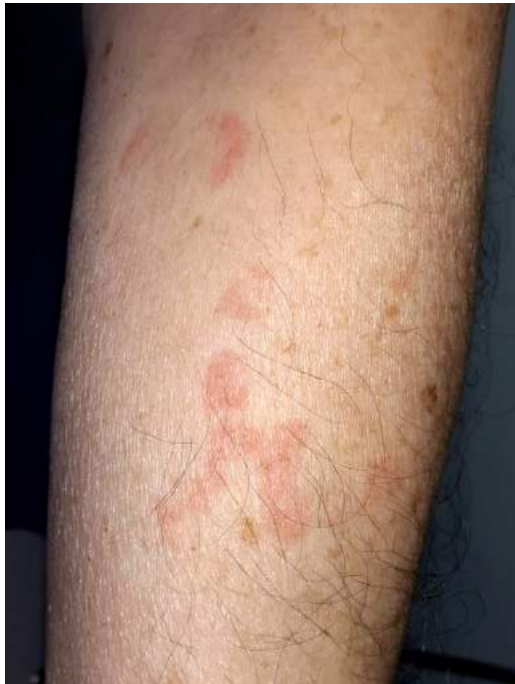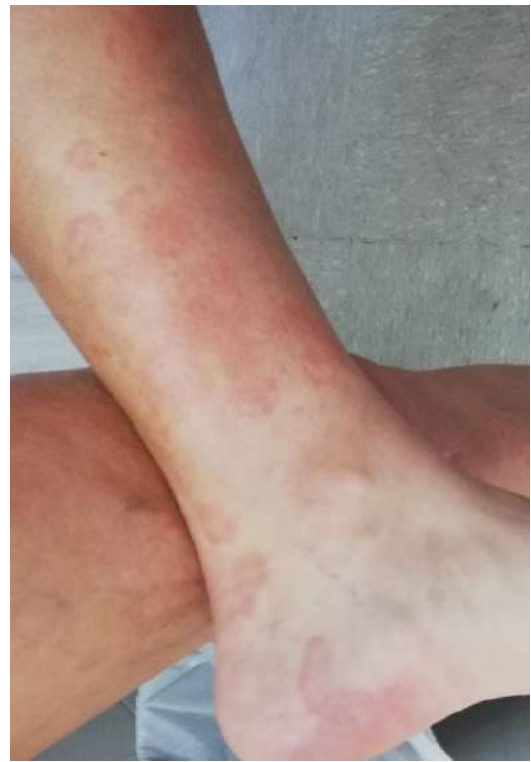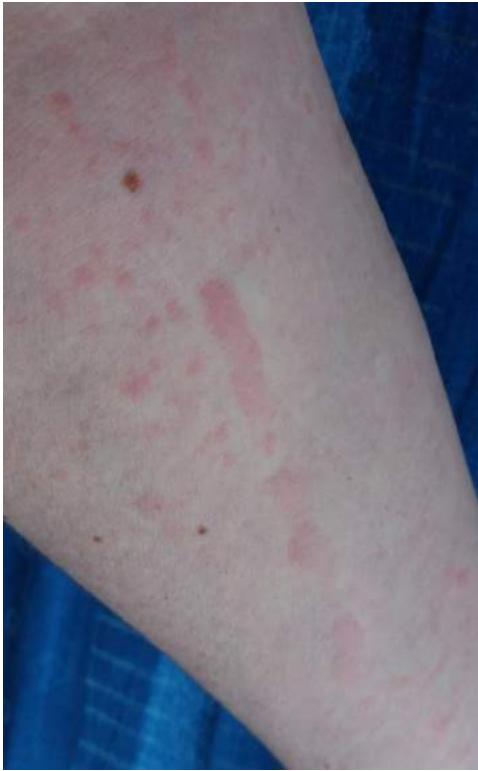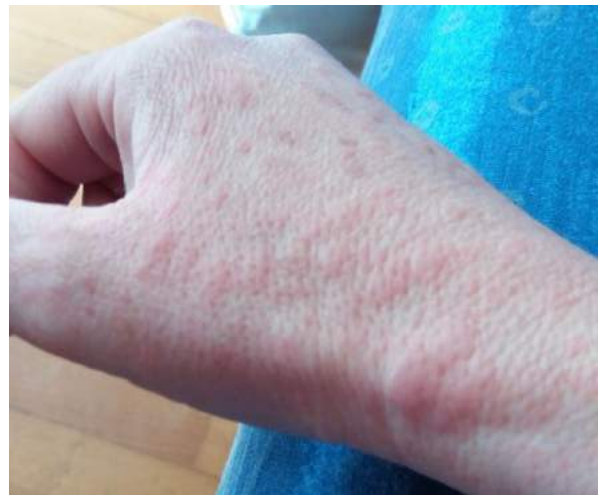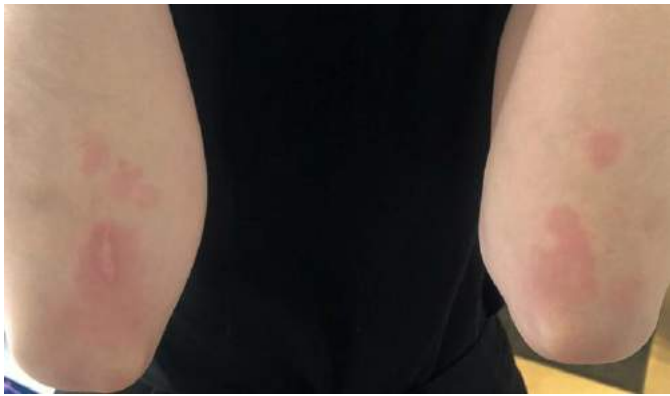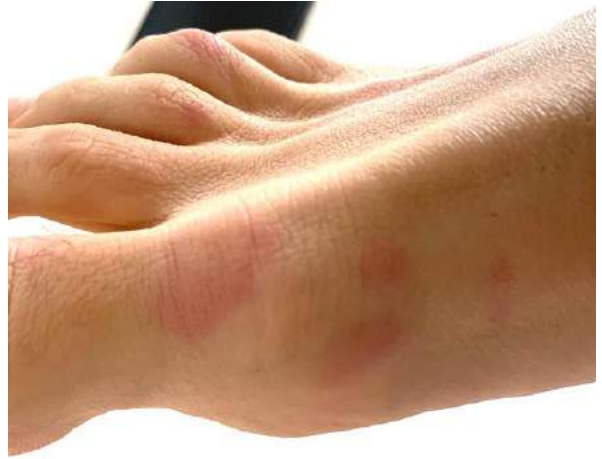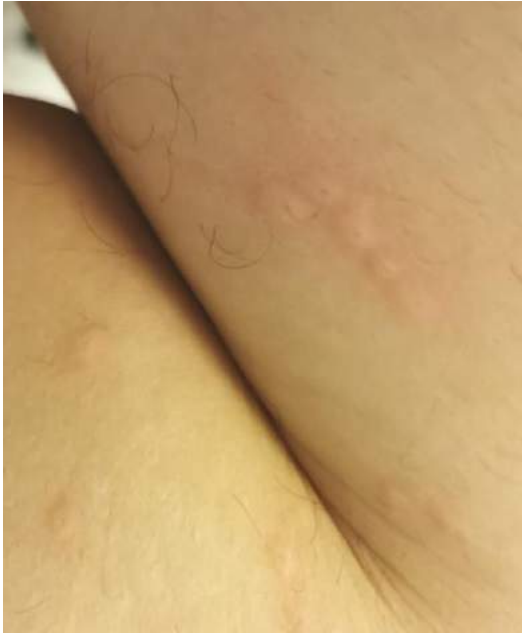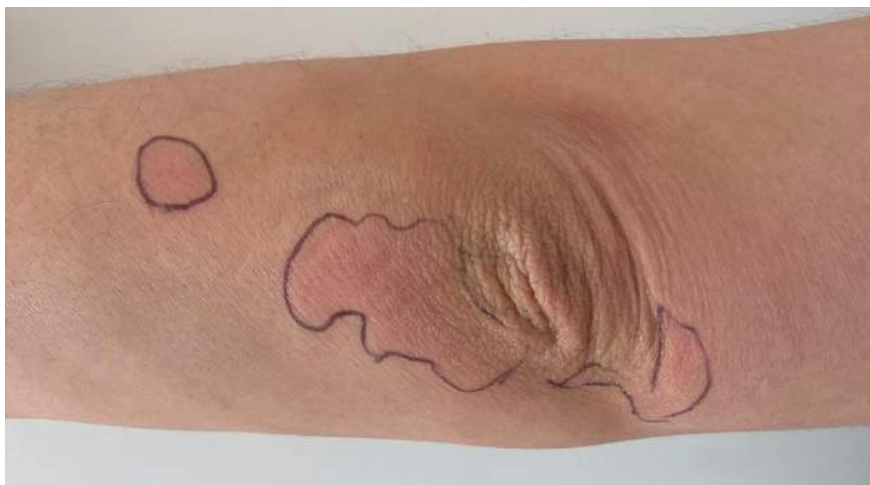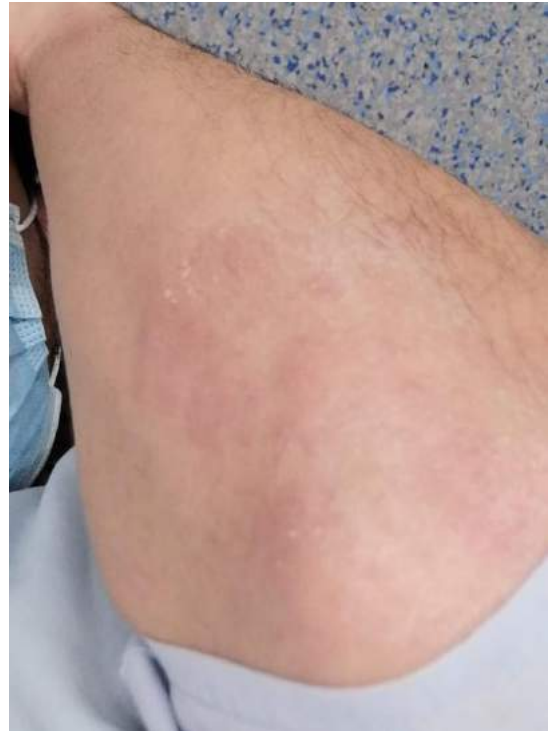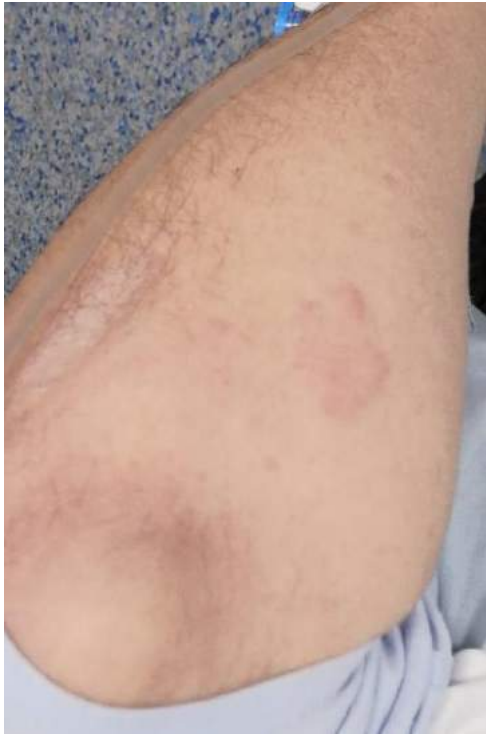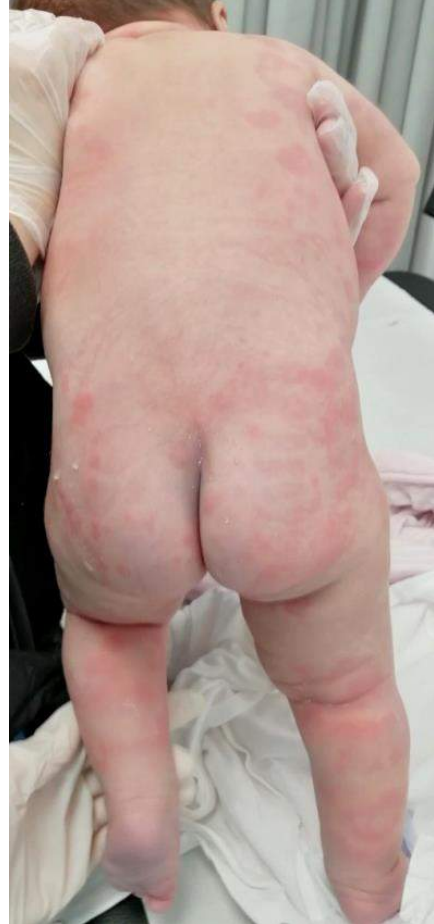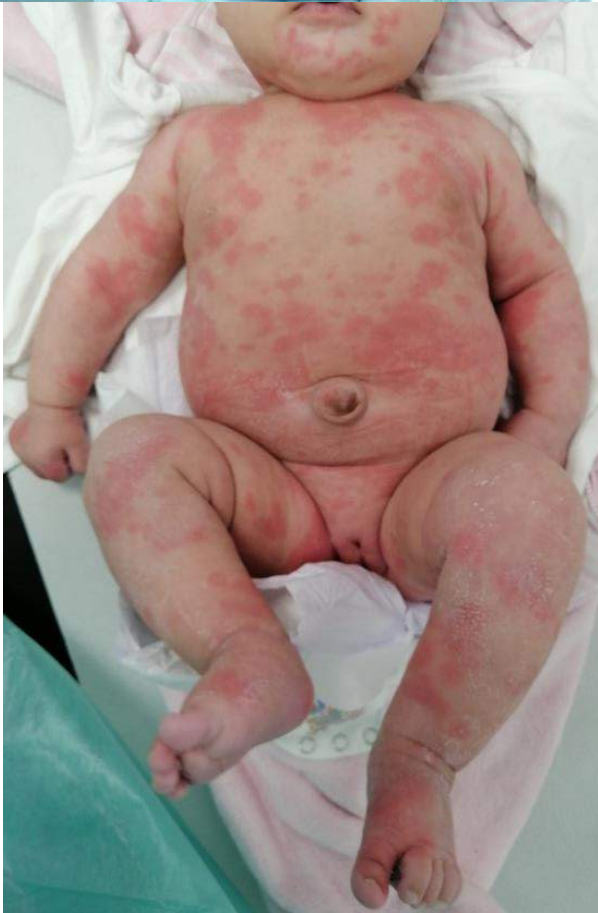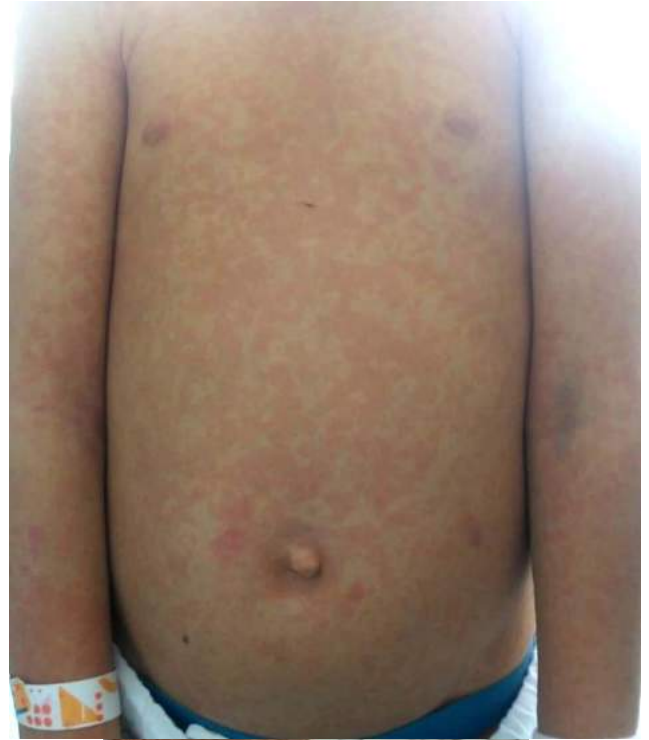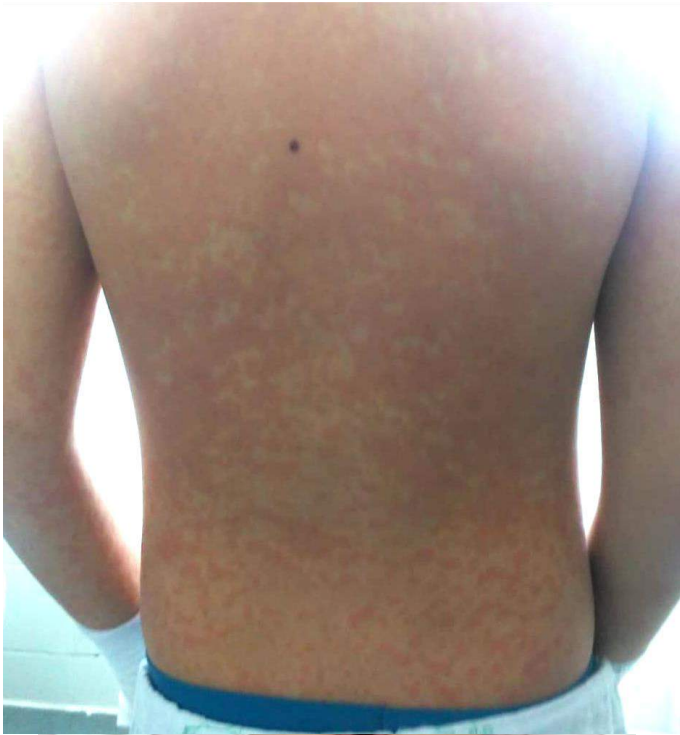Urticarial Eruption – Confirmed cases

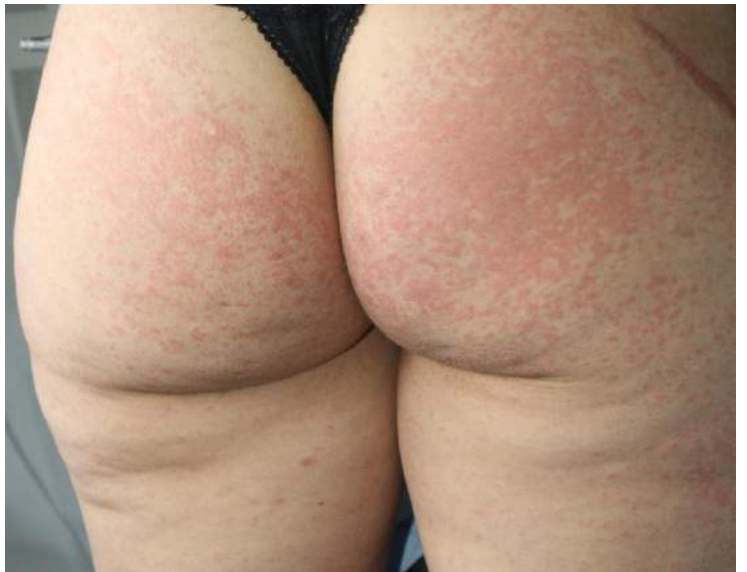
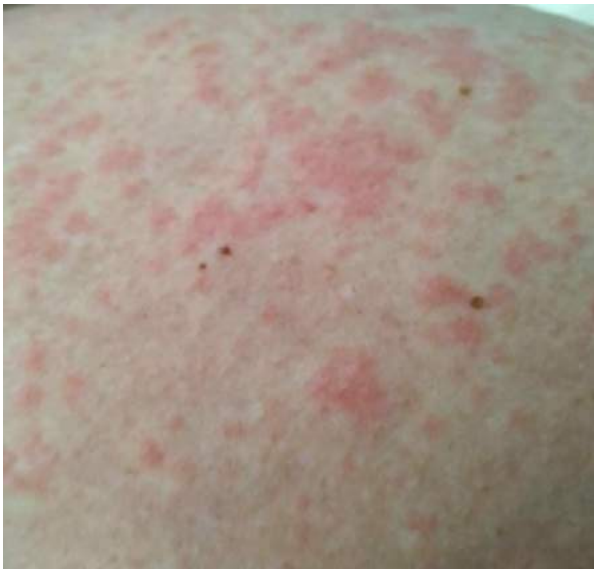
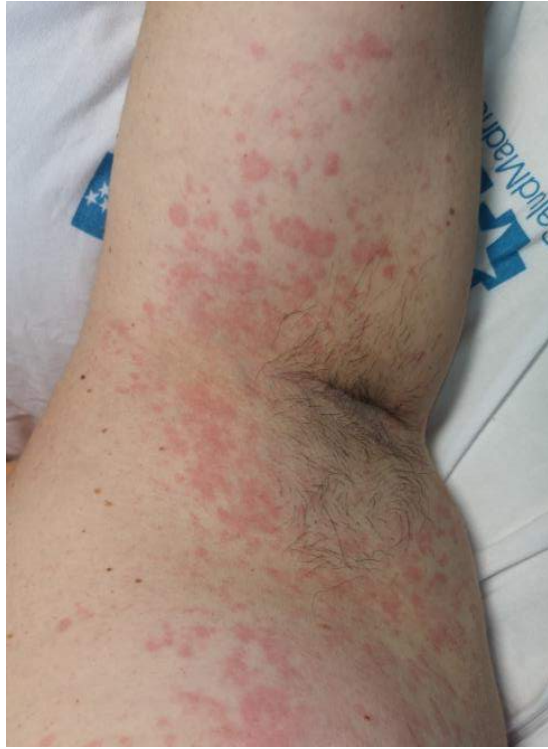
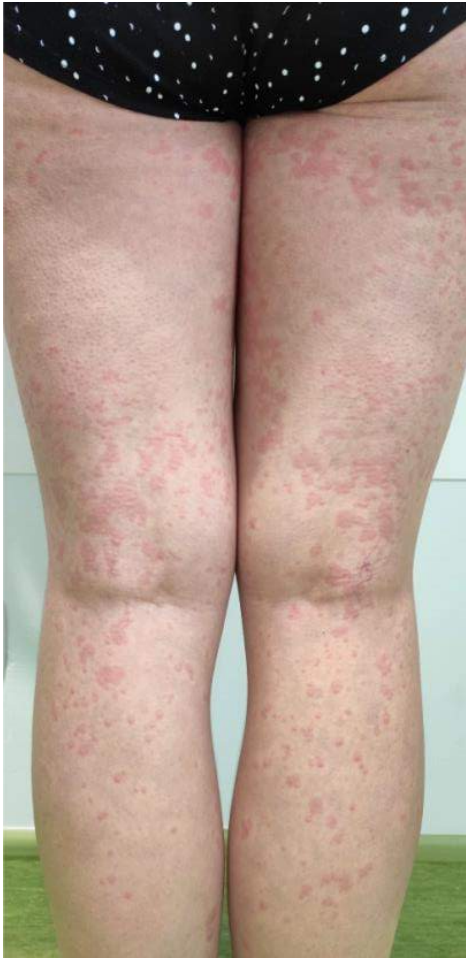


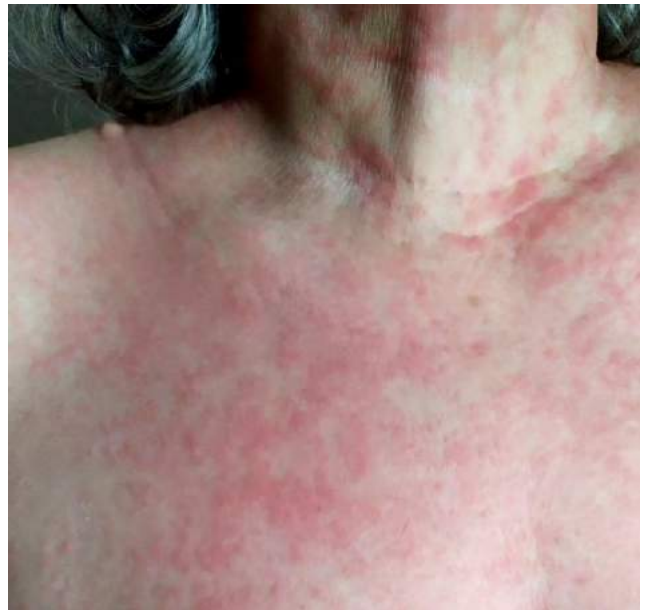
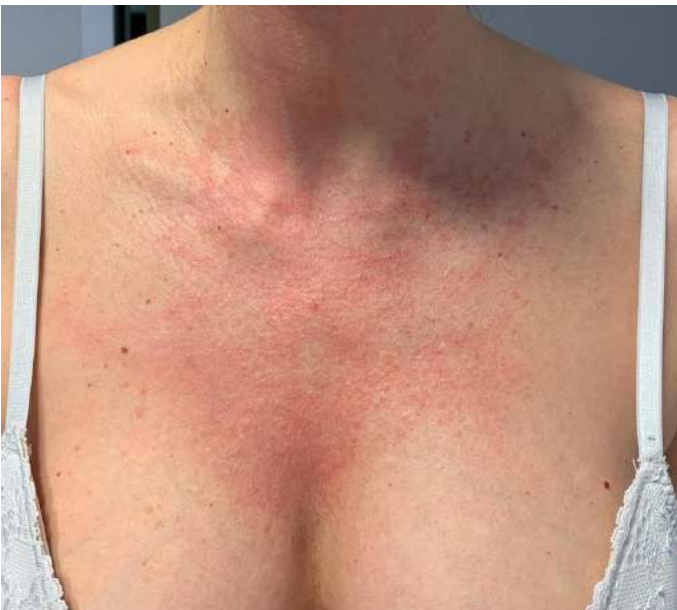
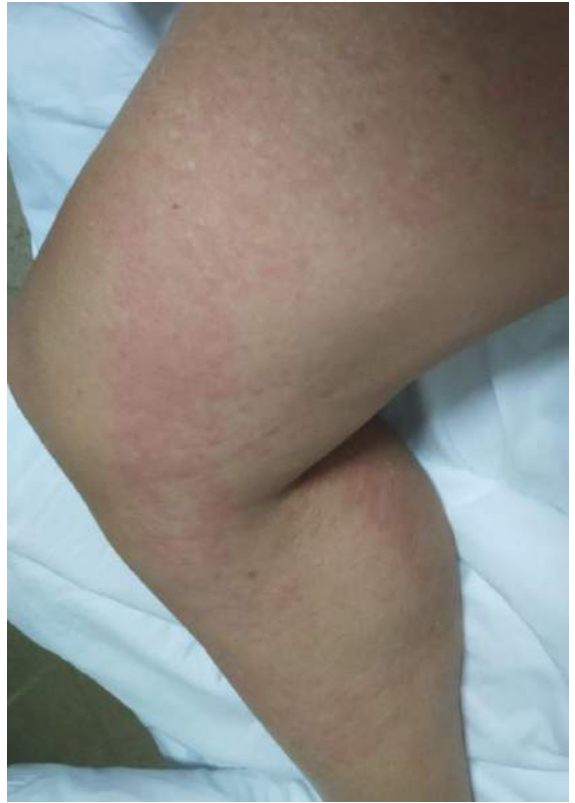
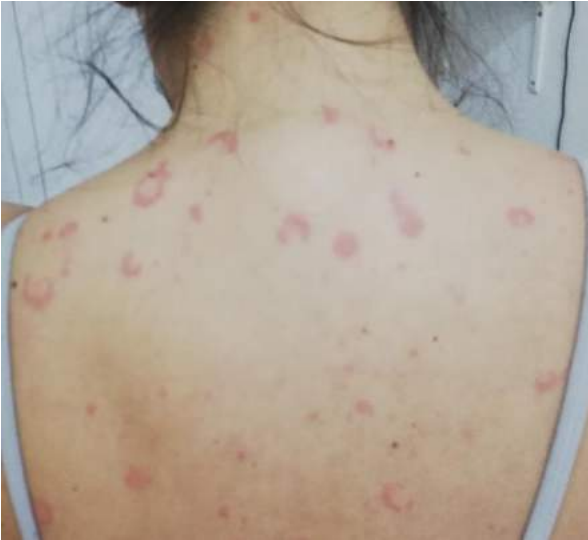


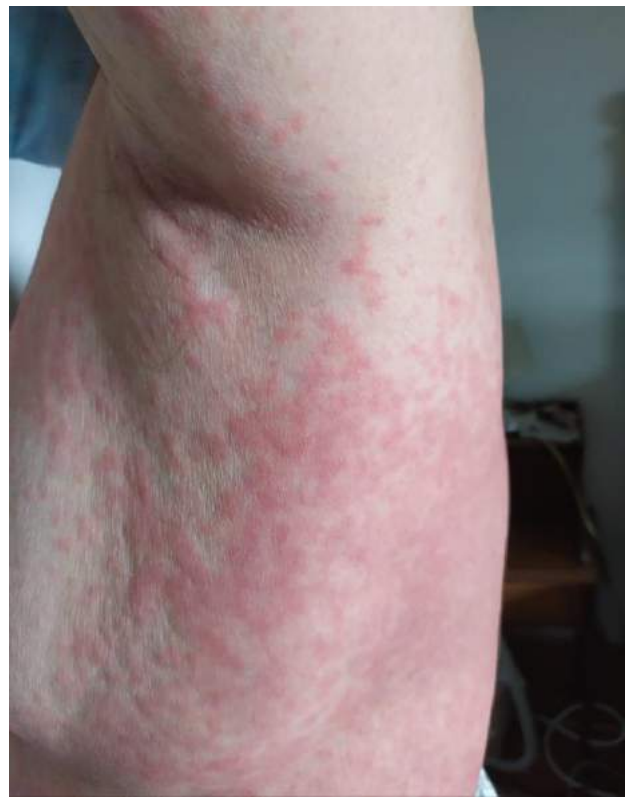
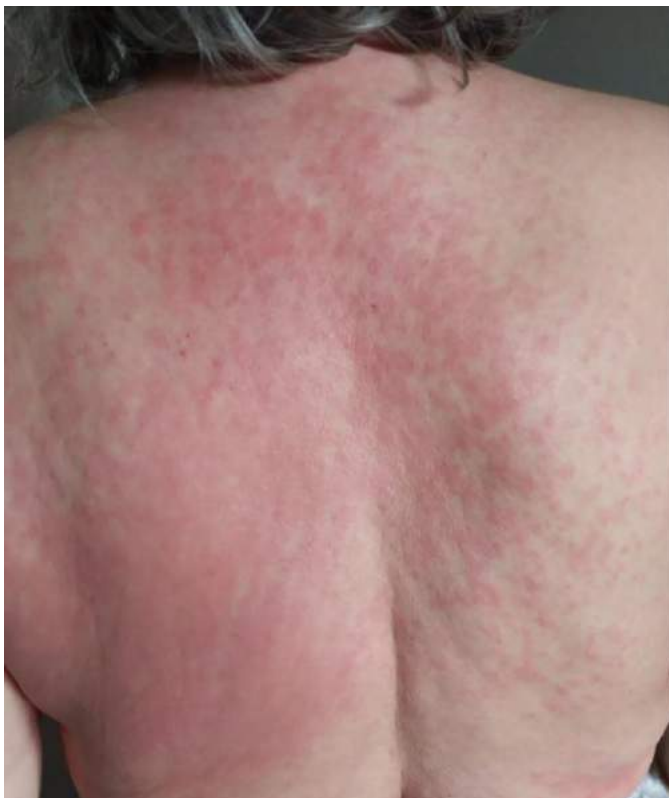
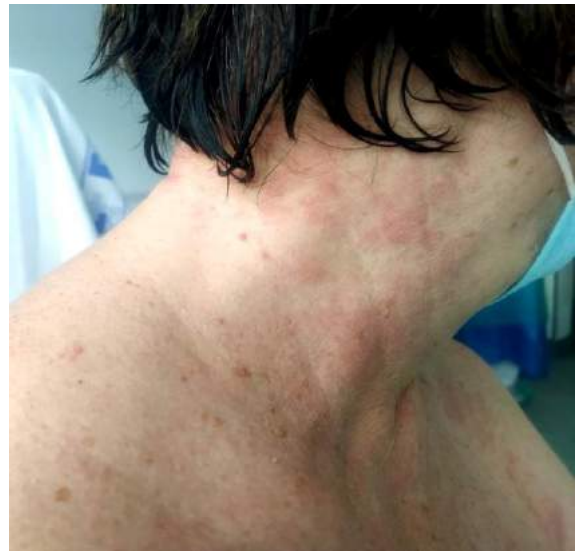
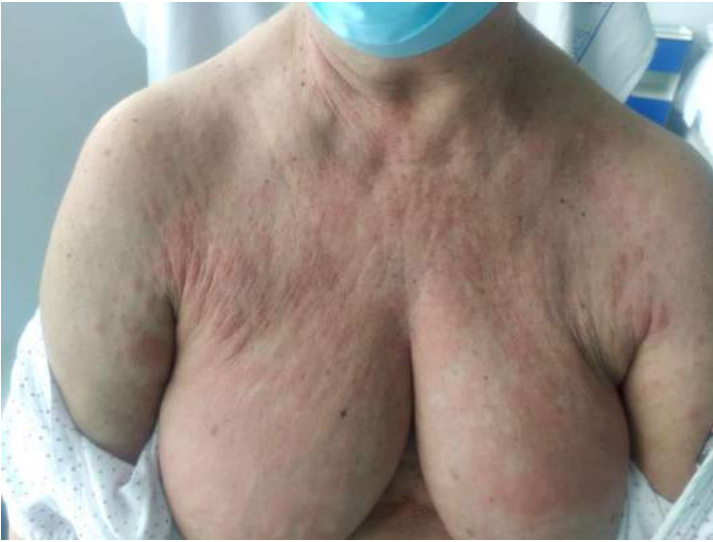


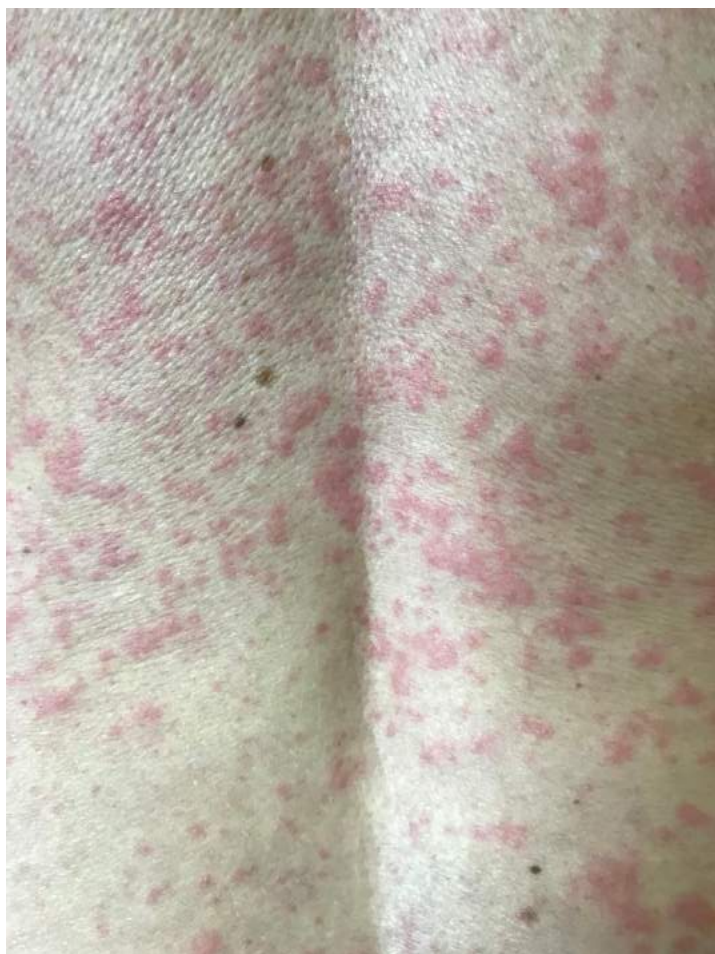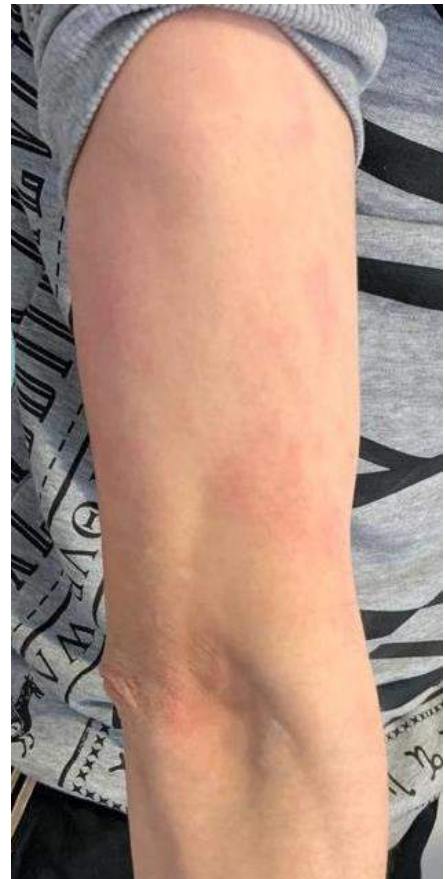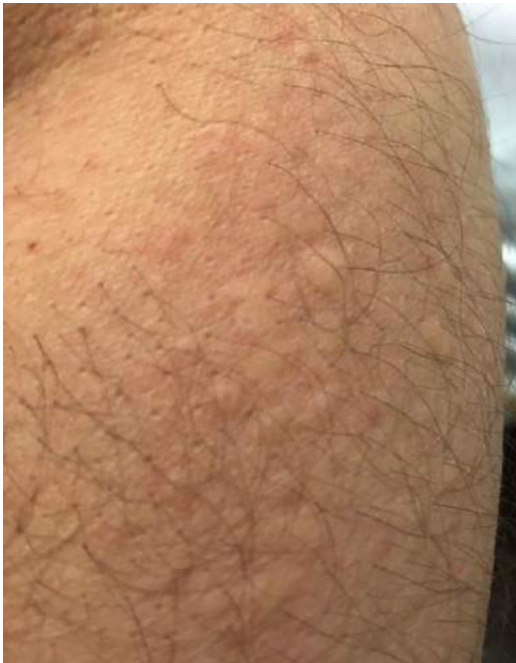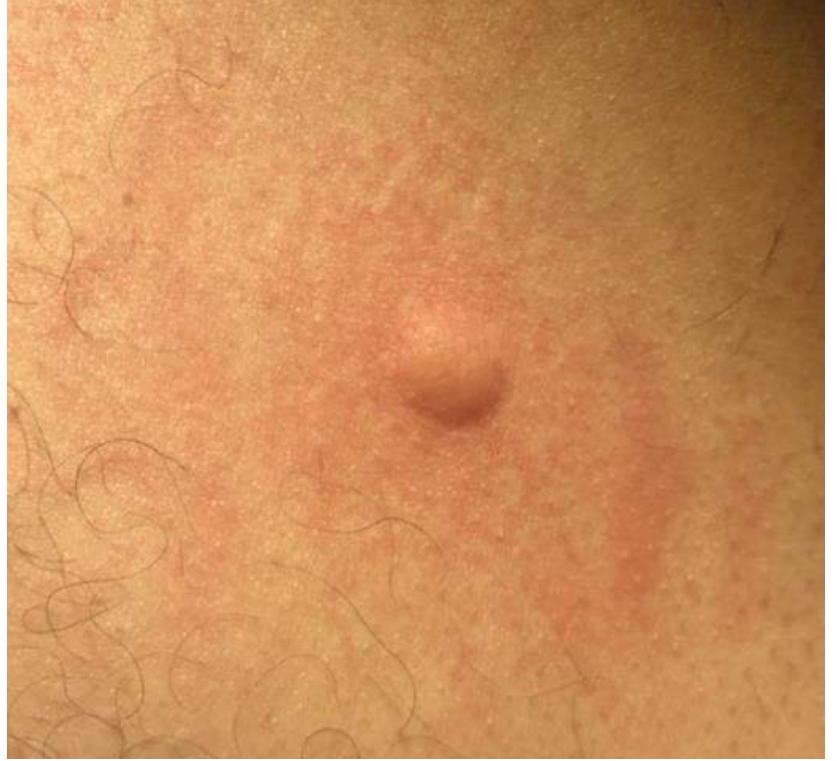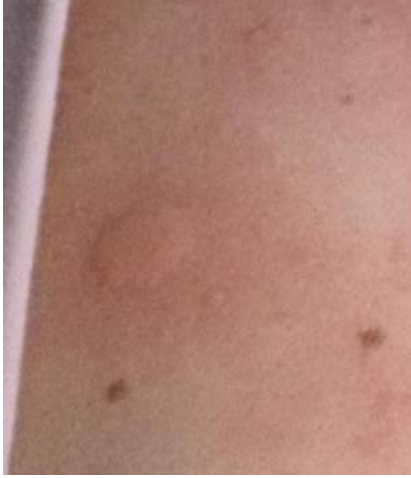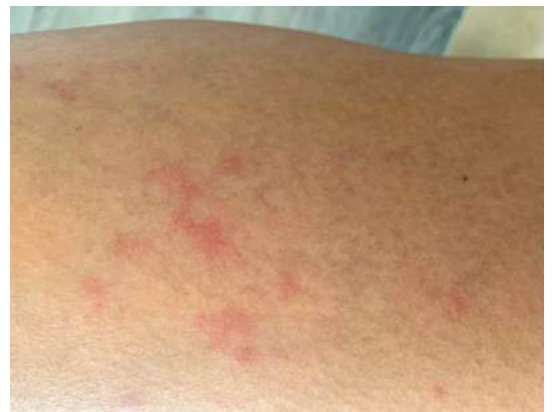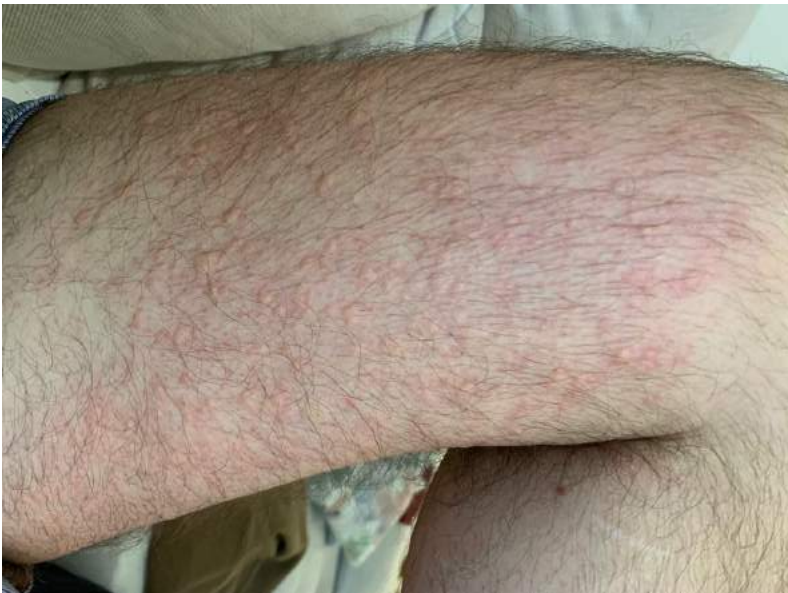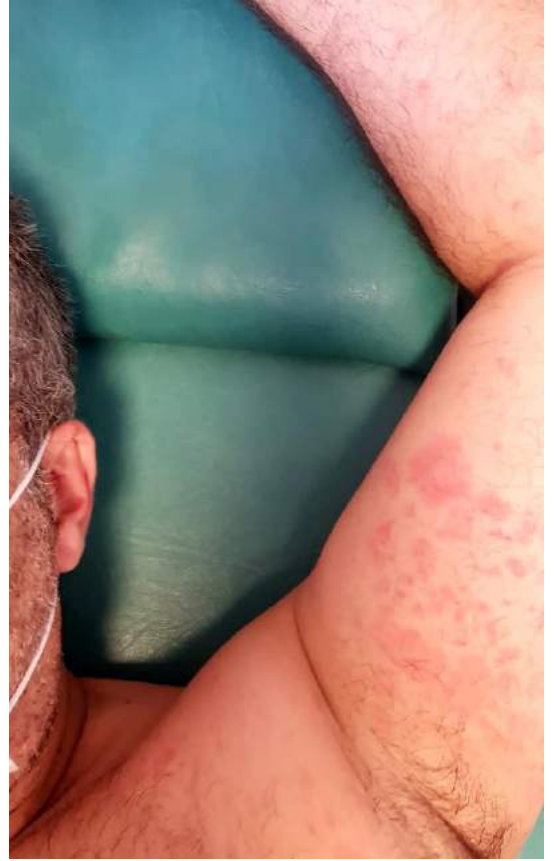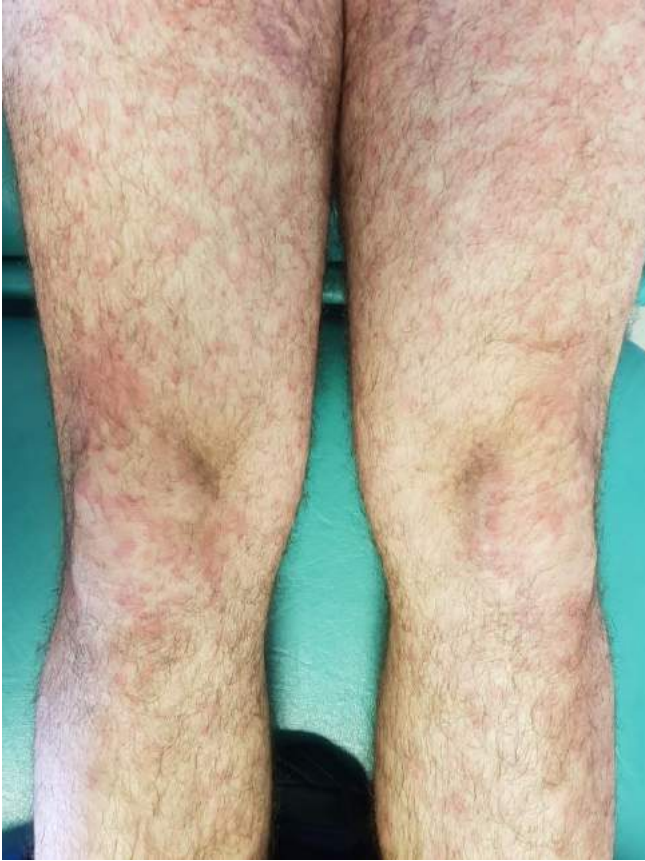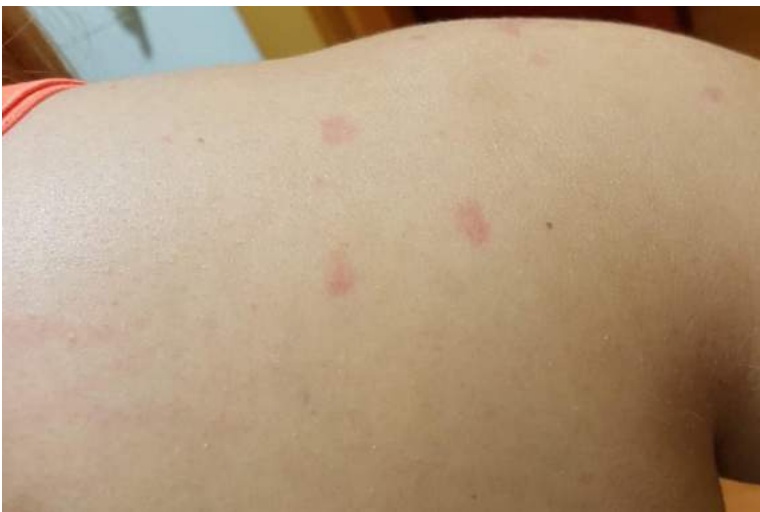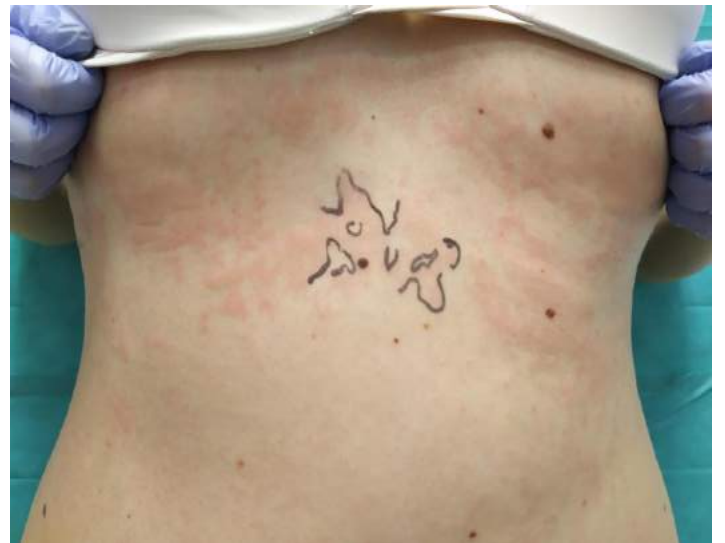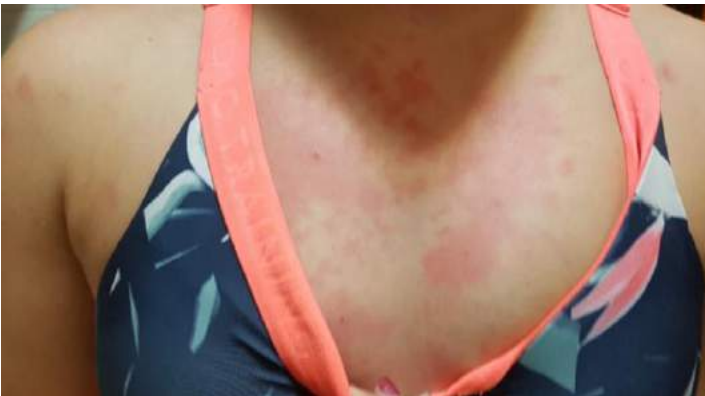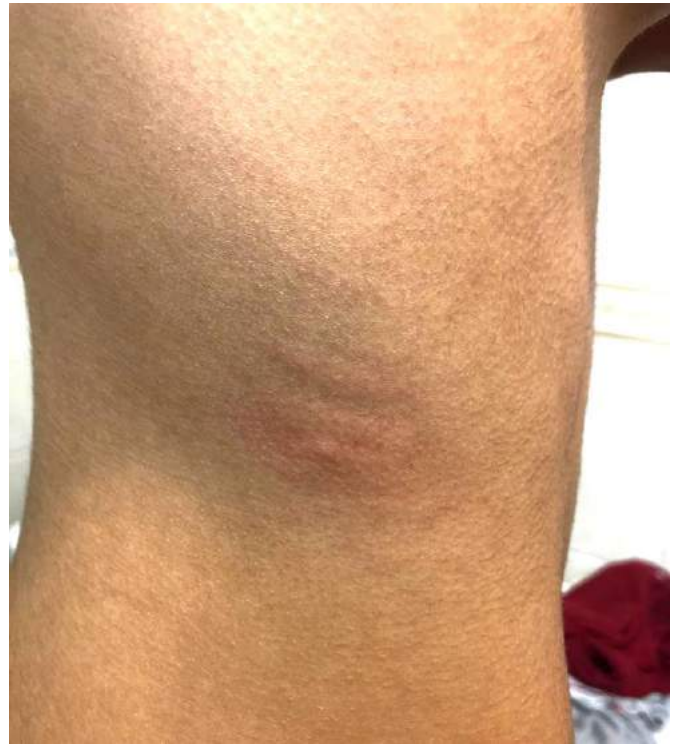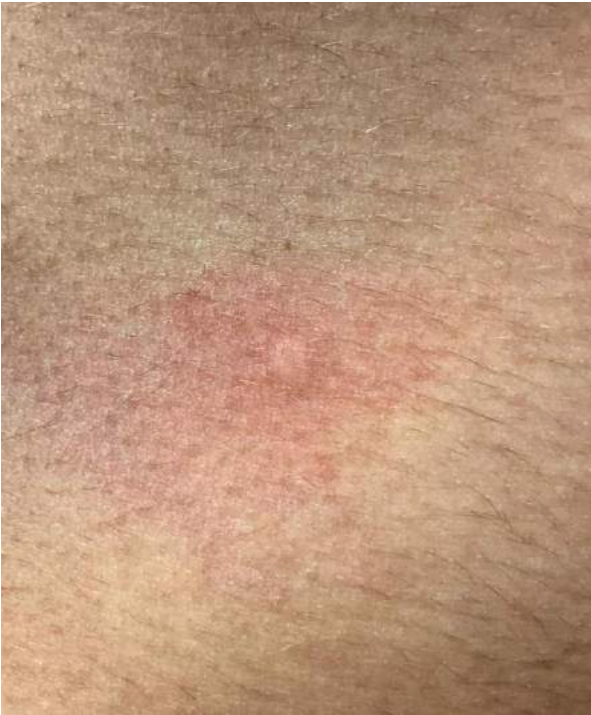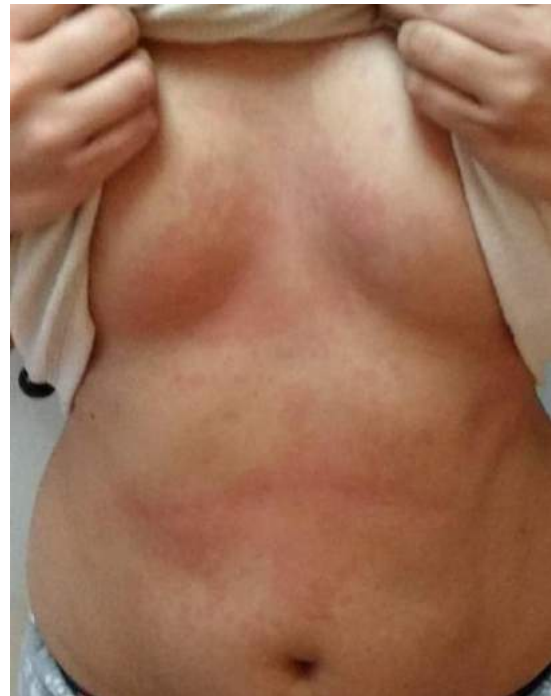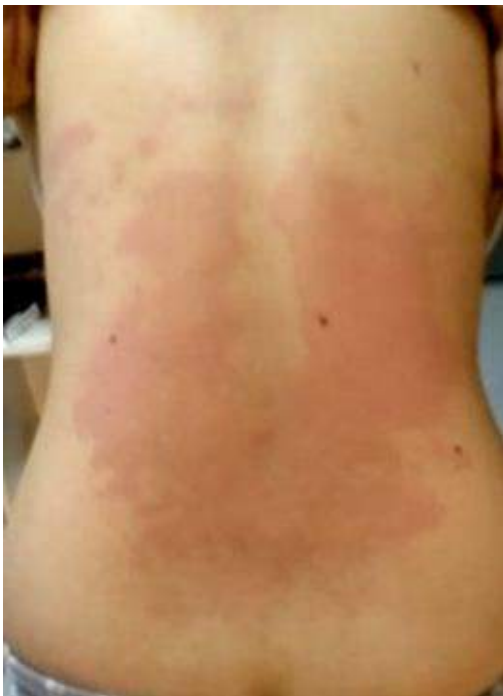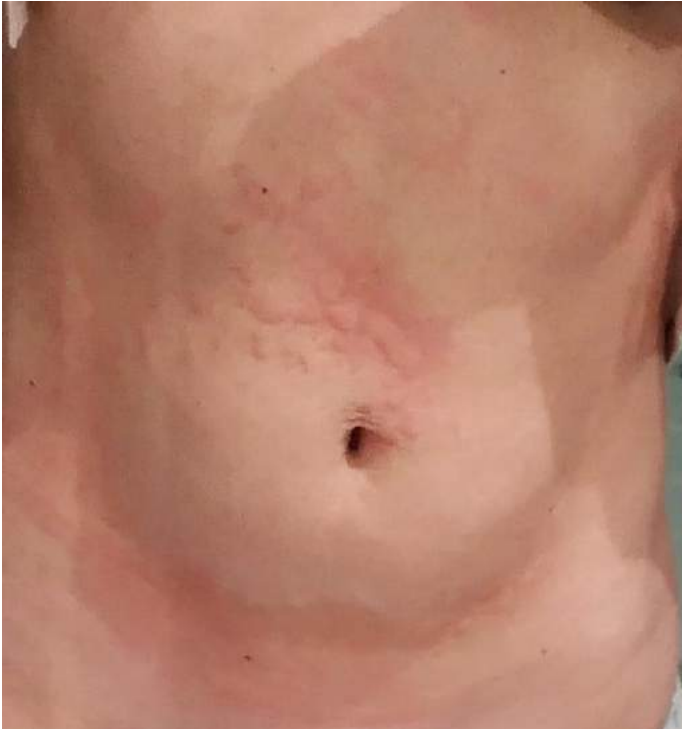Urticarial Eruption – Suspected cases



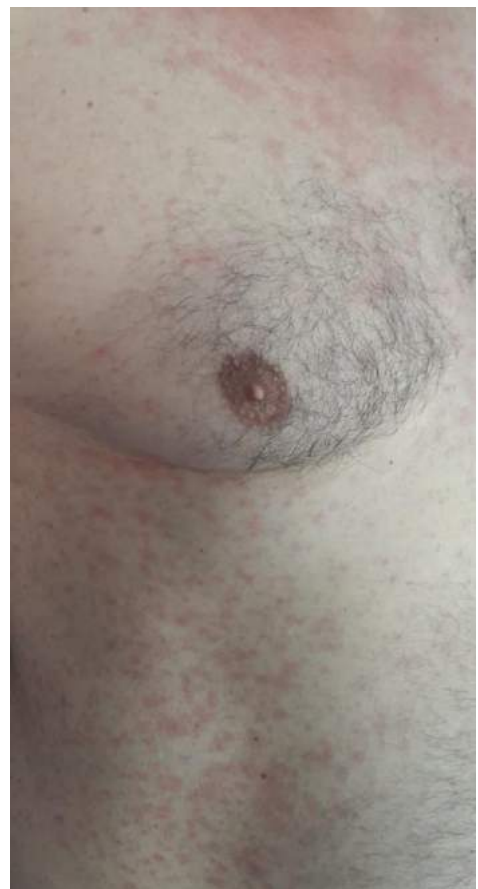
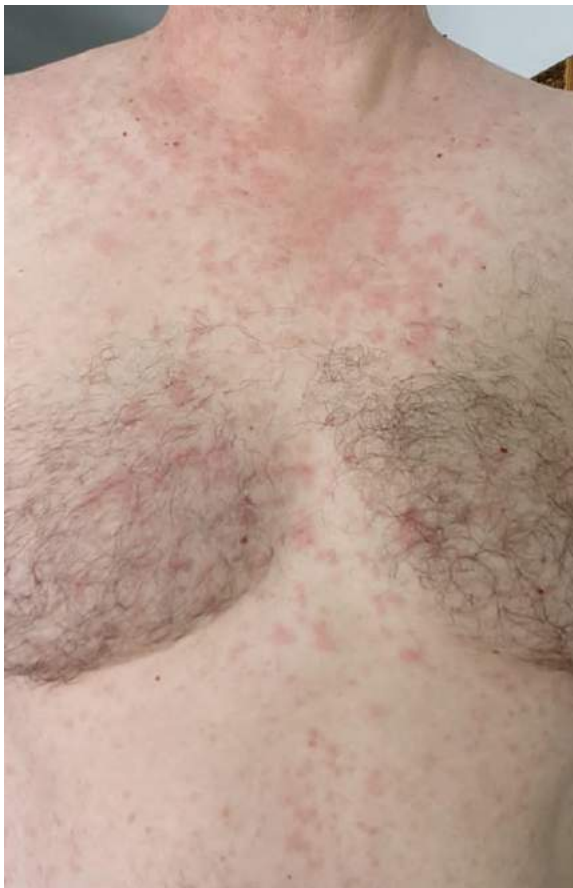
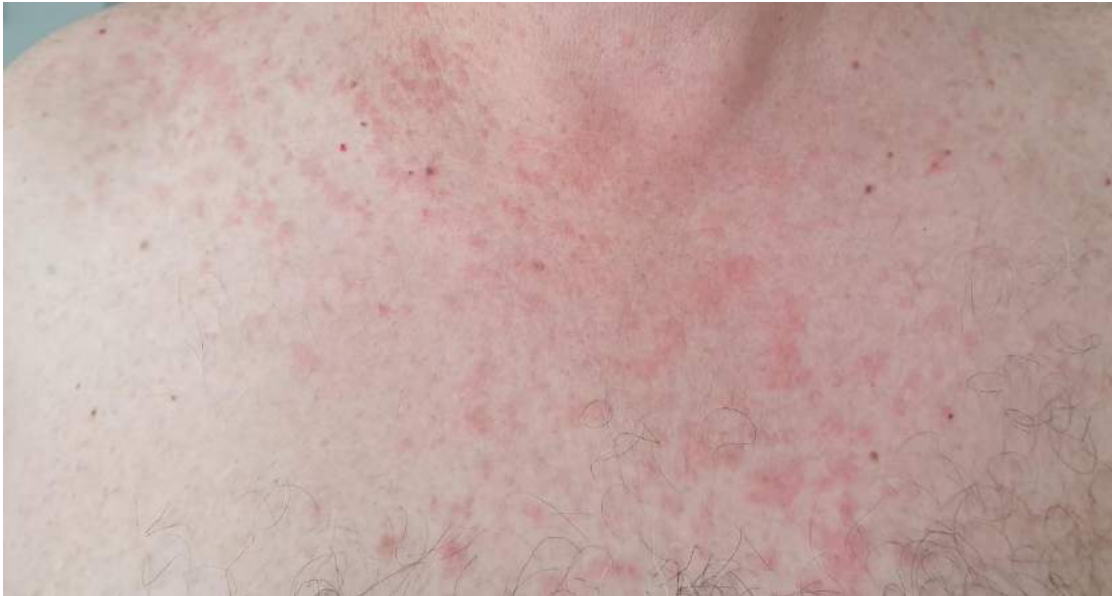
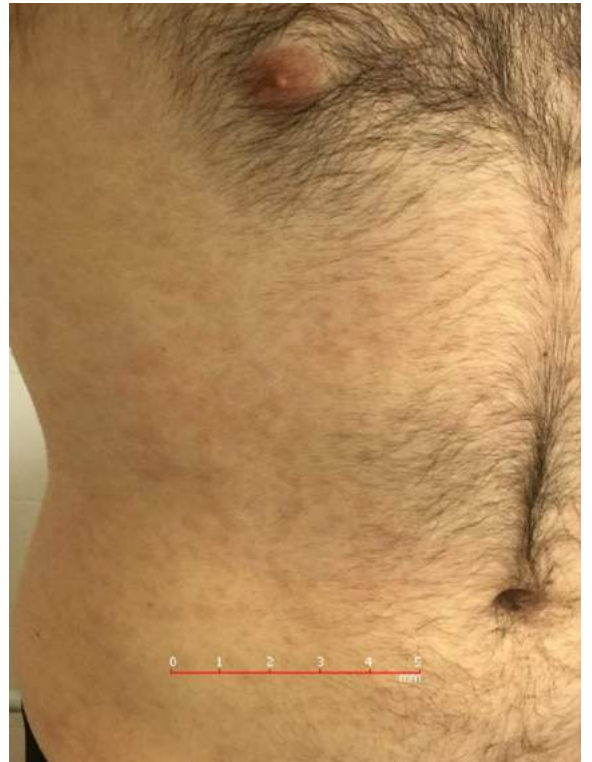


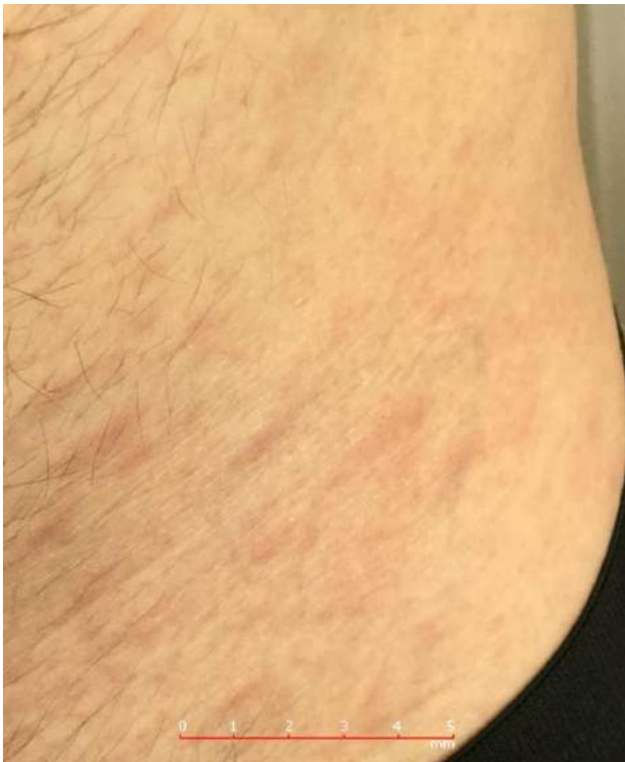
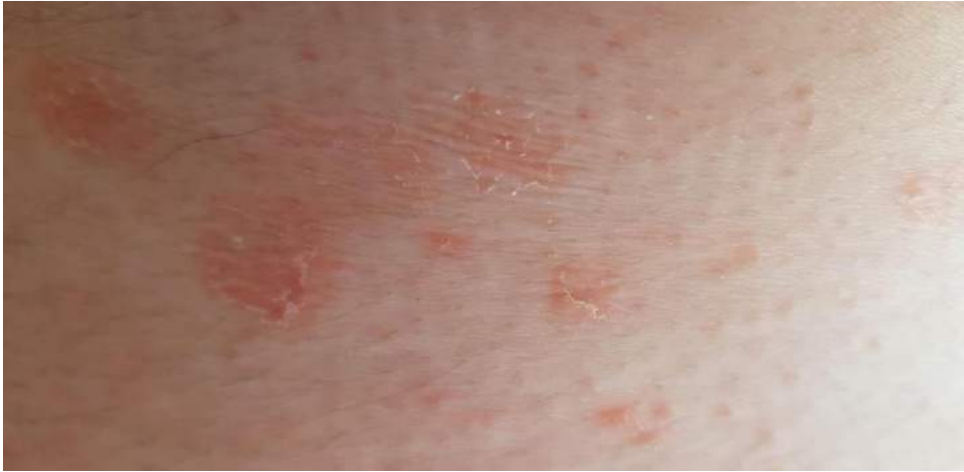
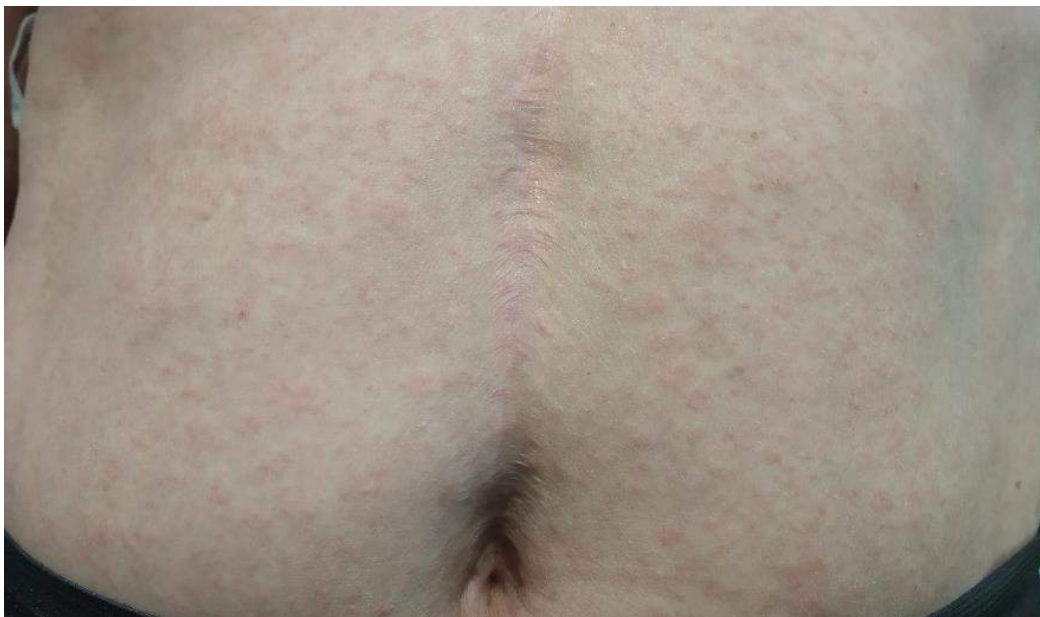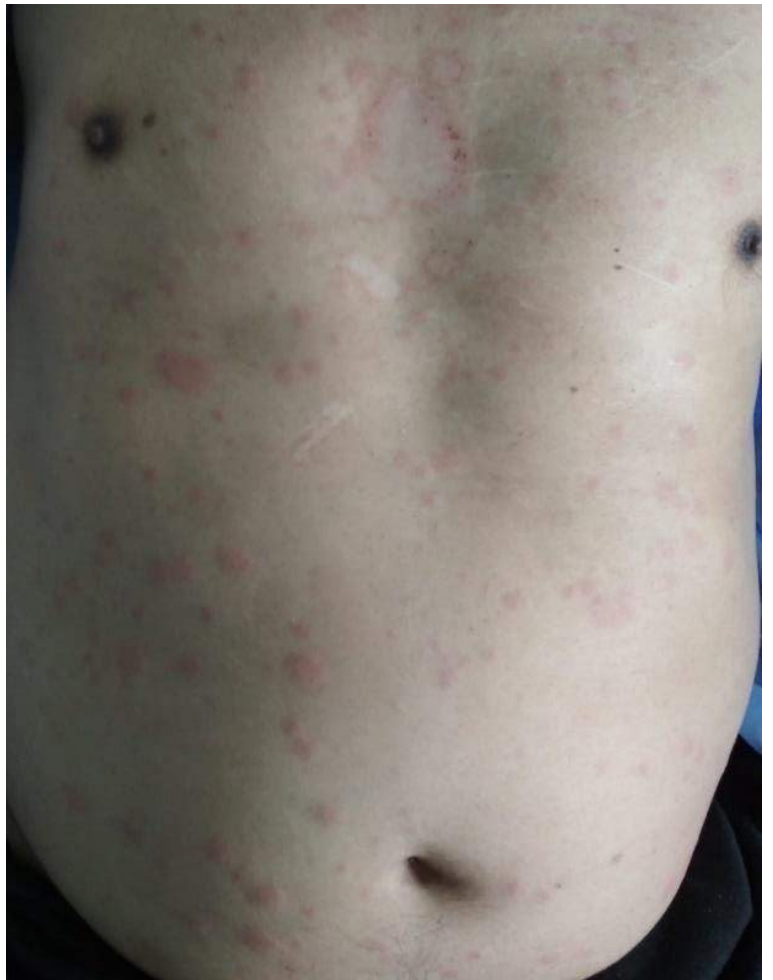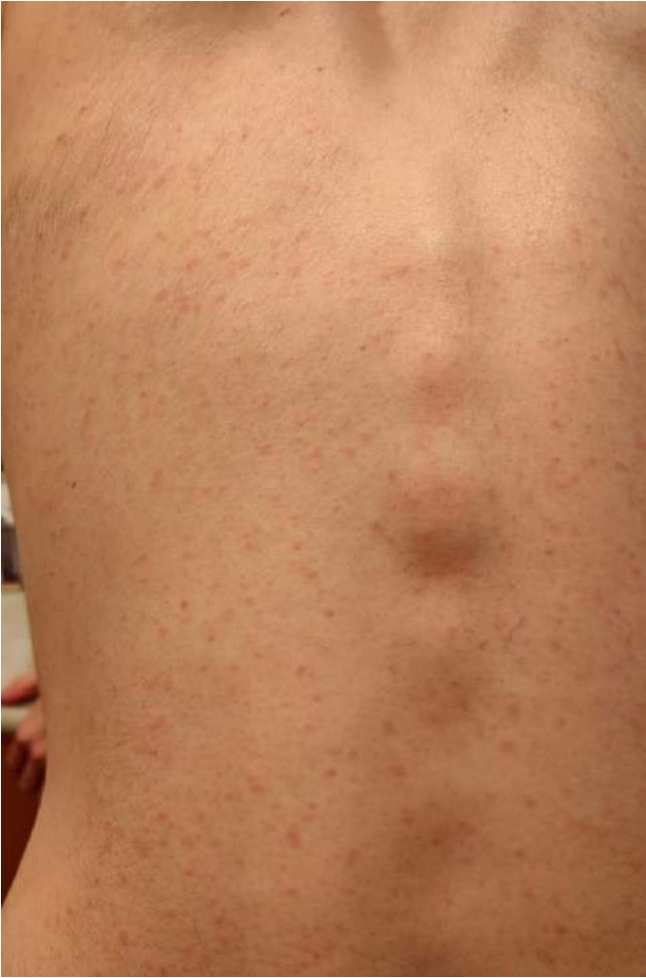Maculopapular eruption – Confirmed cases

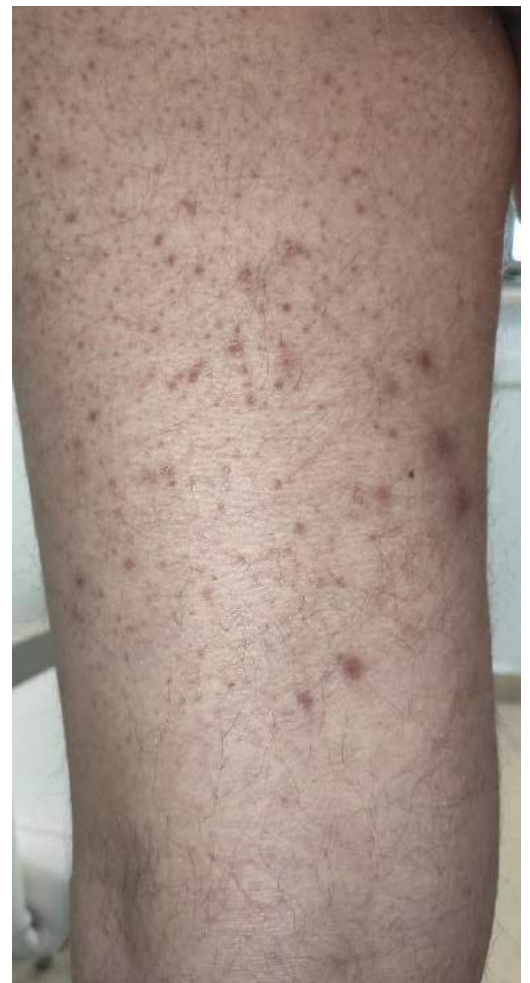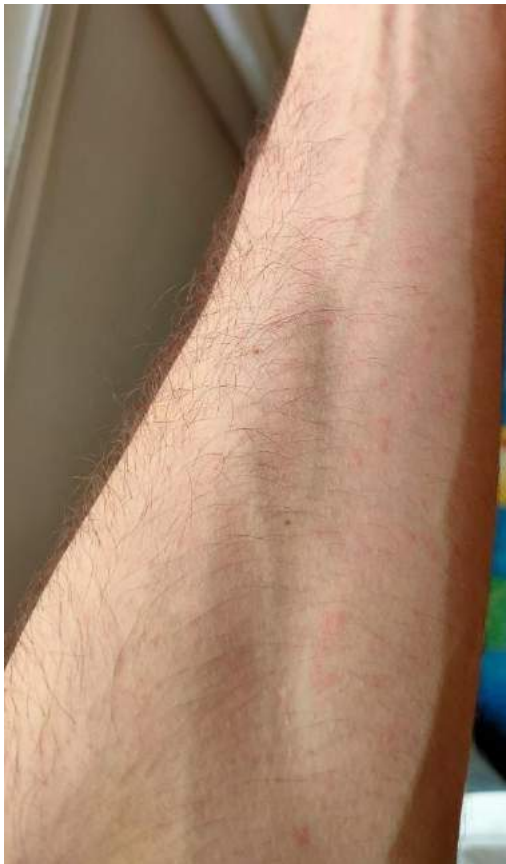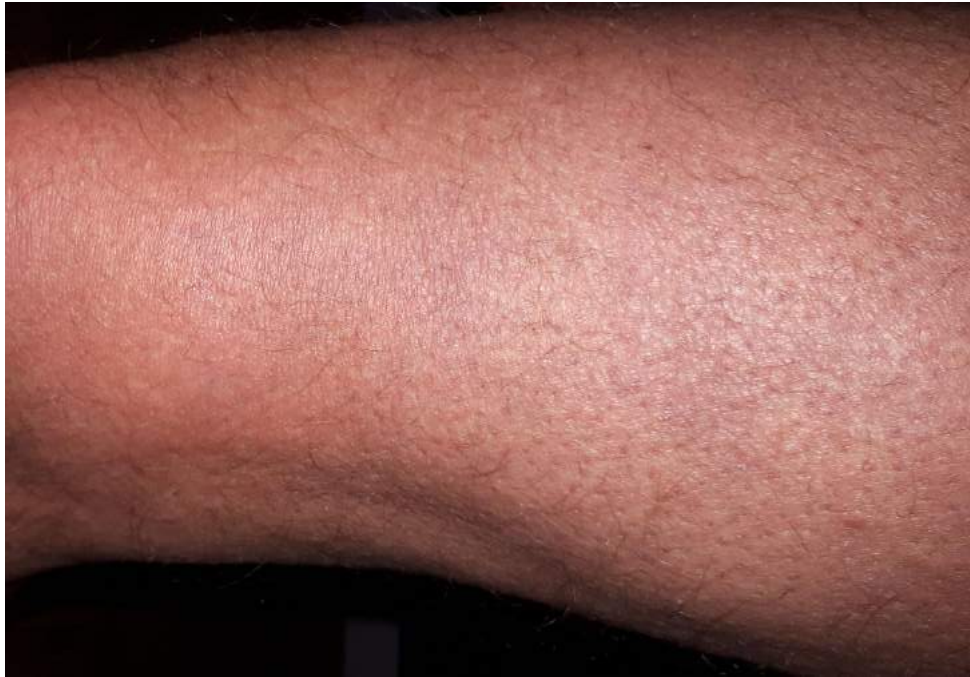Pityriasis rosea-like

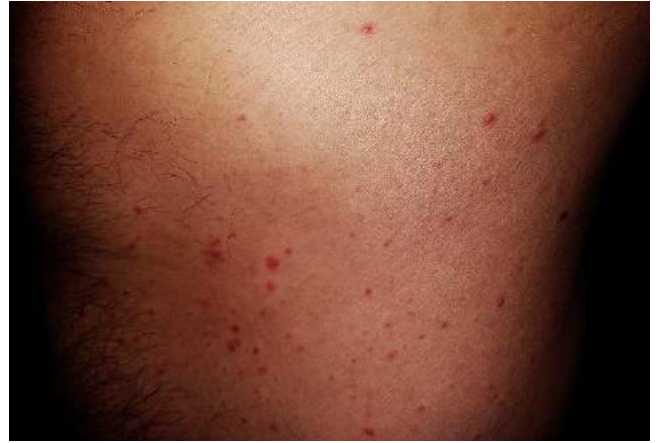
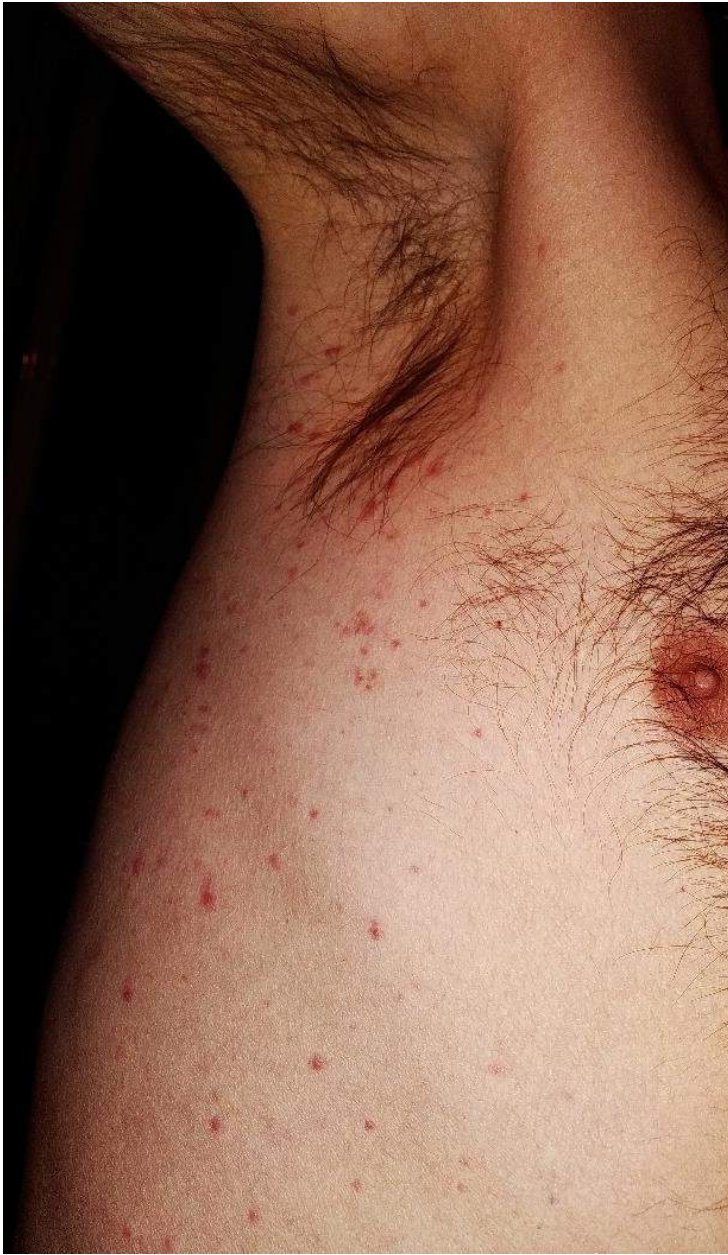




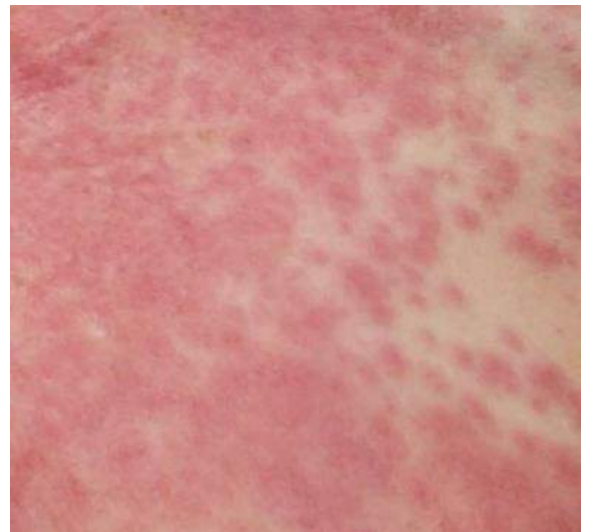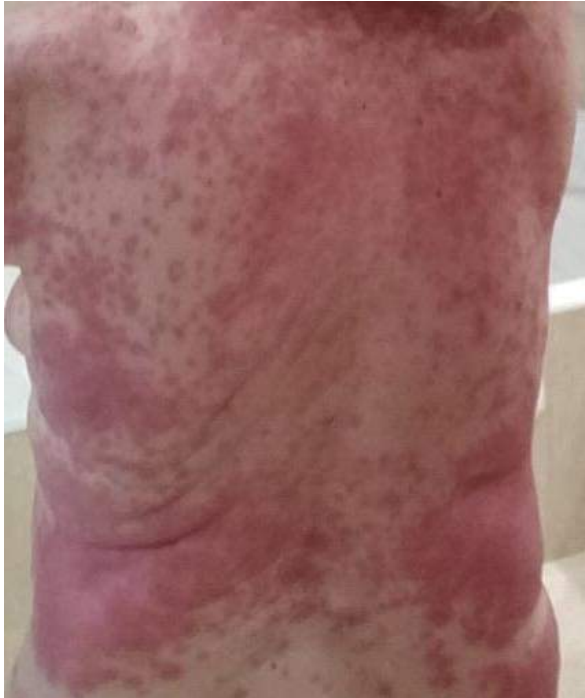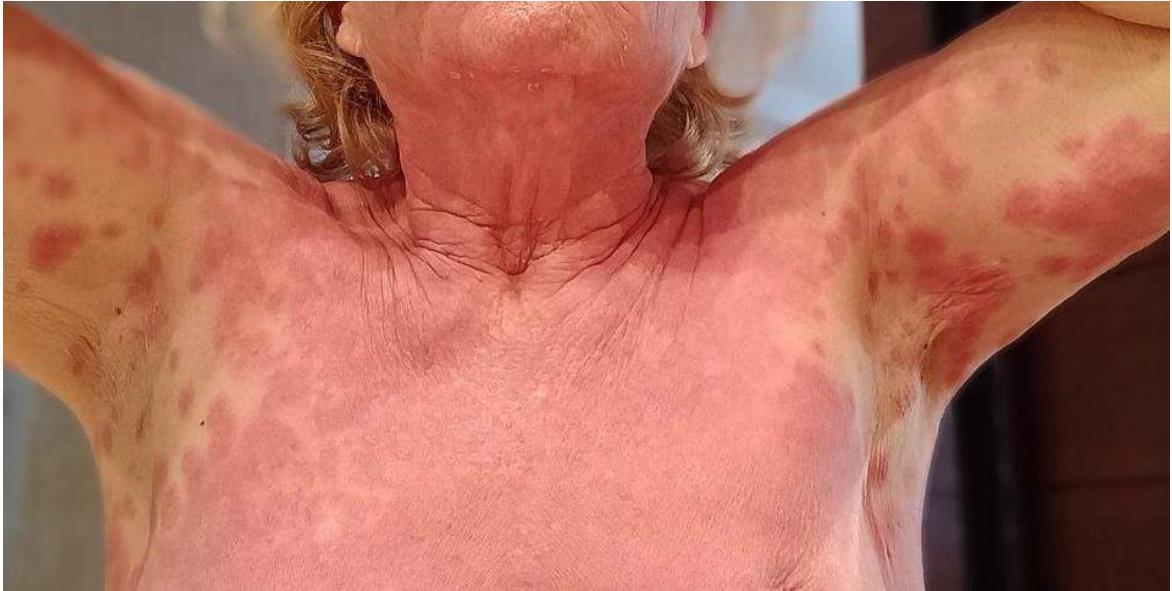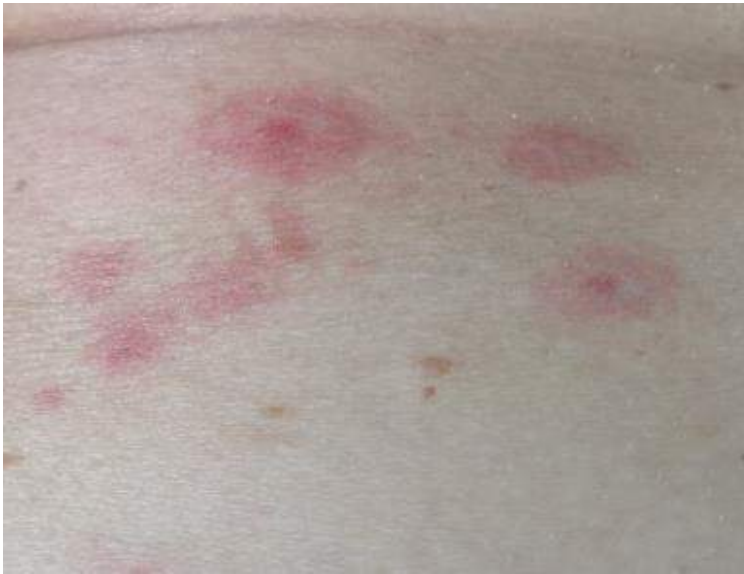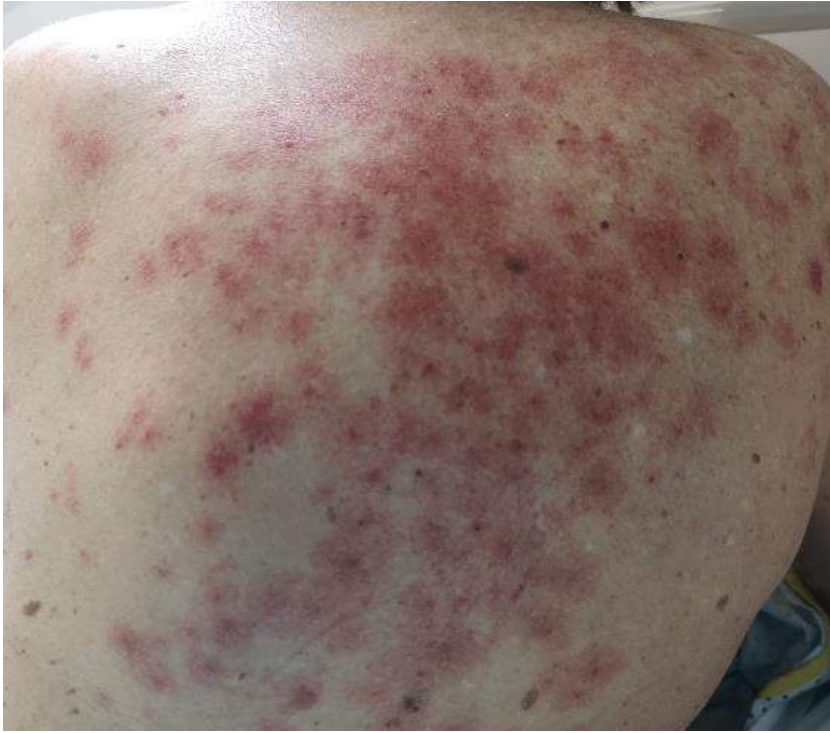Perifollicular eruption



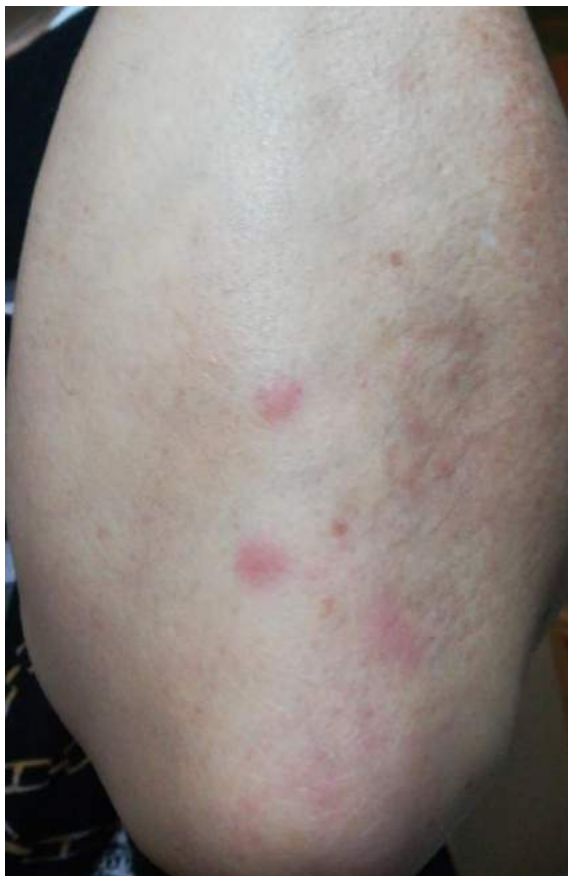
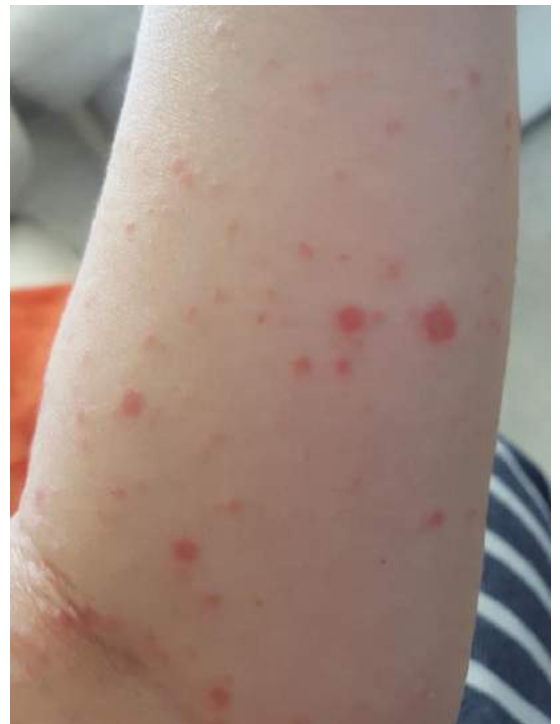
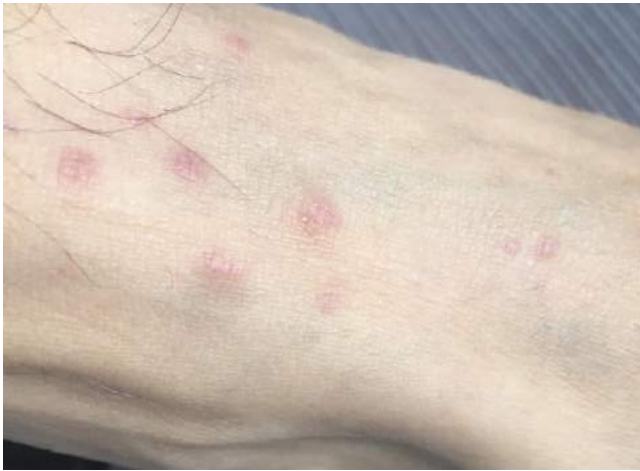Erythema multiforme-like

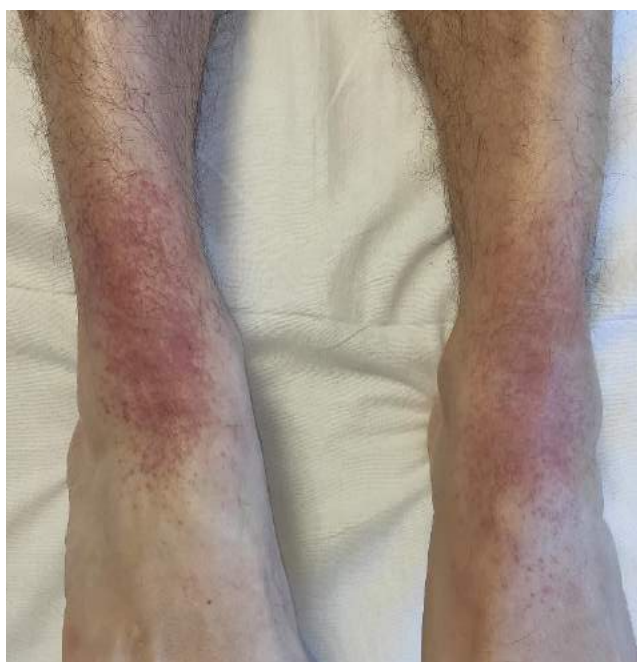
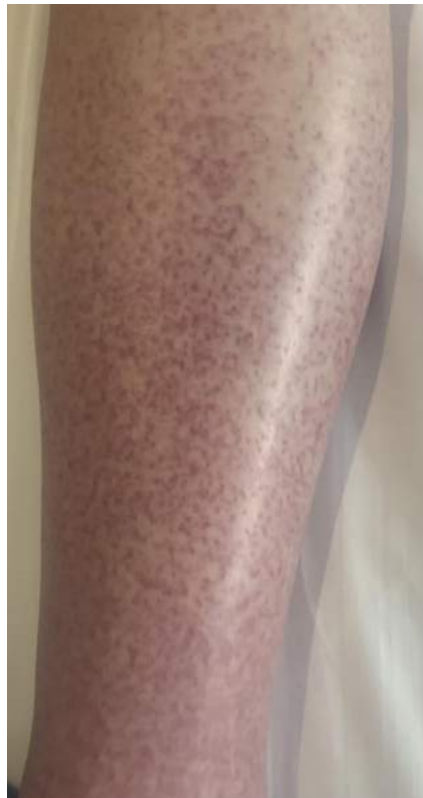
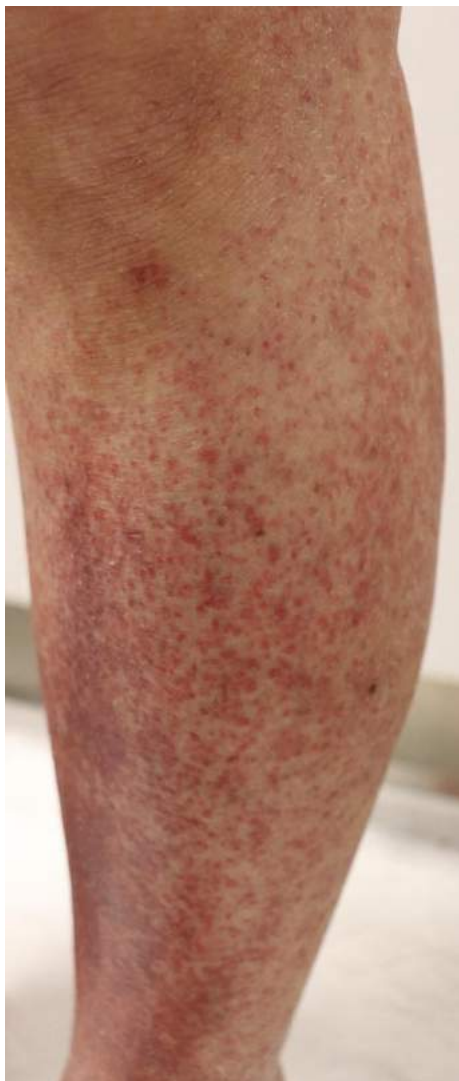

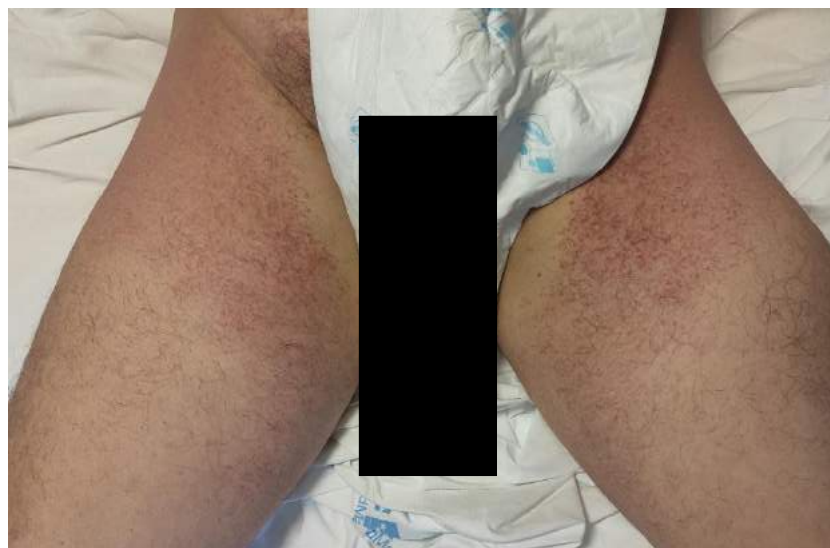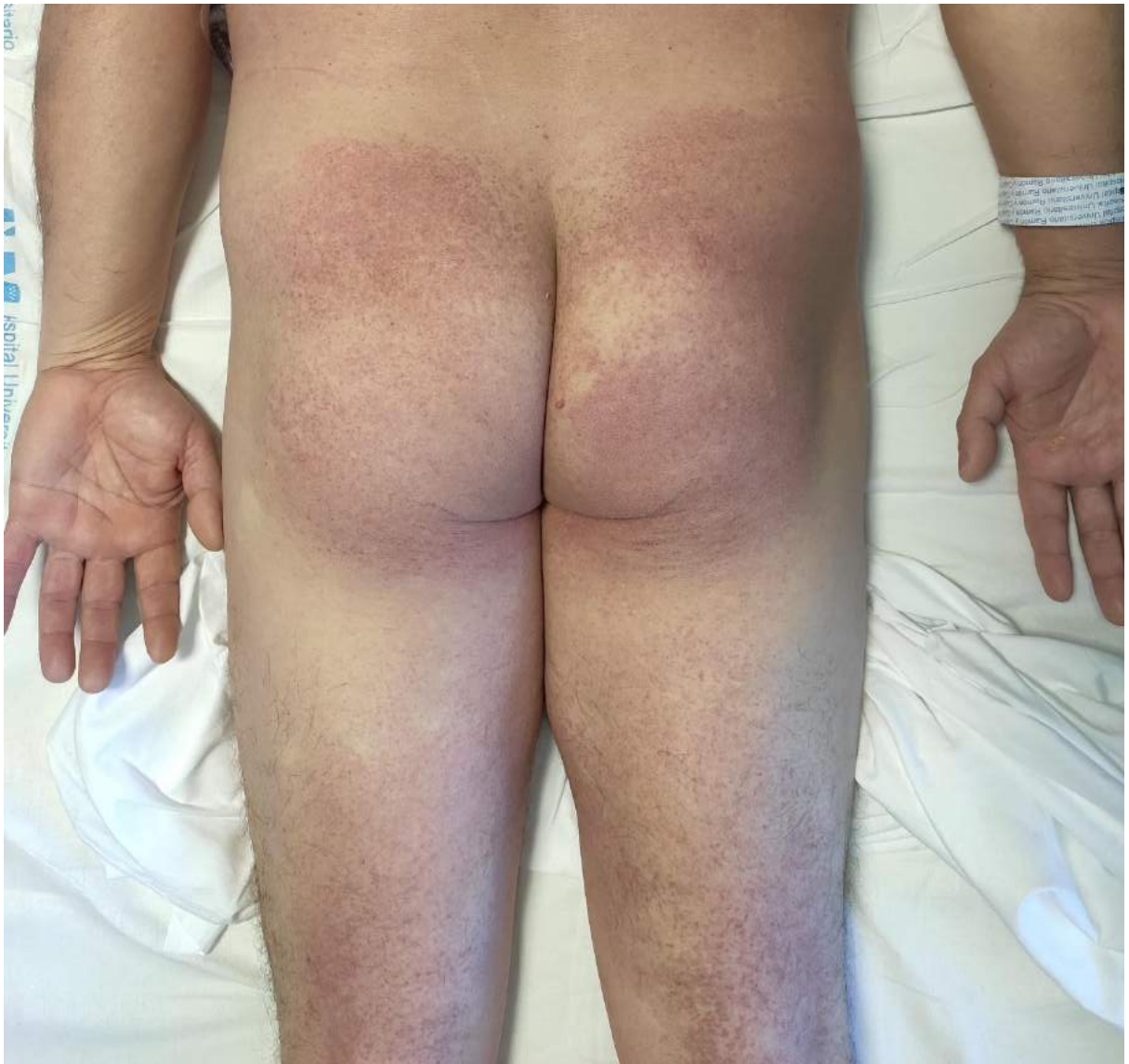Pseudovesicular or resembling erythema elevatum diutinum

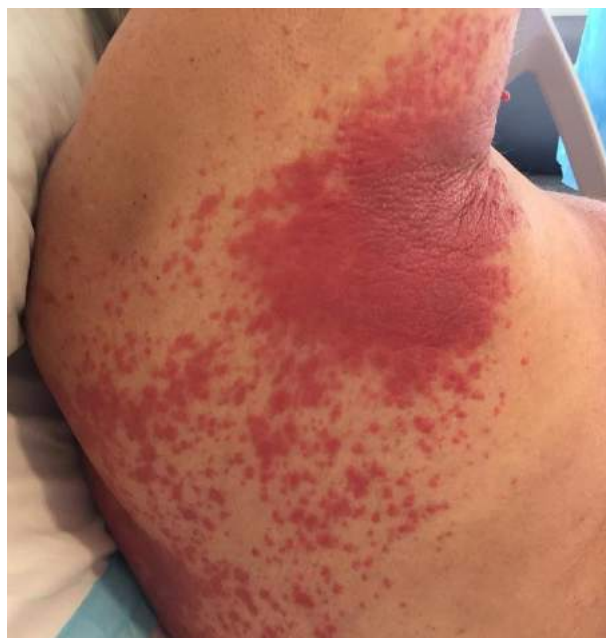
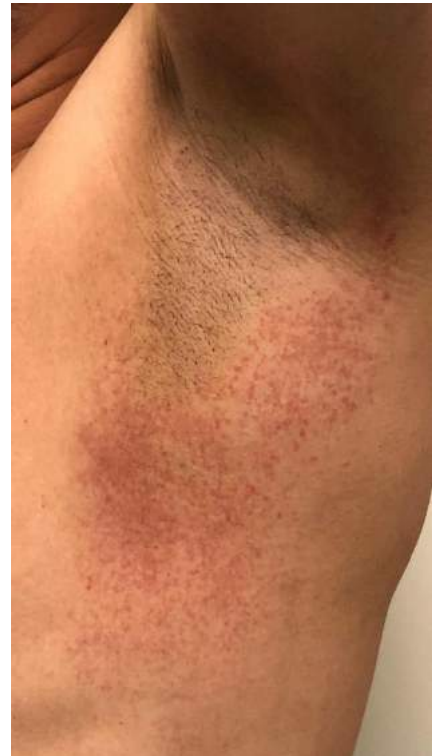
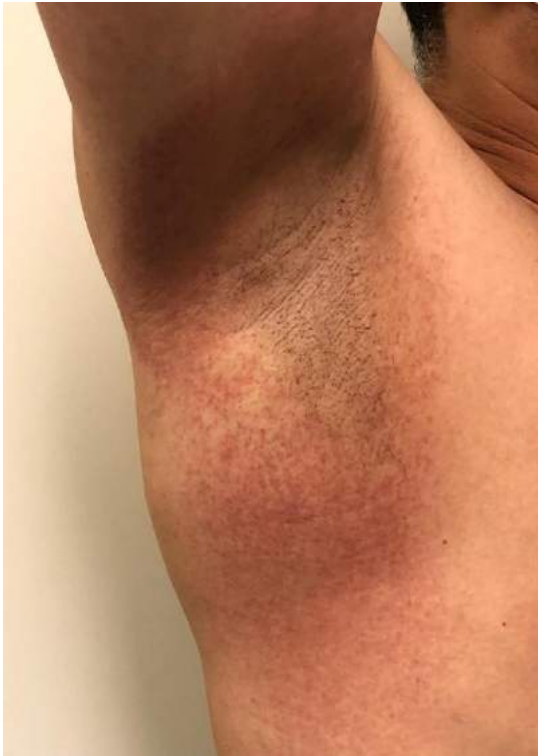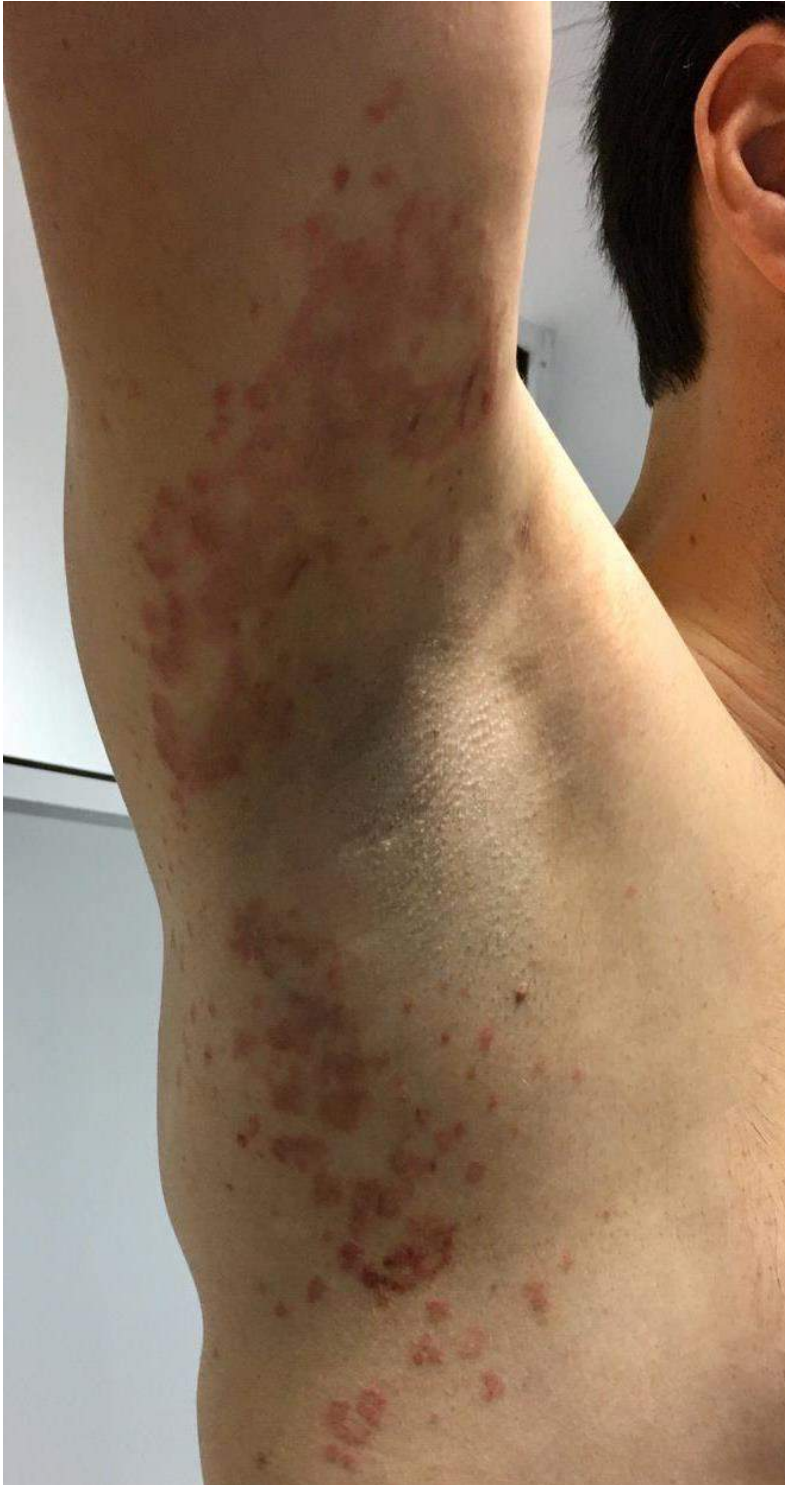Purpuric eruptions



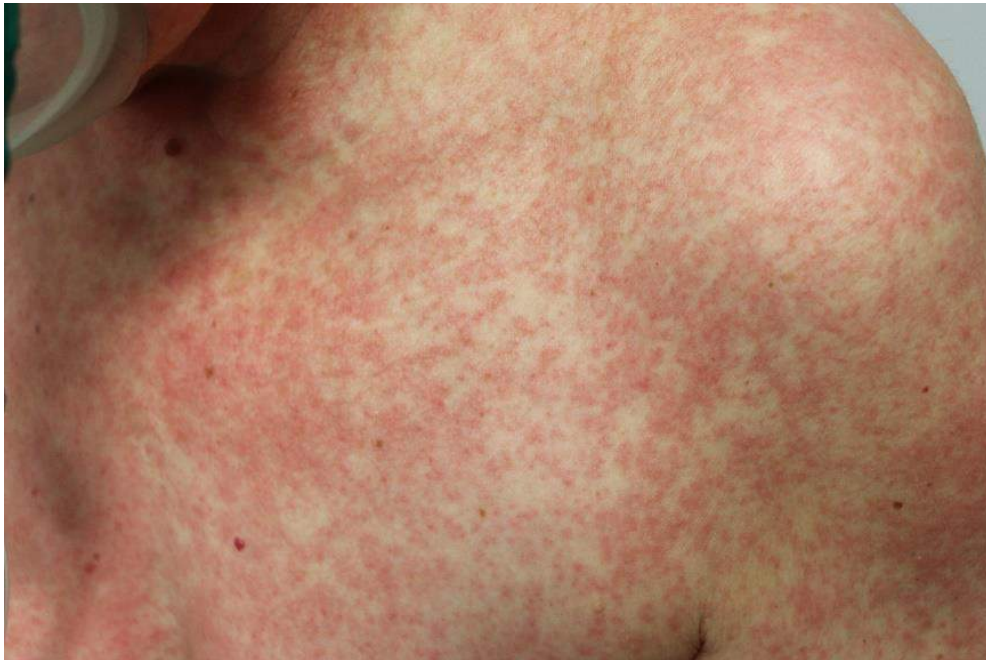
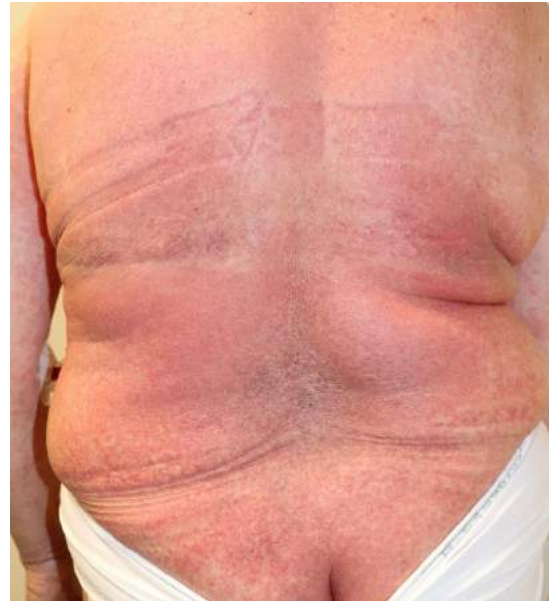
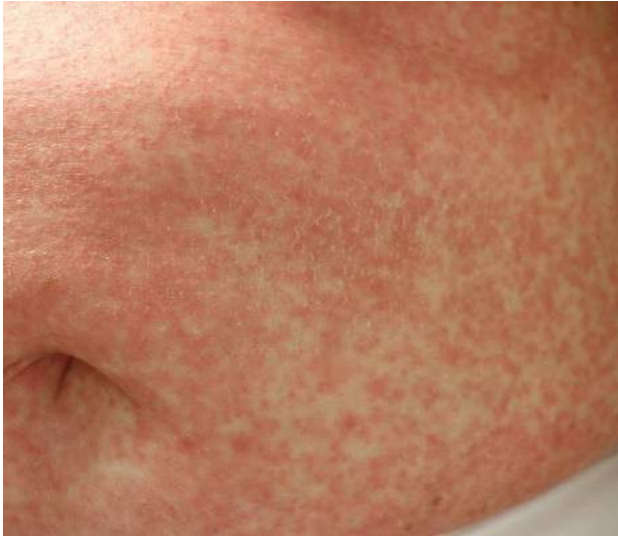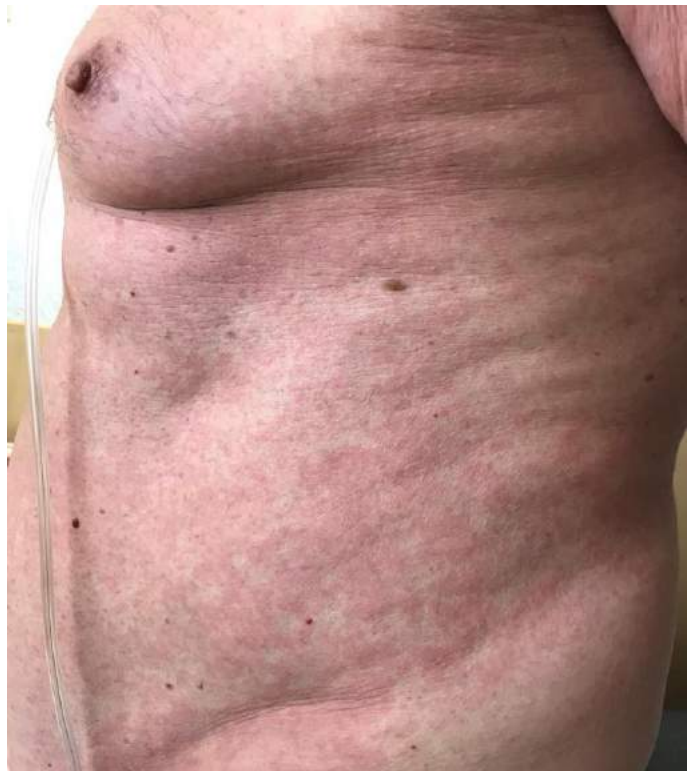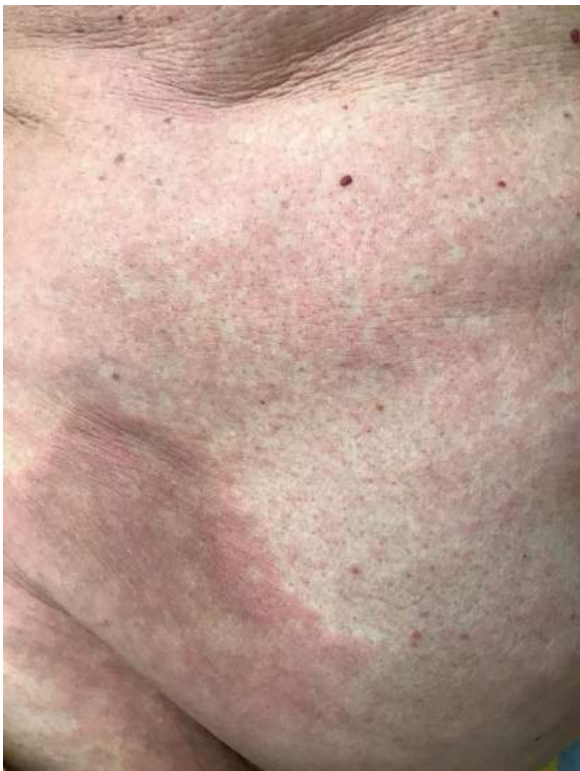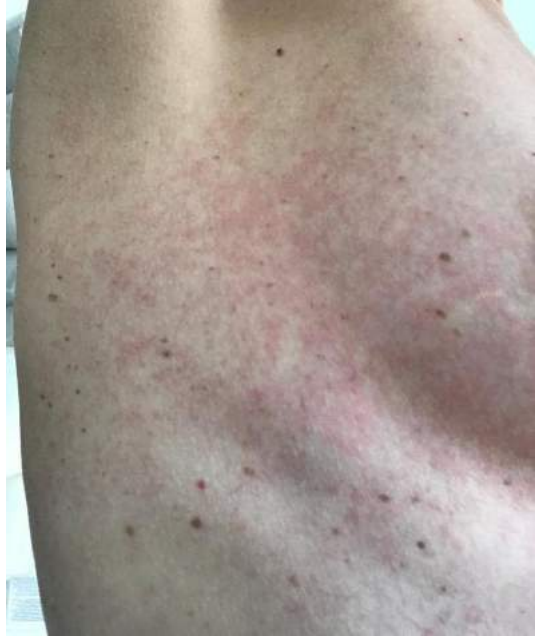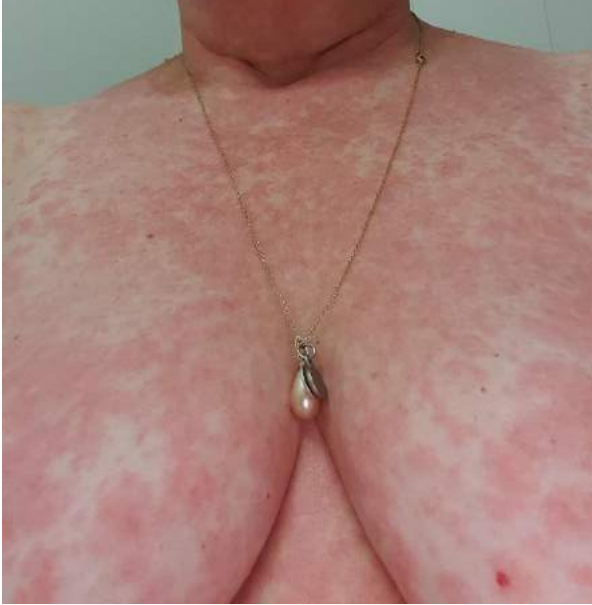Bilateral axillary purpuric eruption



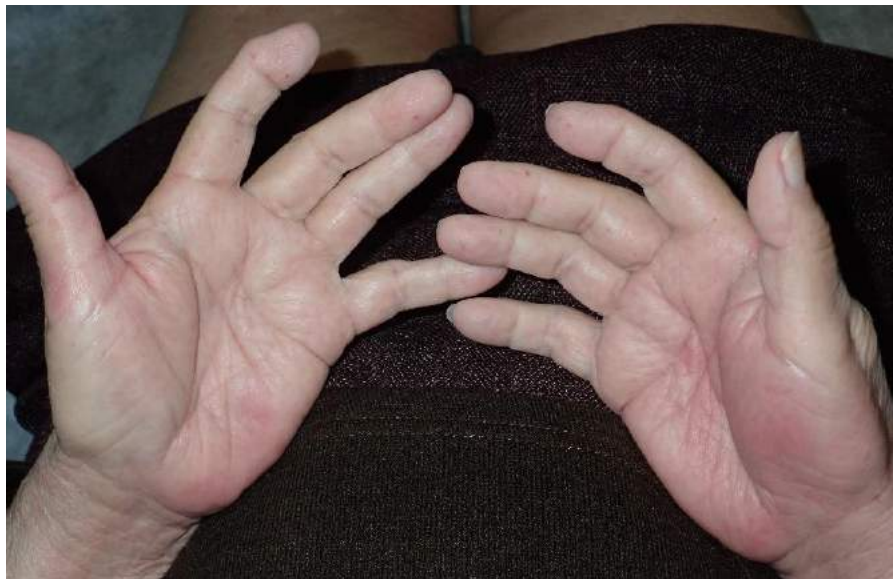
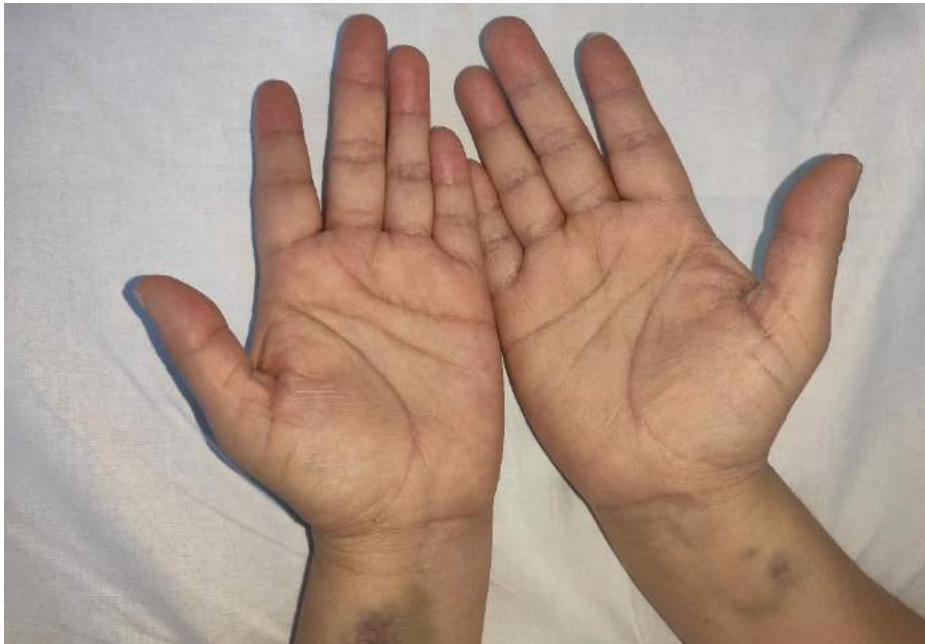
Morbilliform eruptions

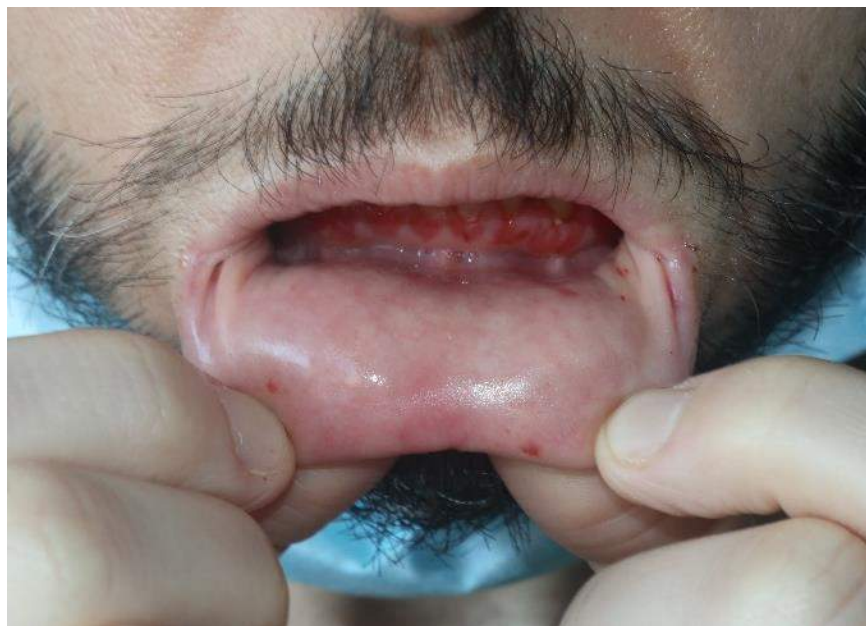
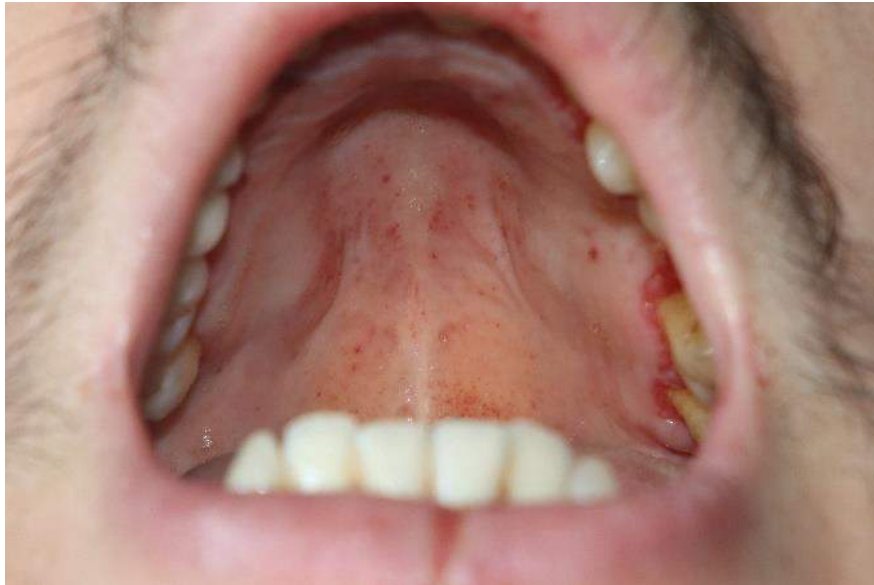


Palmar erythema

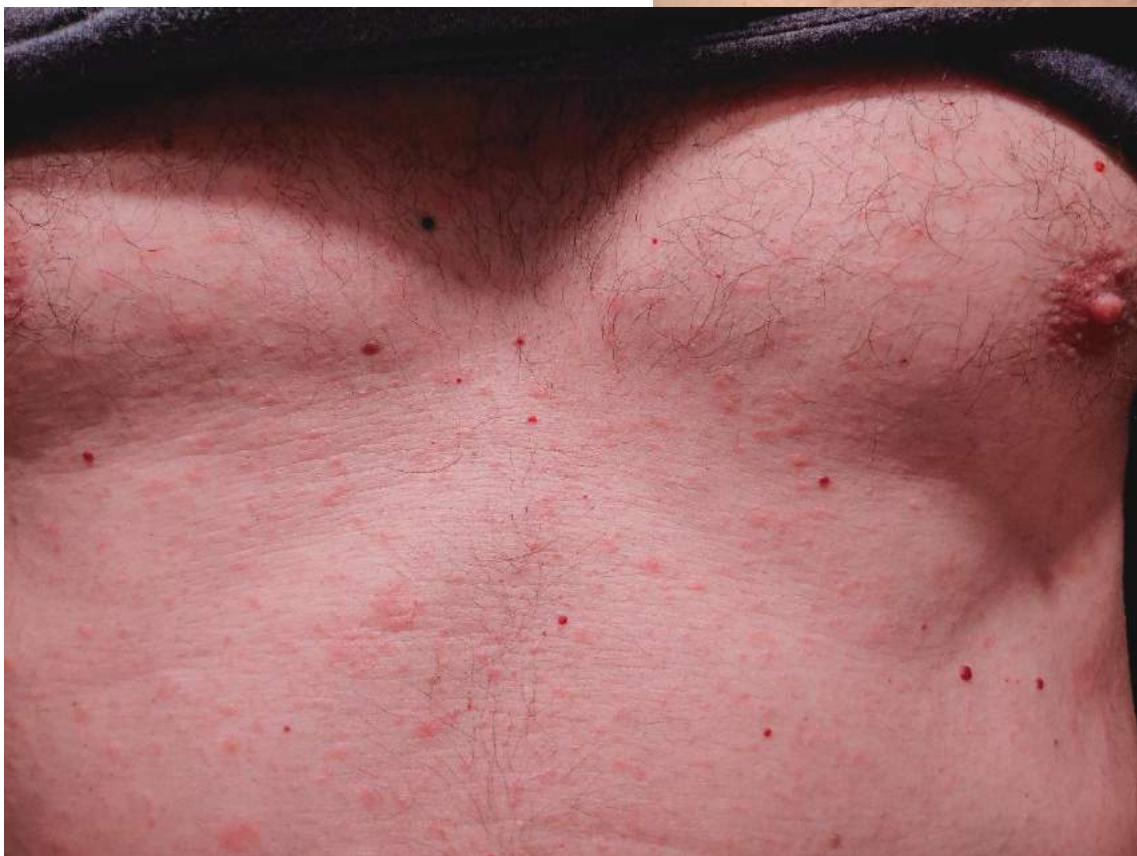
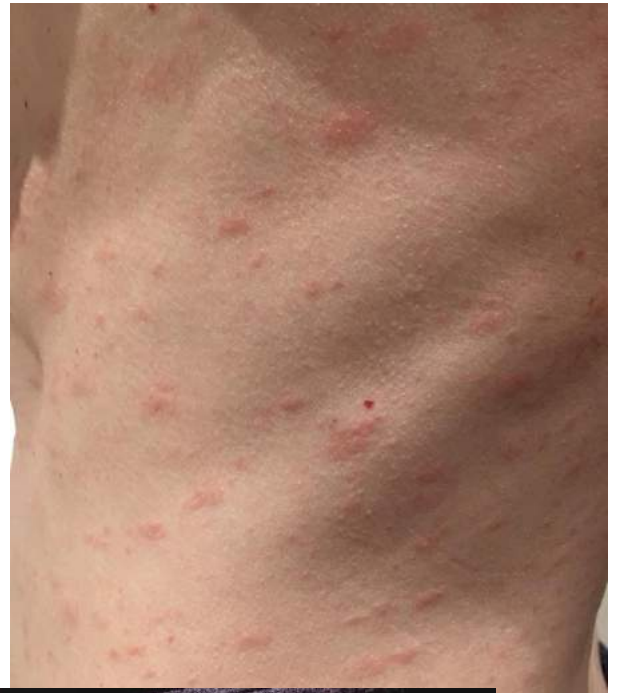
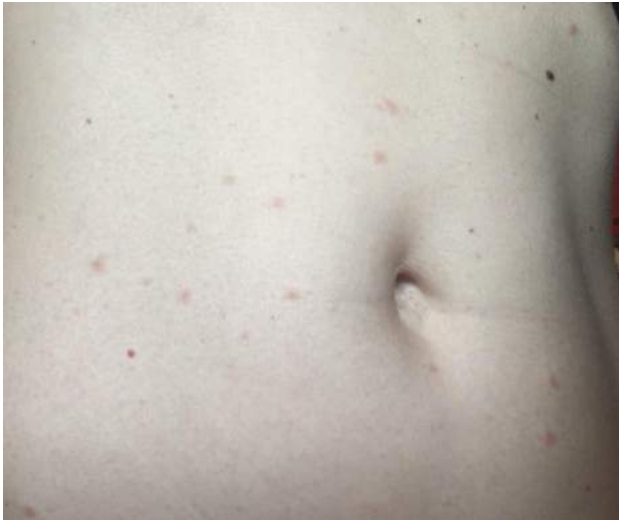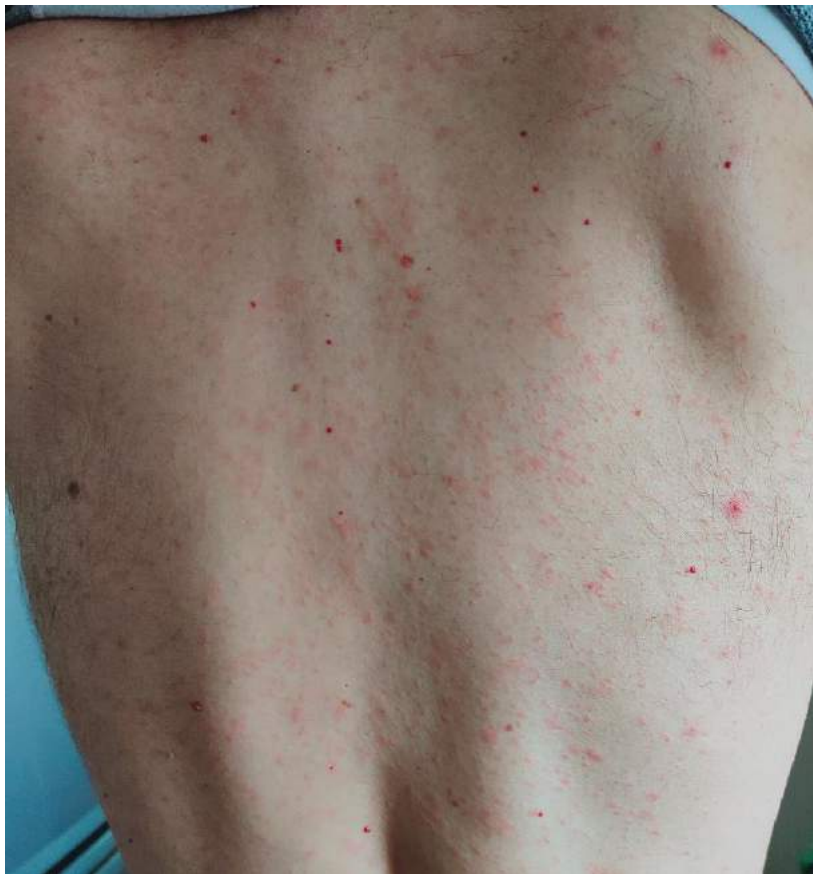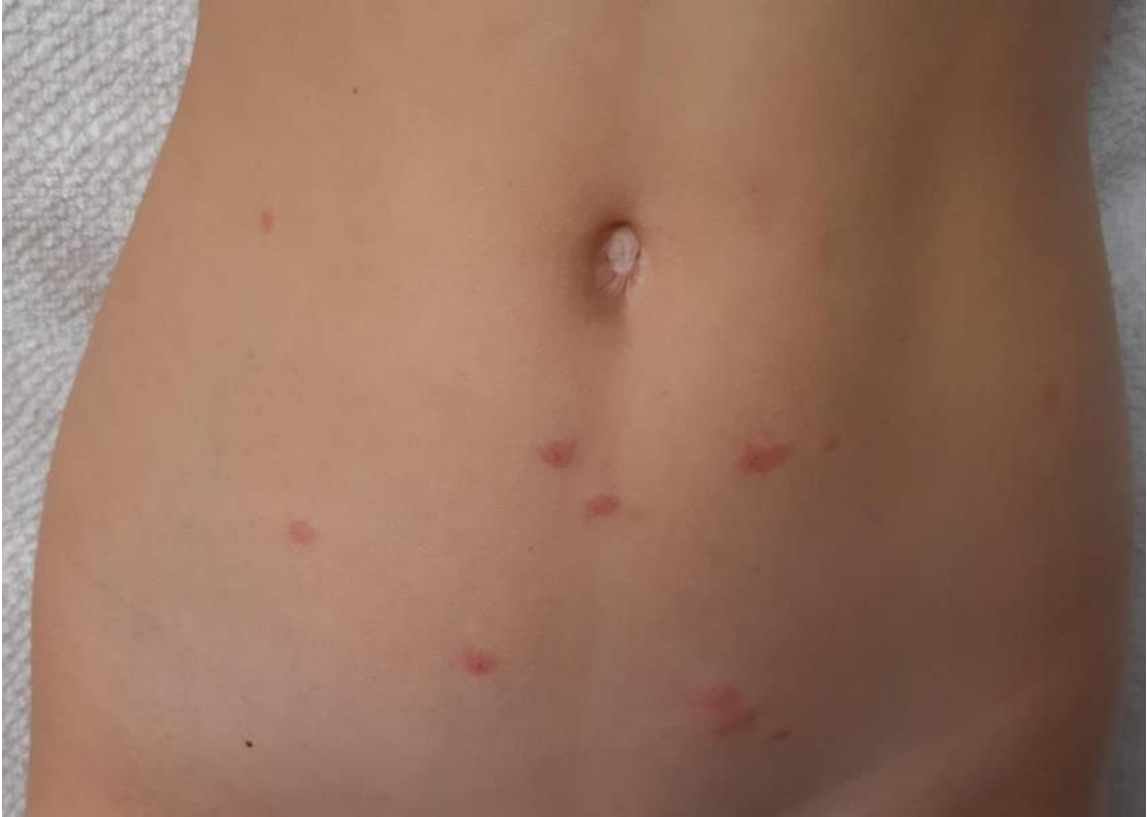Enanthem

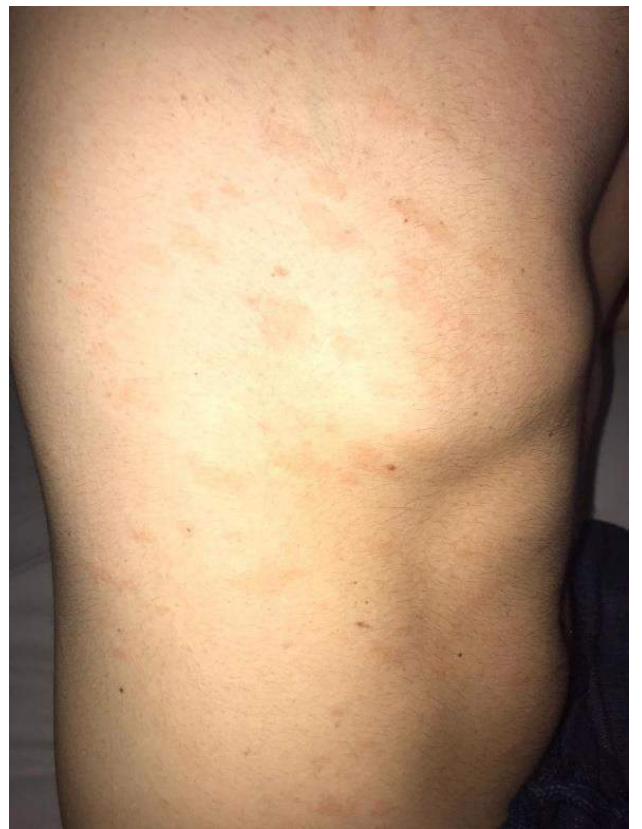
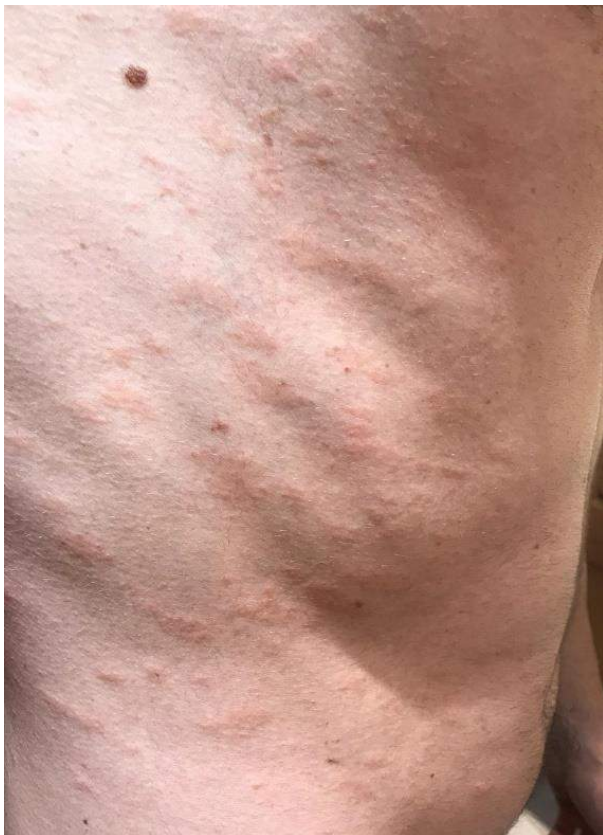
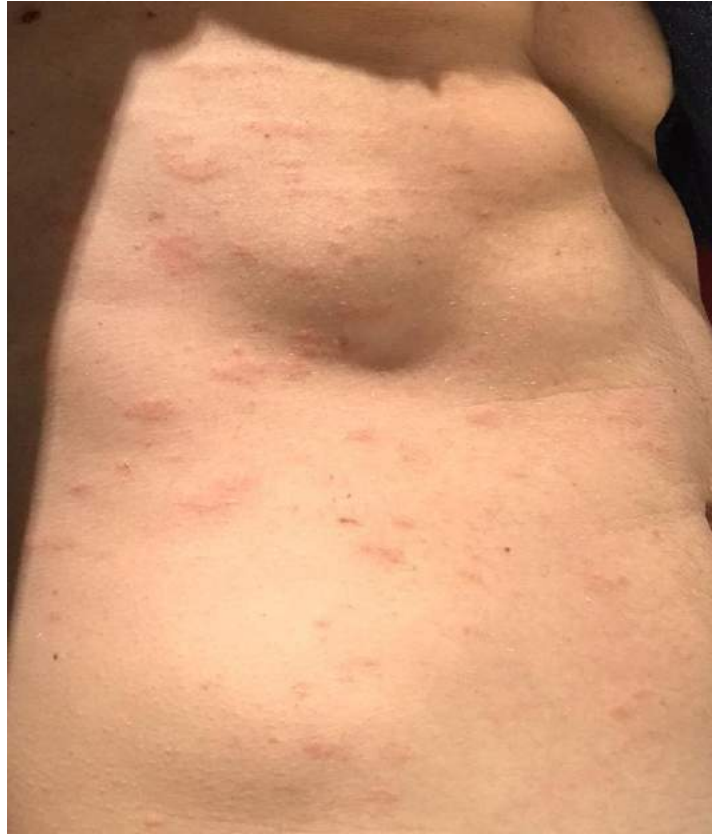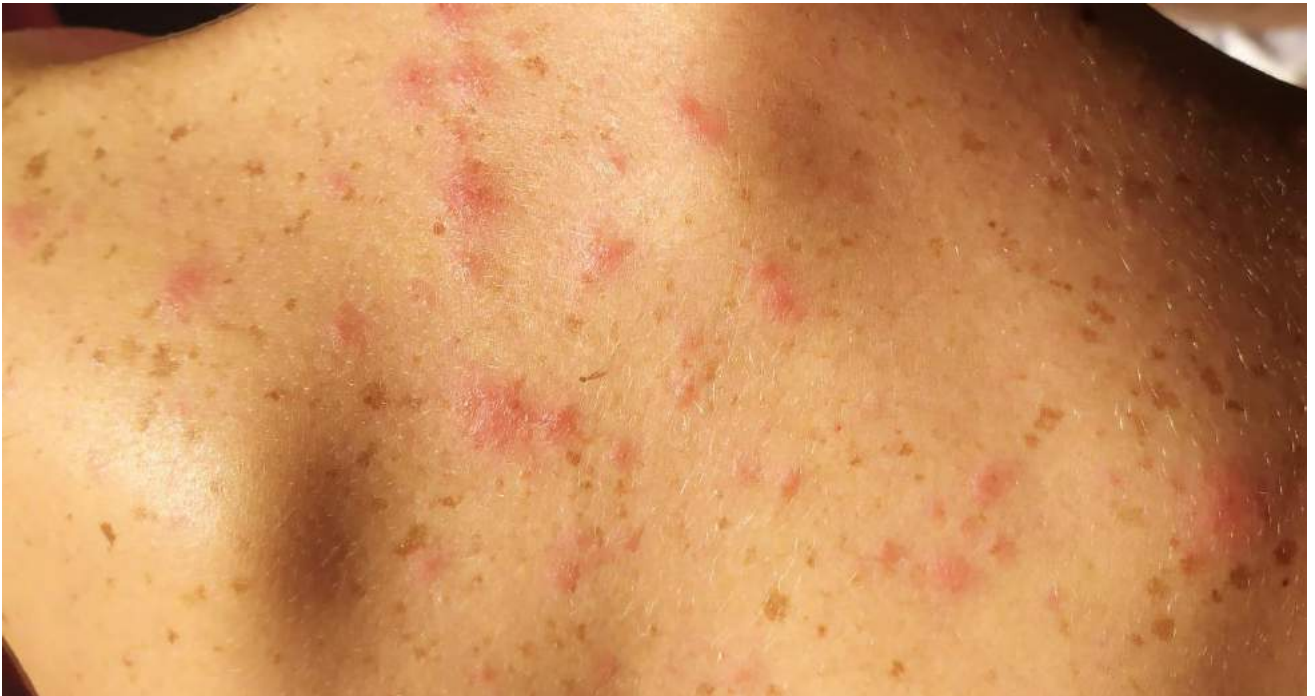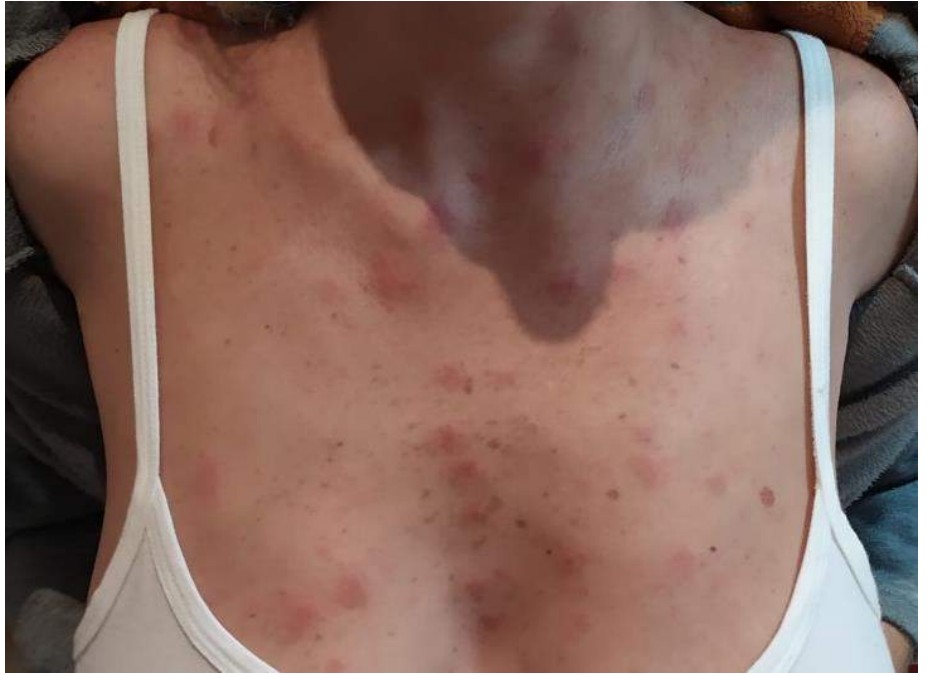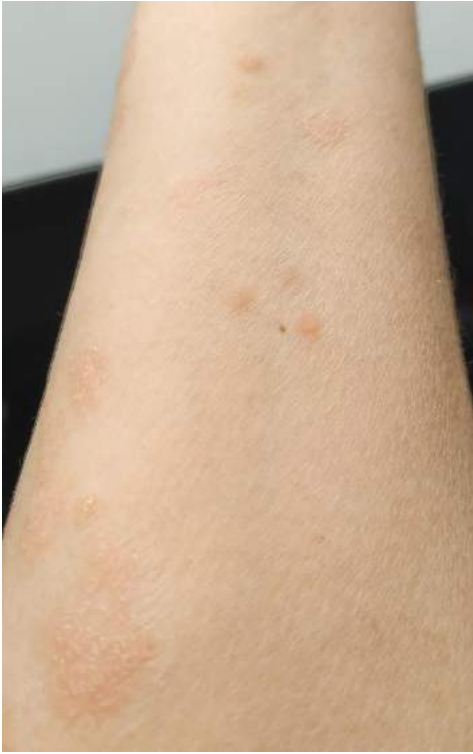Maculopapular eruption – Suspected cases

Pytirisias rosea-like

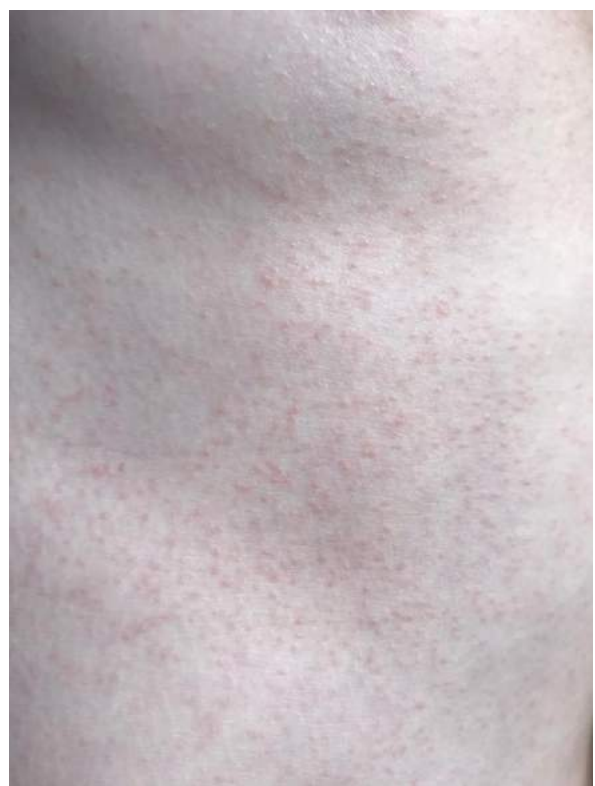
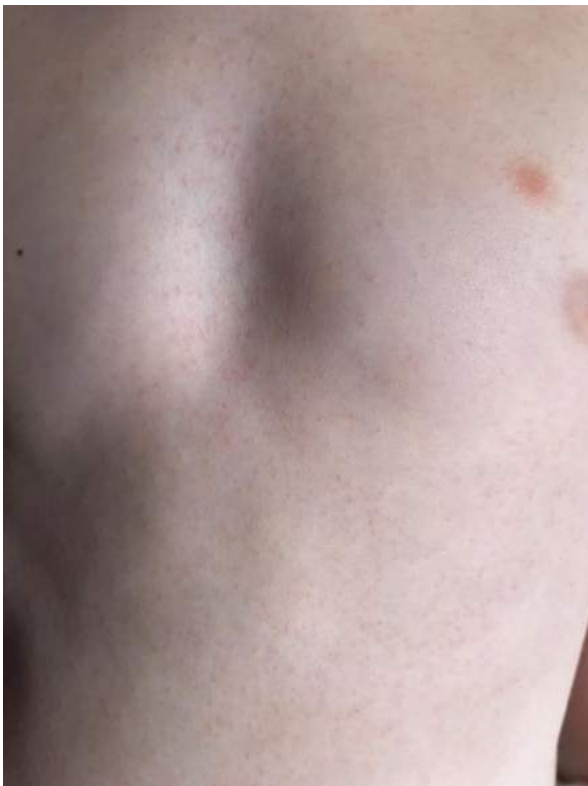
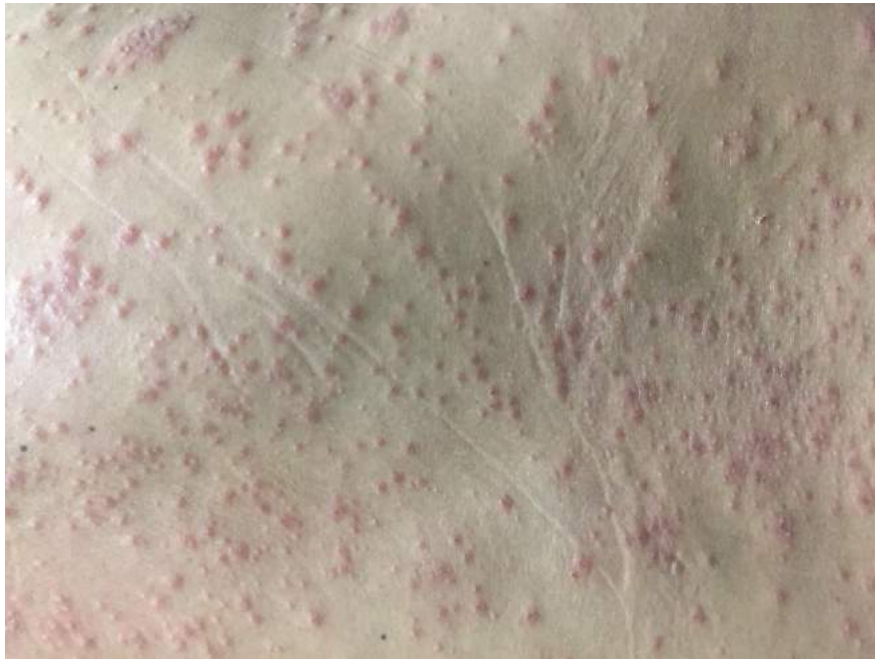


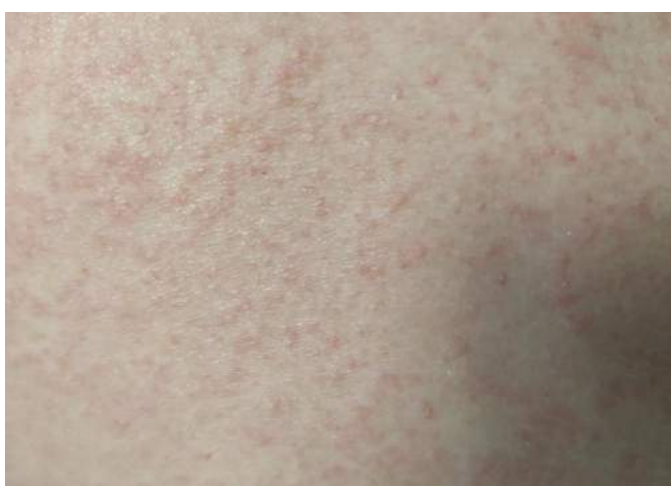
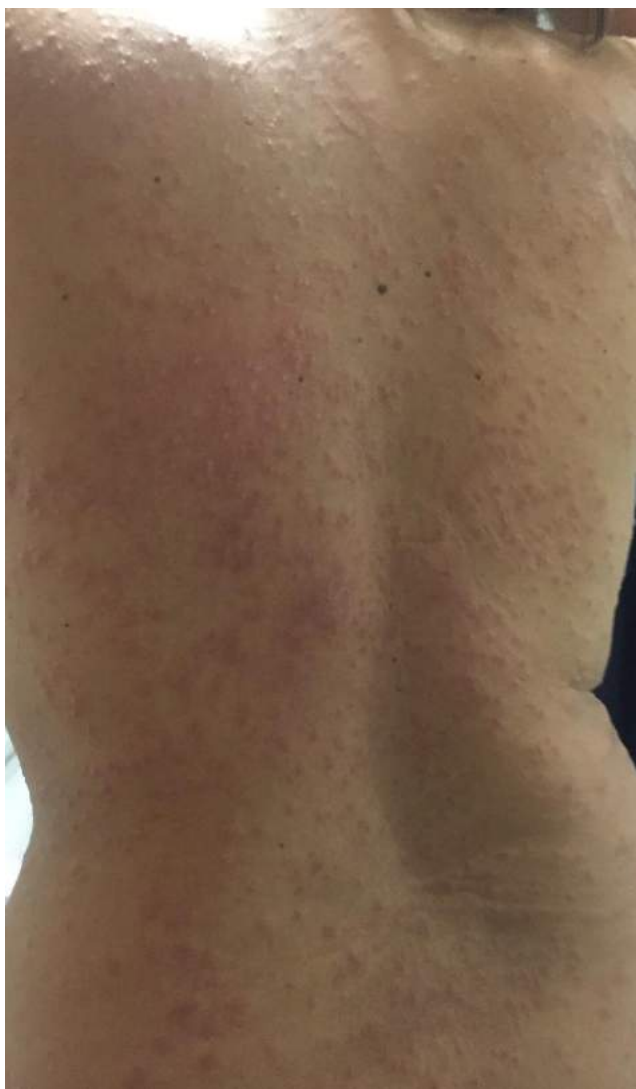

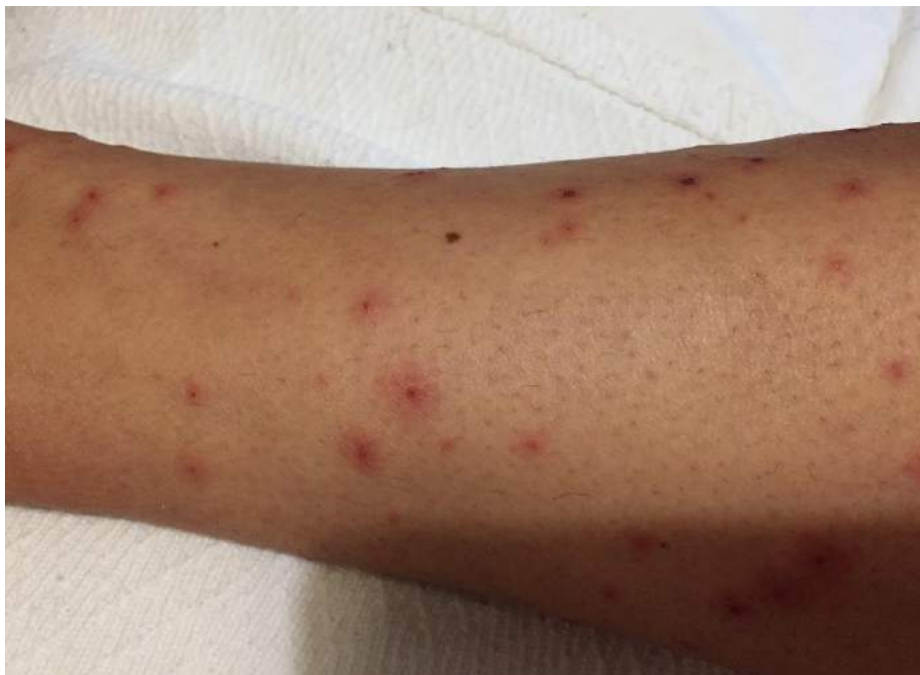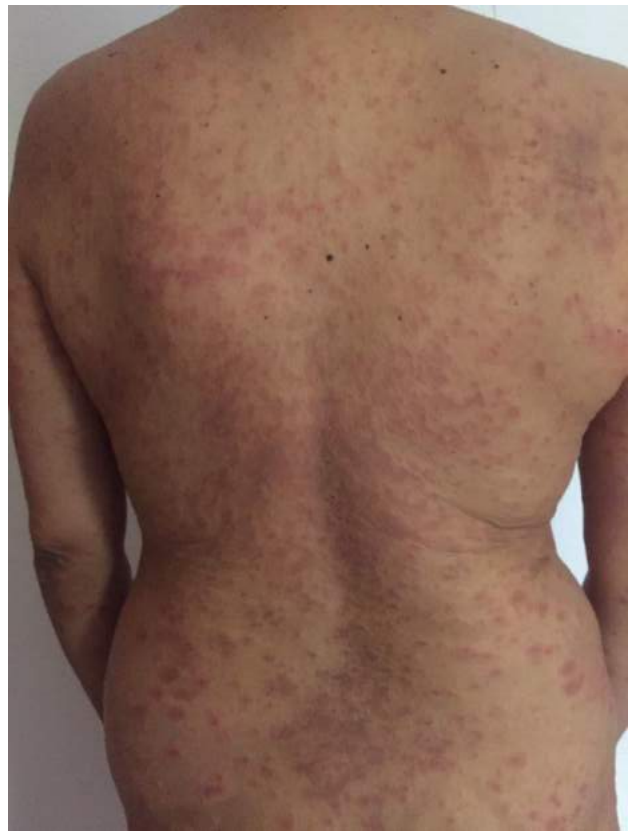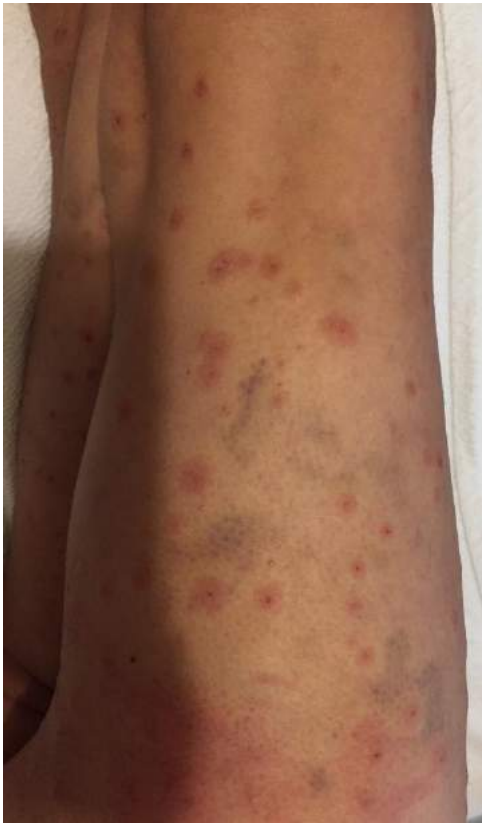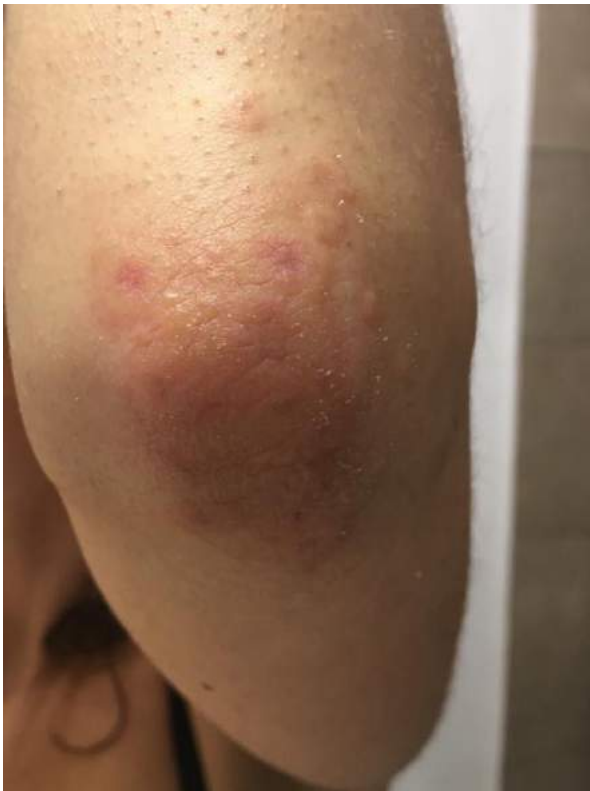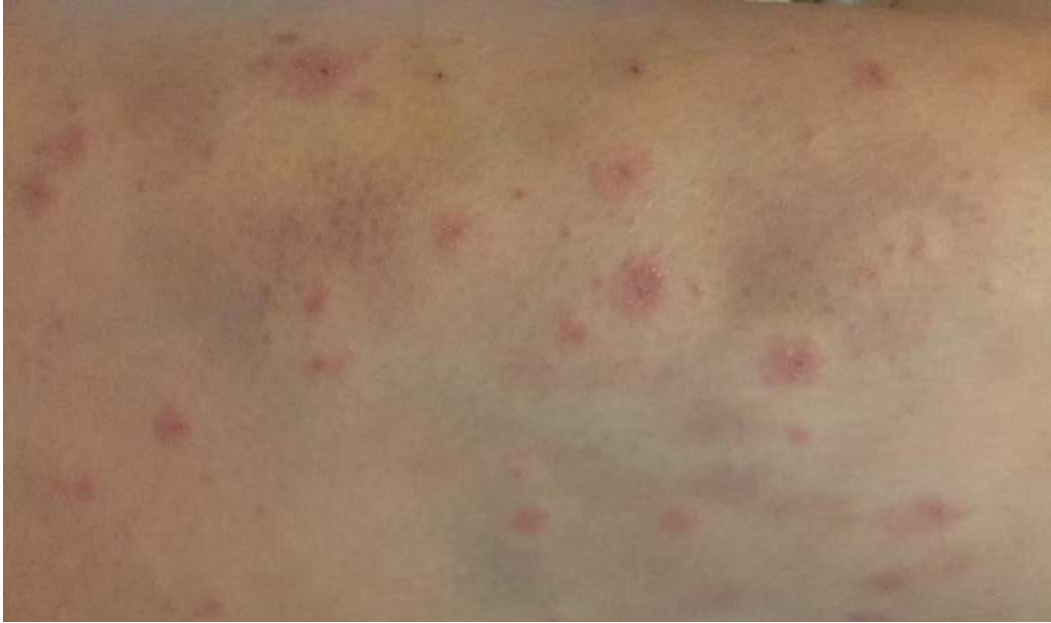Perifollicular eruption

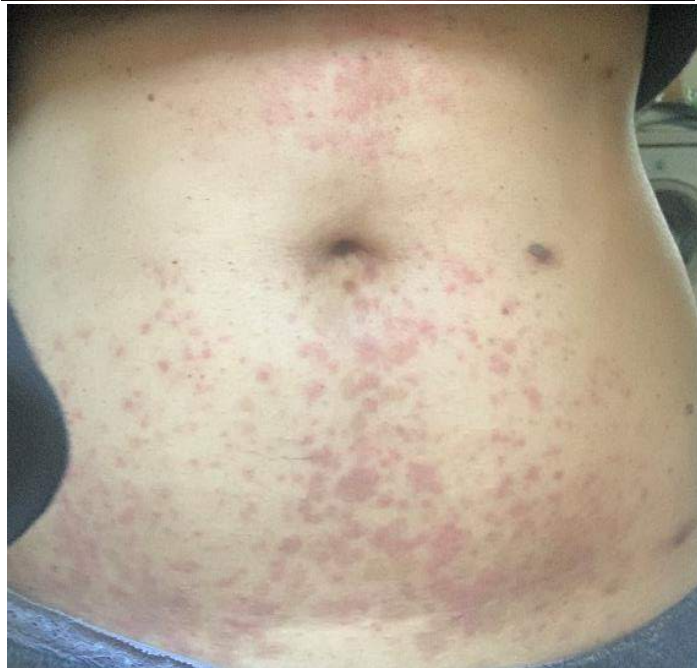
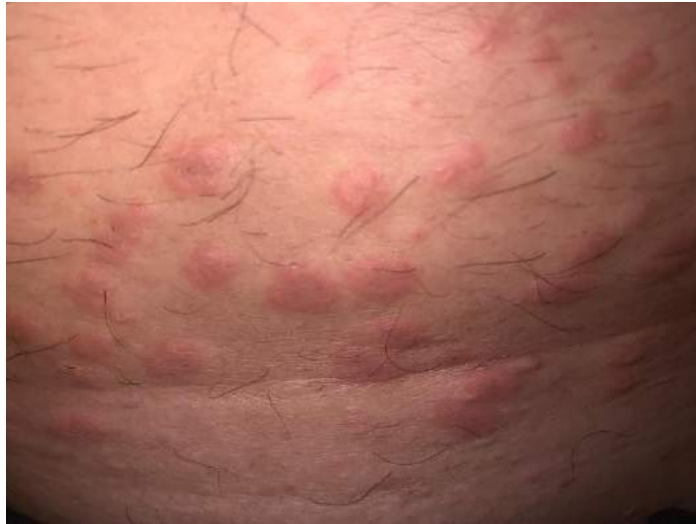
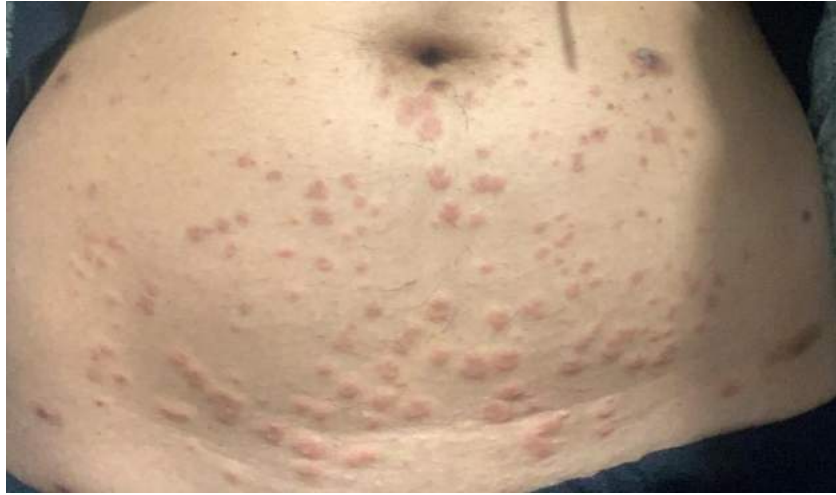

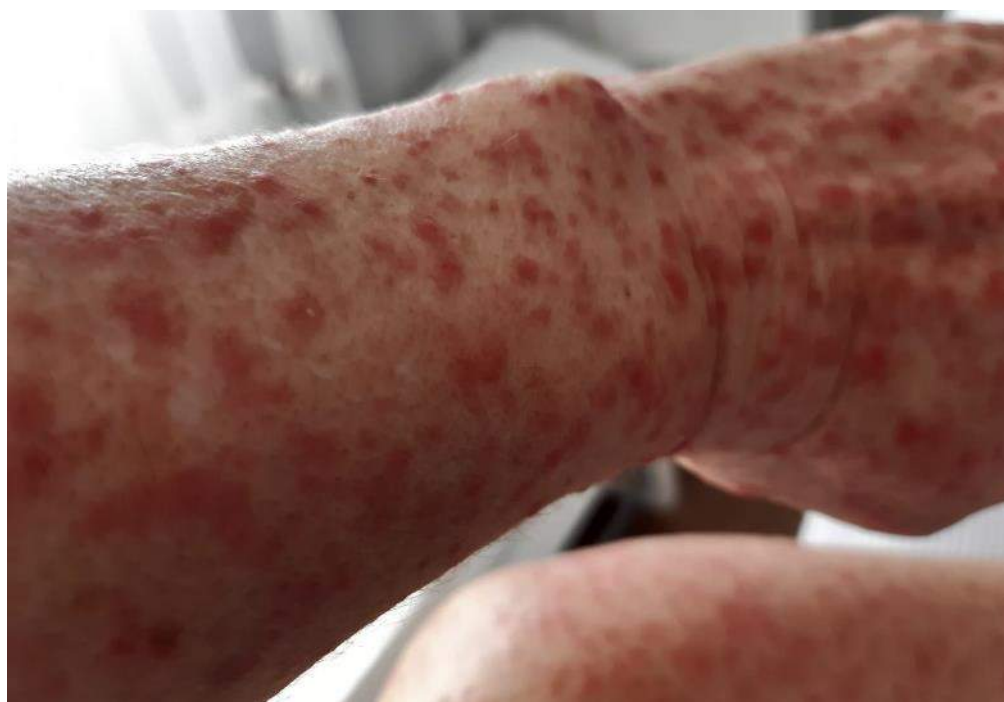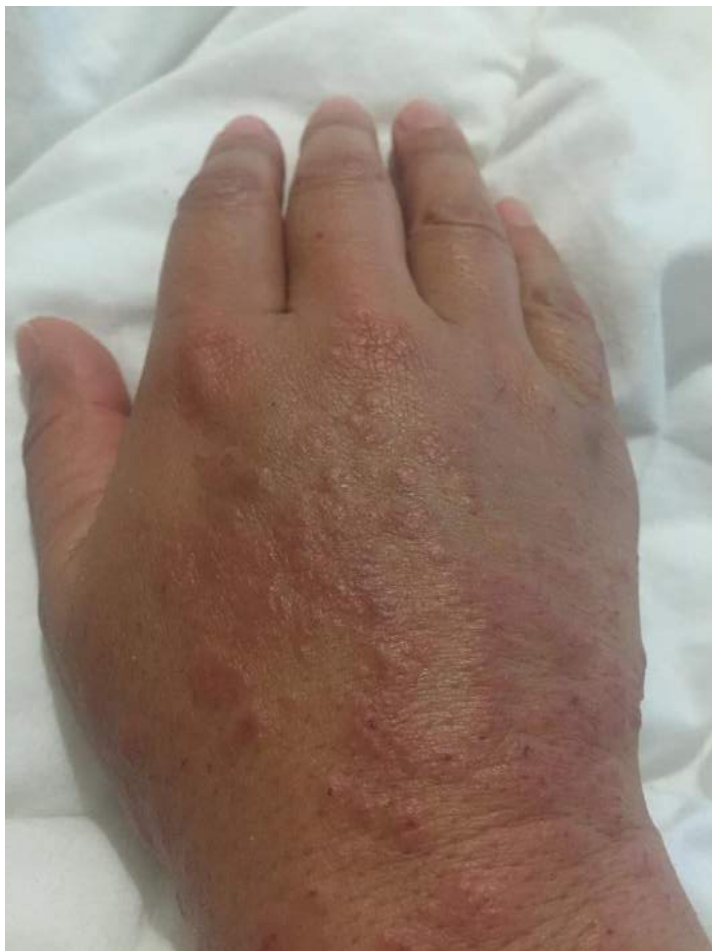Erythema multiforme-like

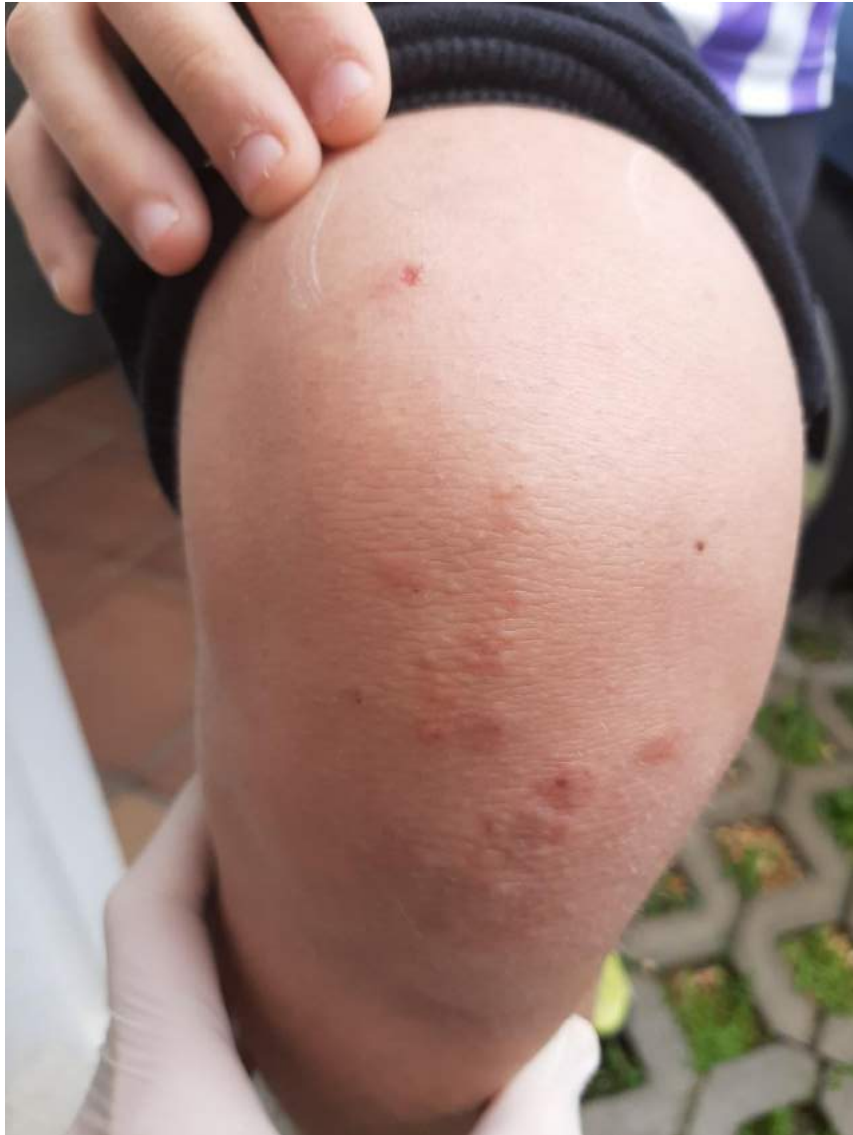


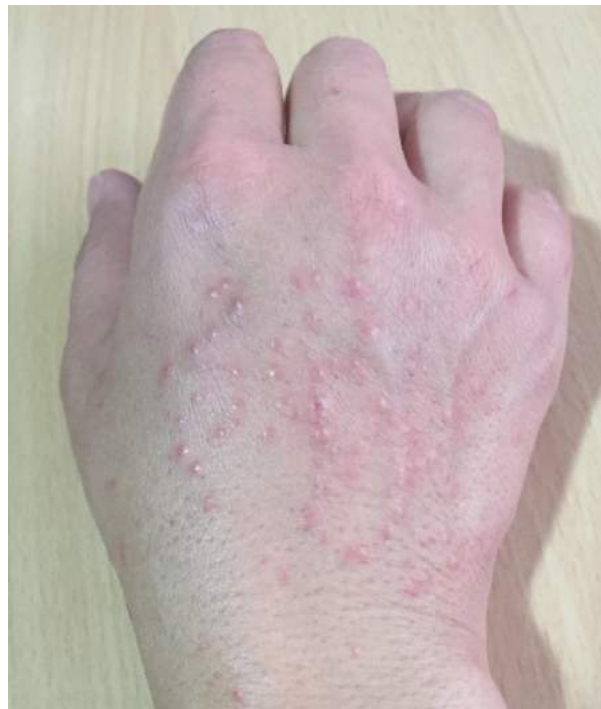
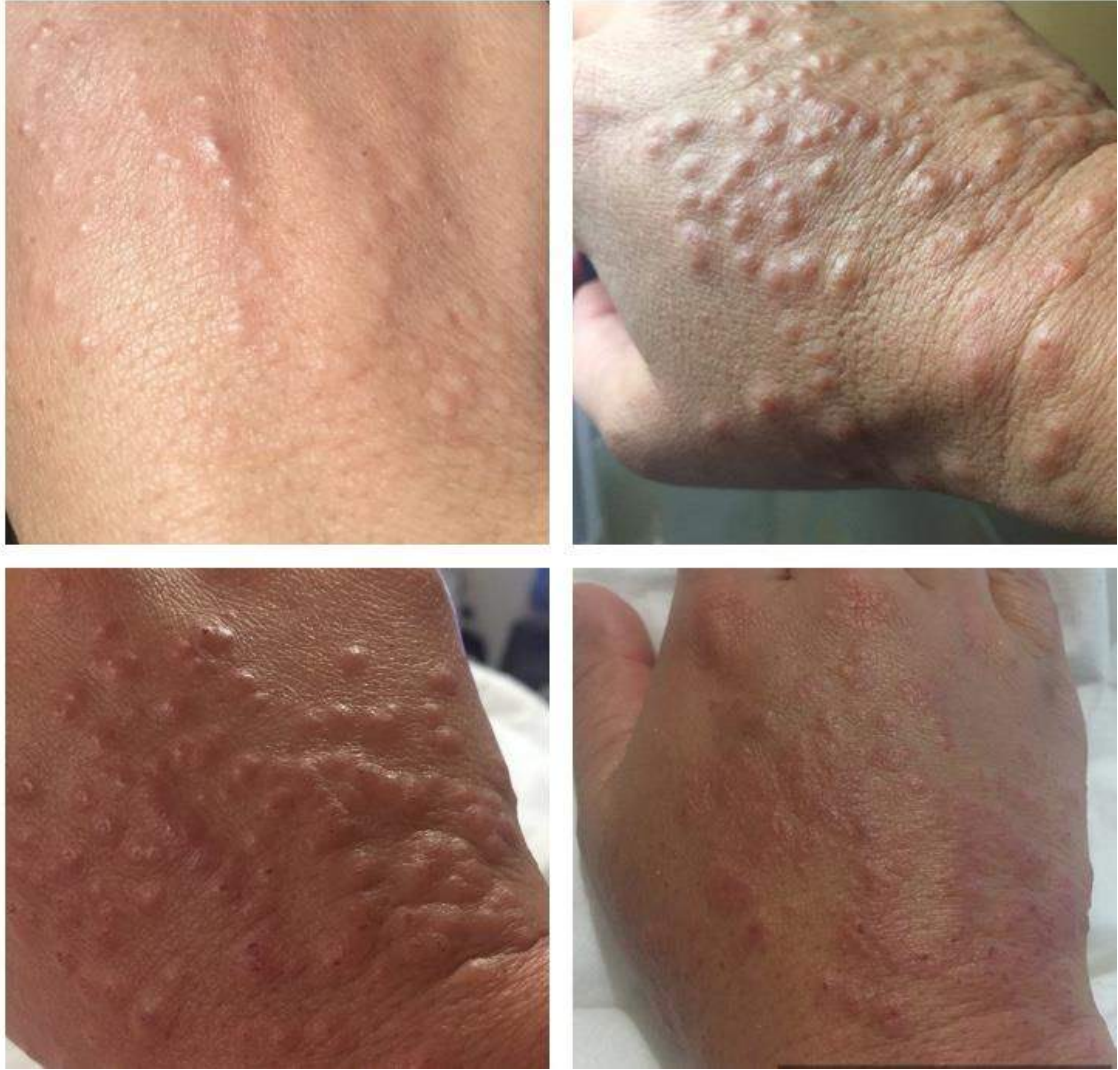

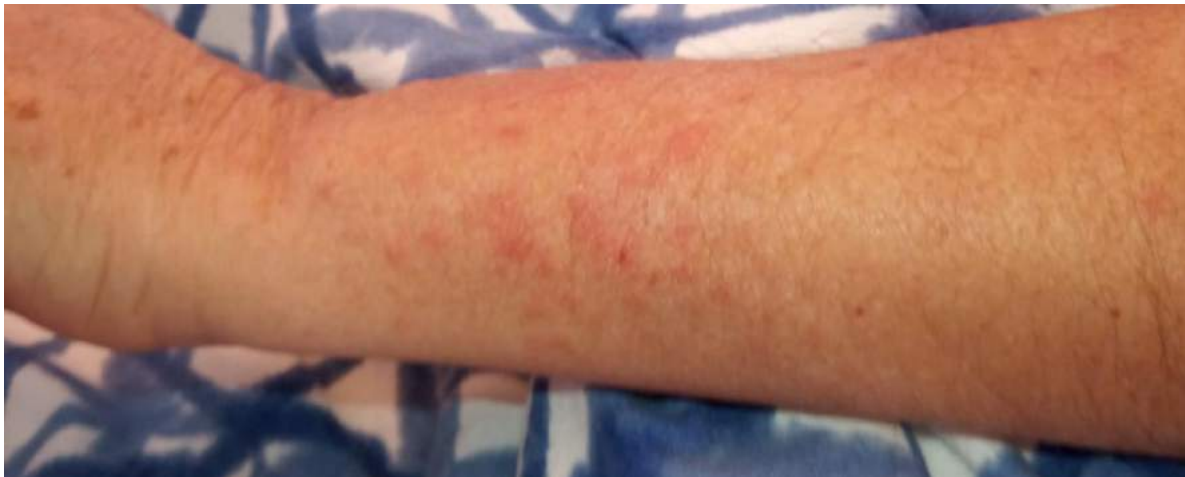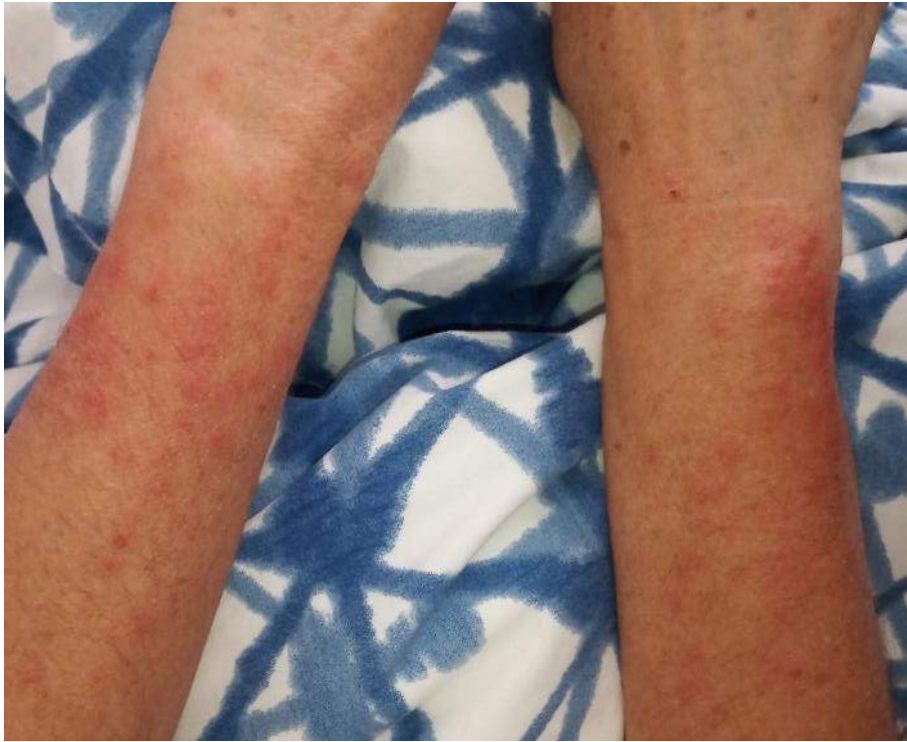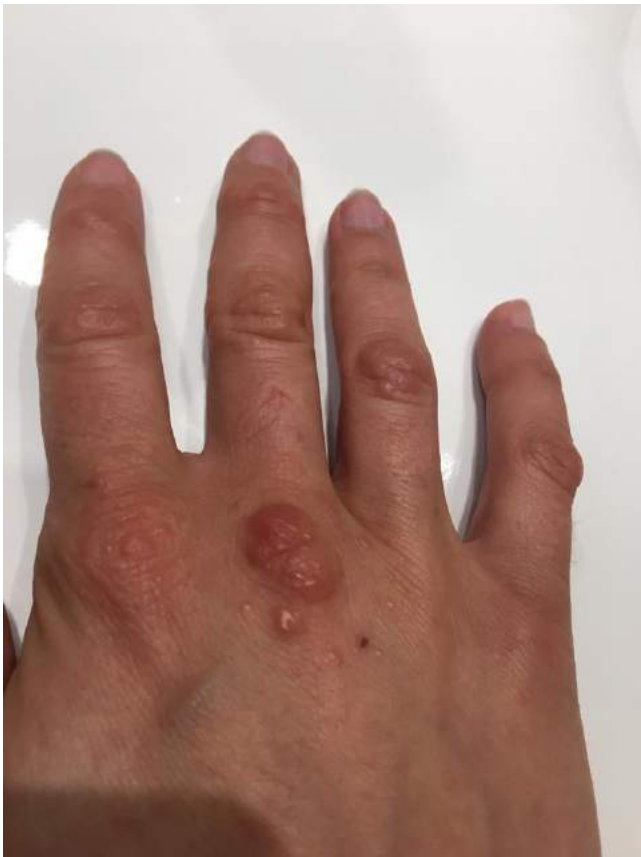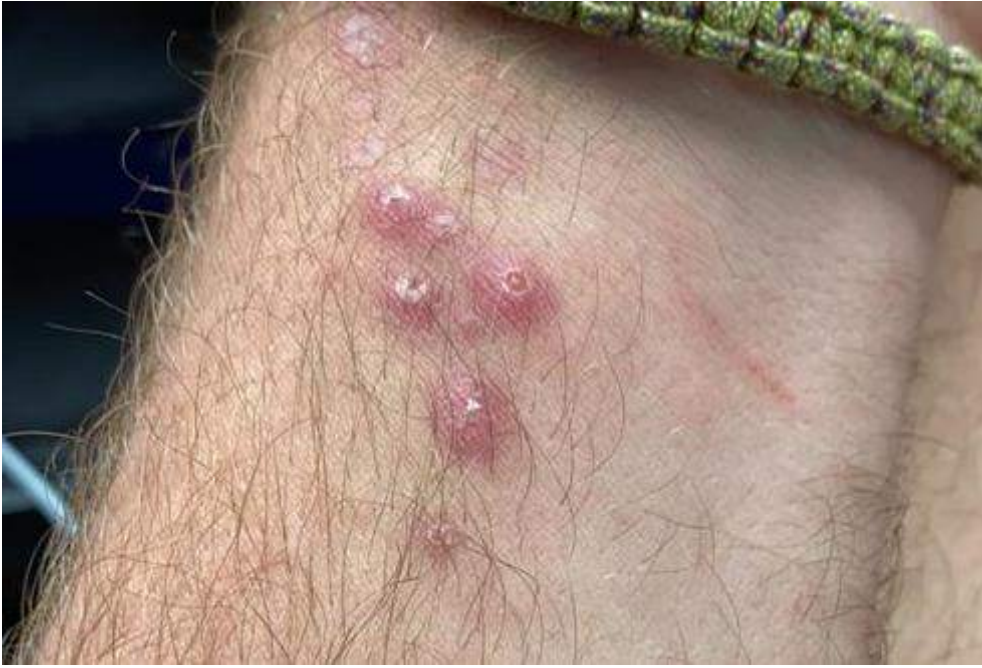Pseudovesicular or resembling erythema elevatum diutinum



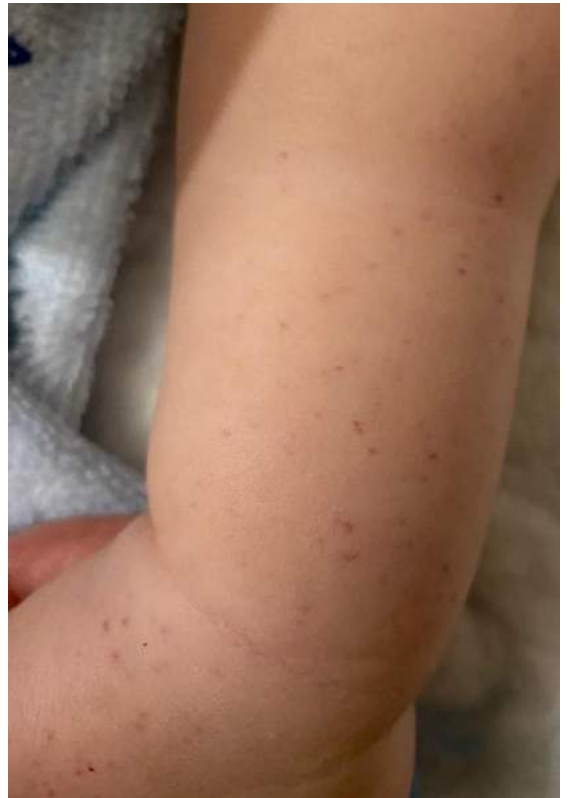
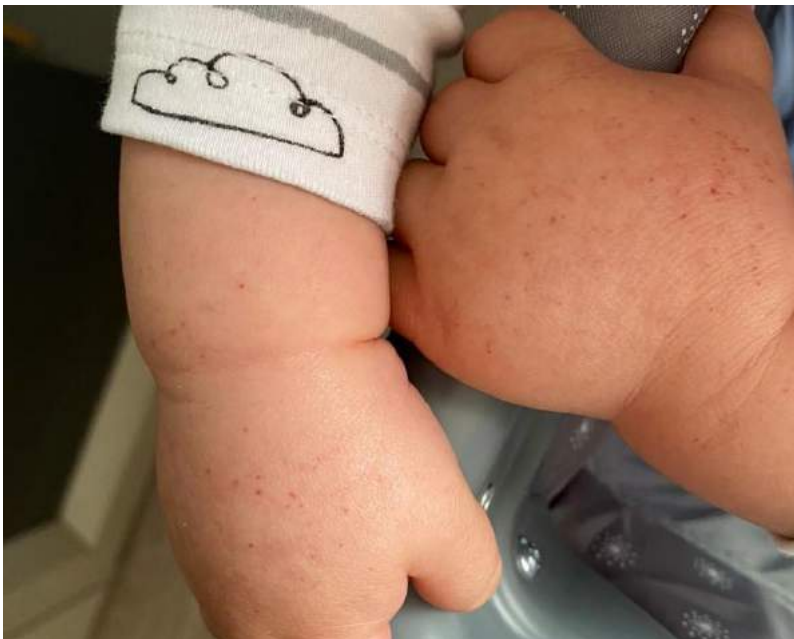
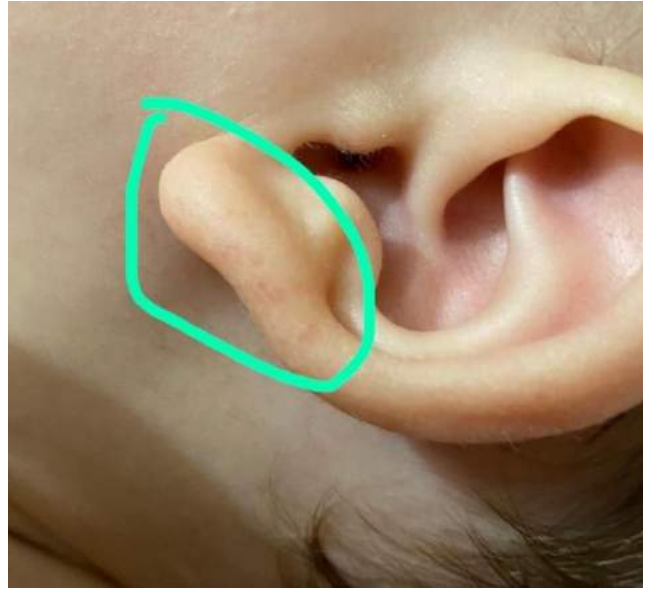
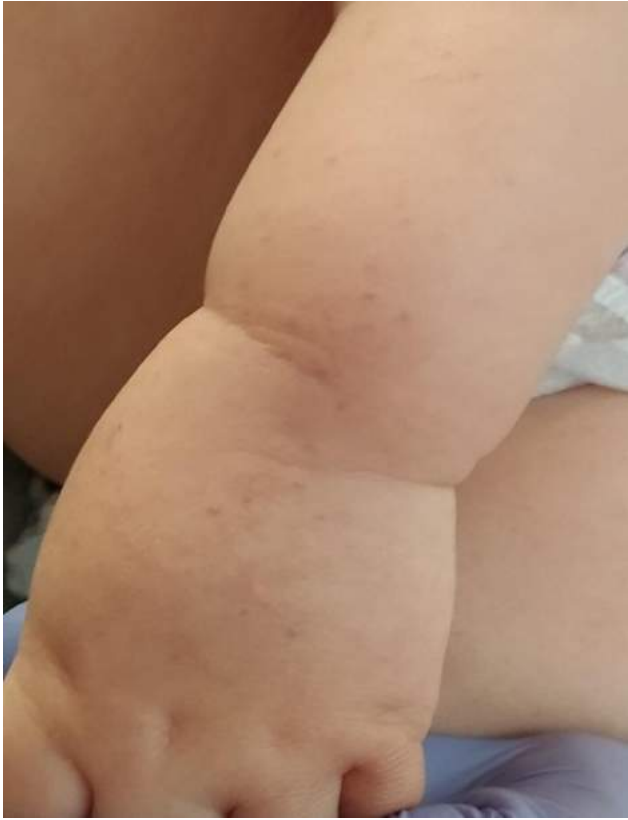




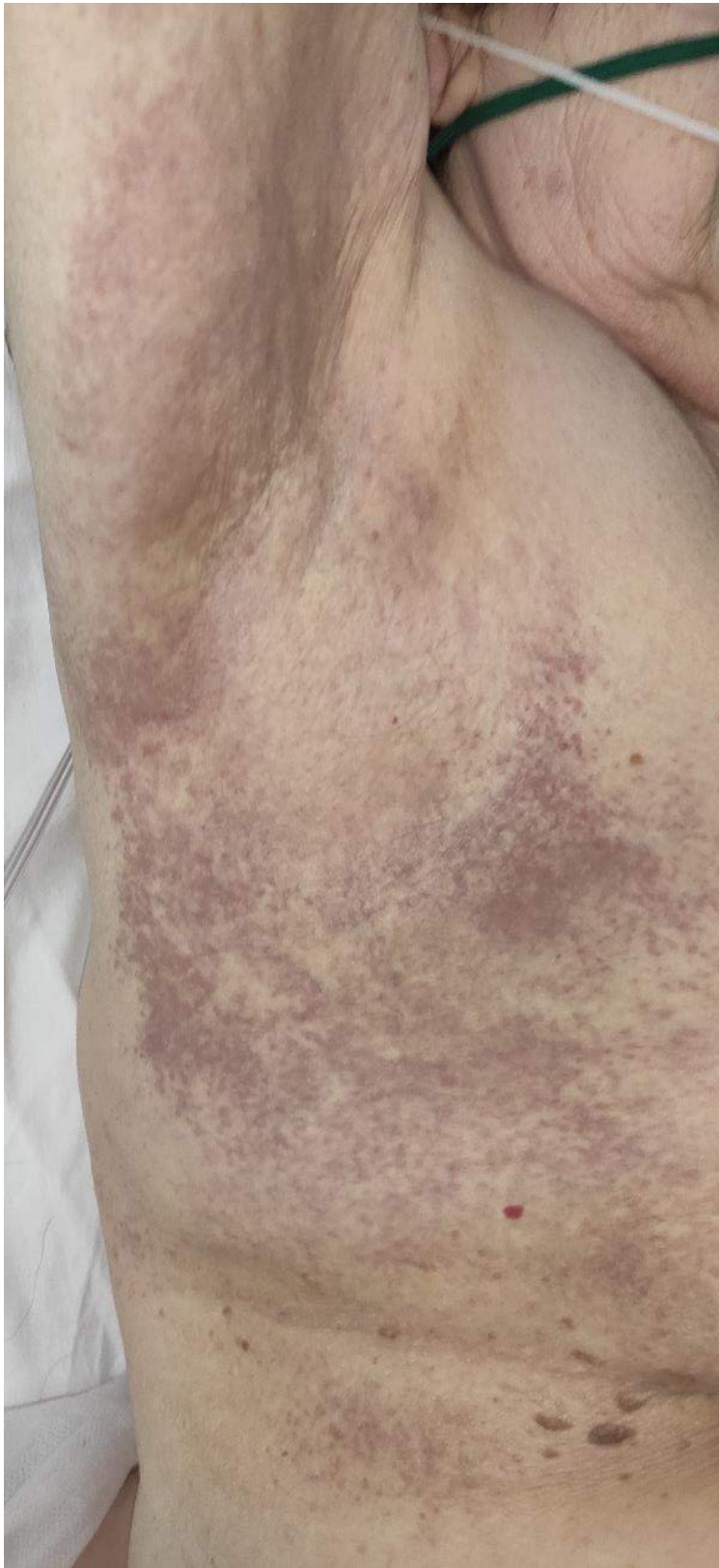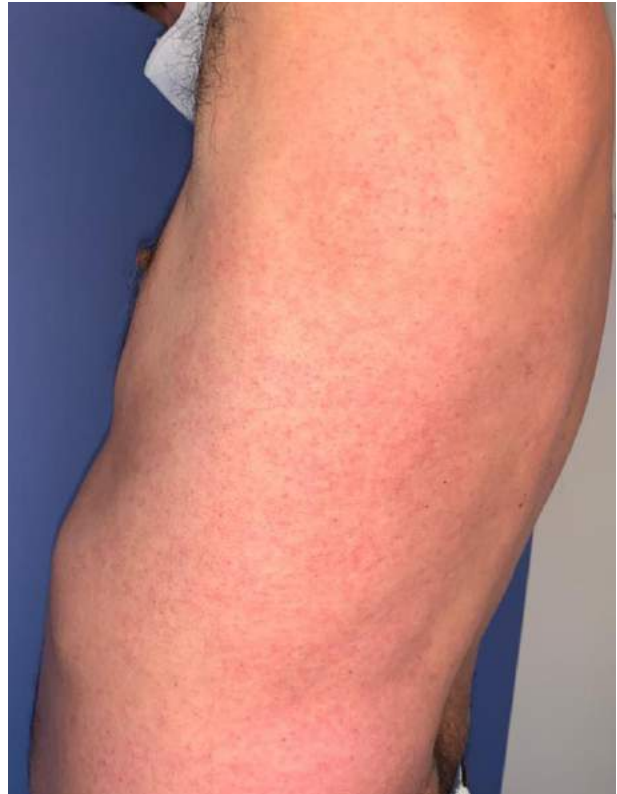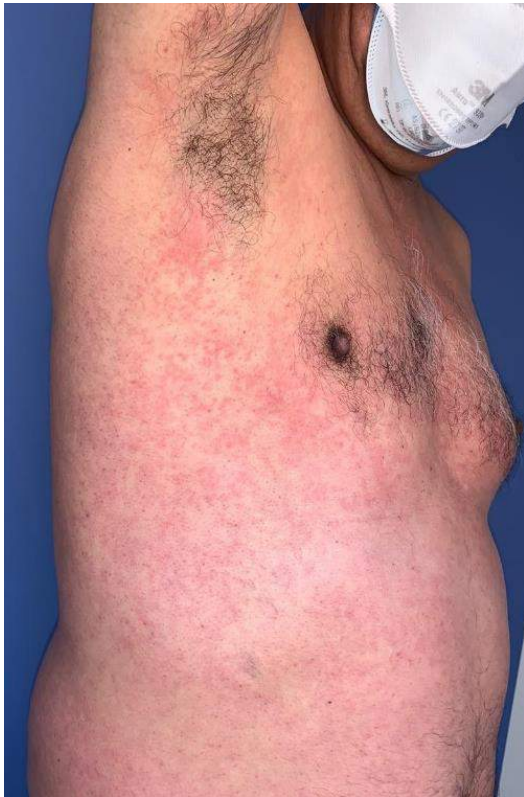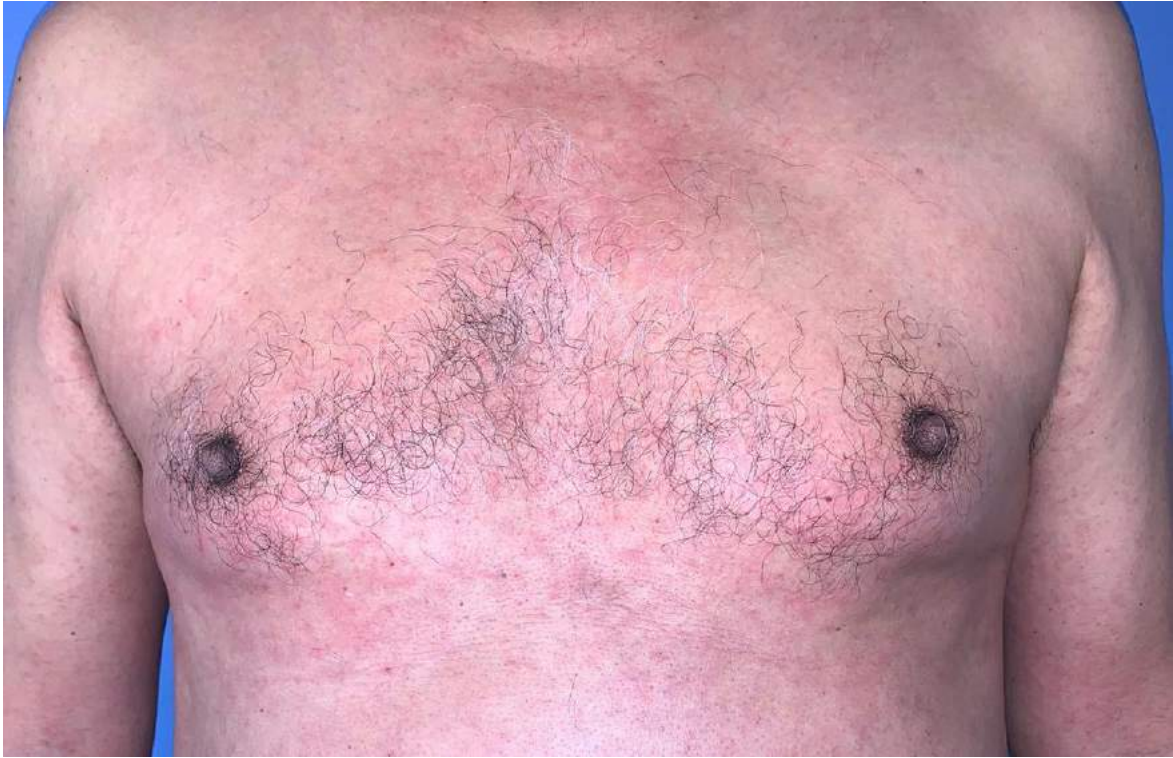Purpuric eruption

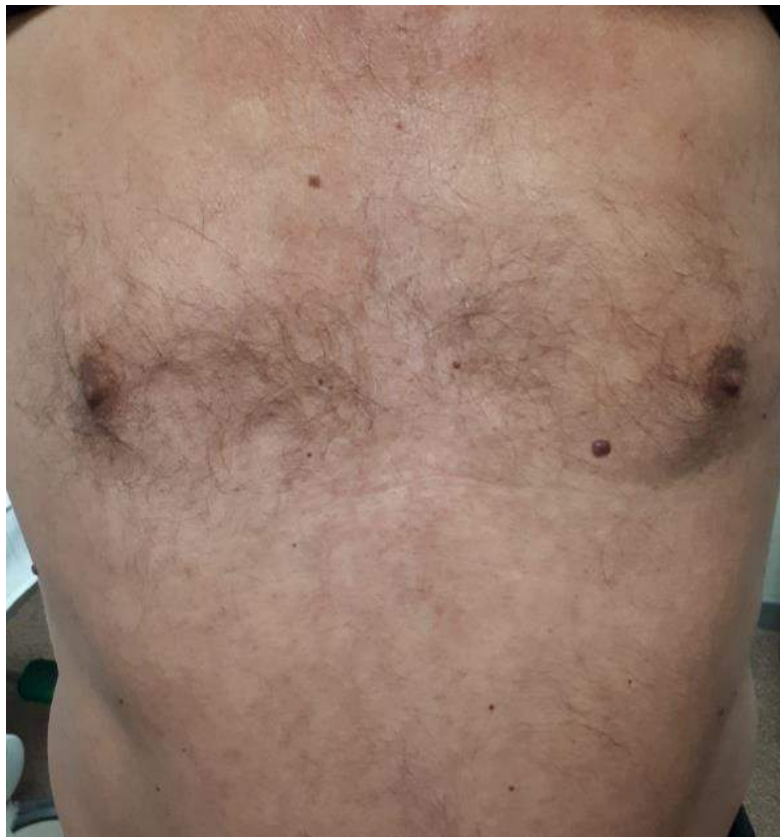
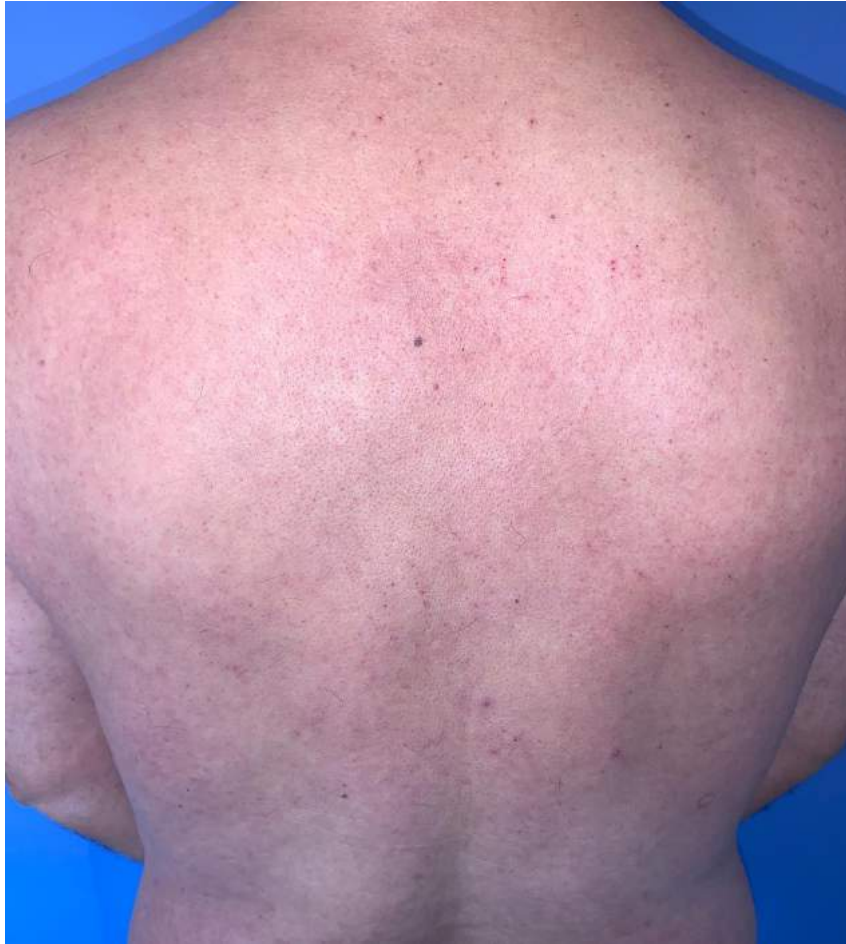
Bilateral axillary purpuric eruption

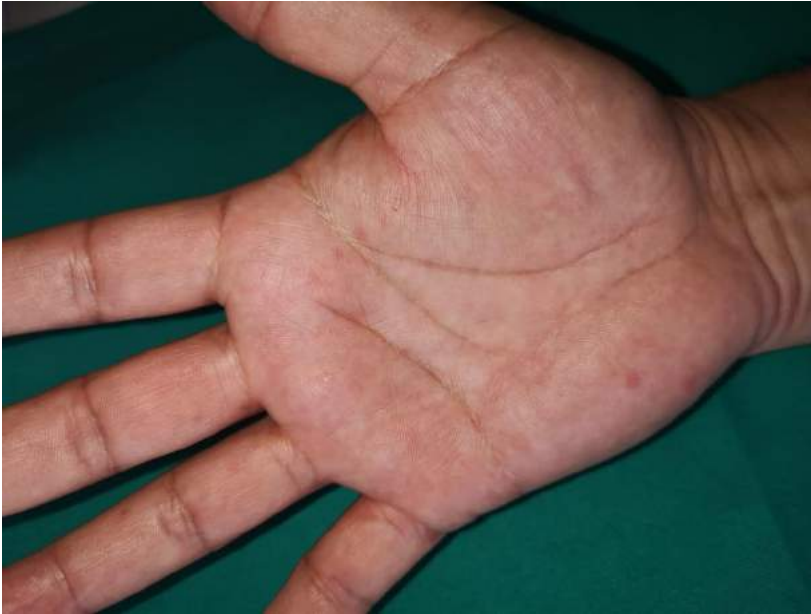

Morbilliform eruptions

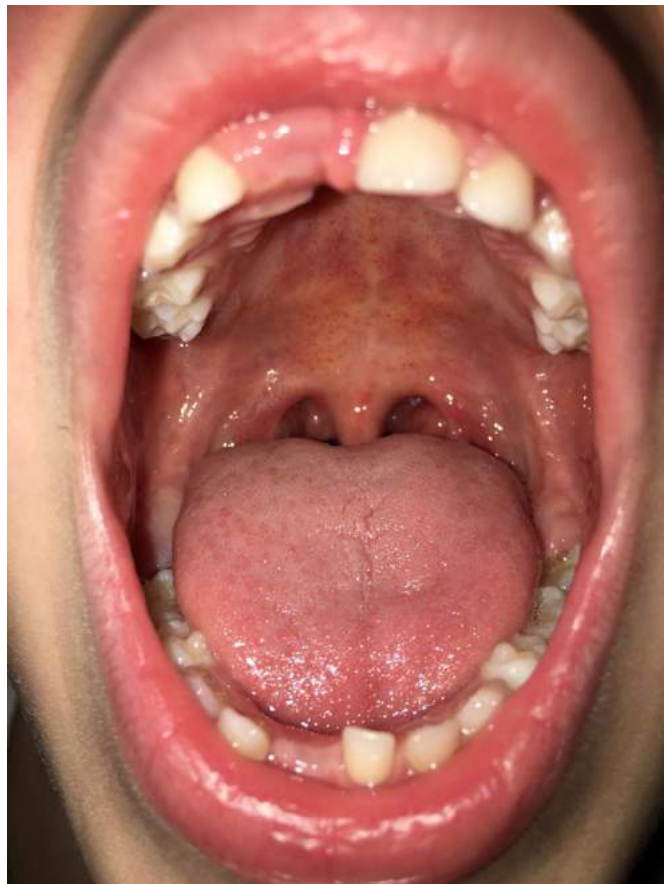
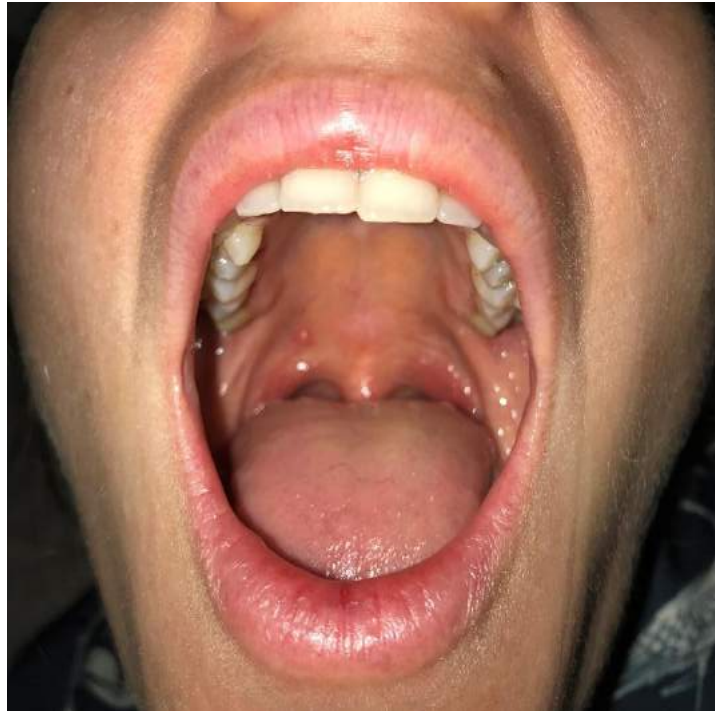


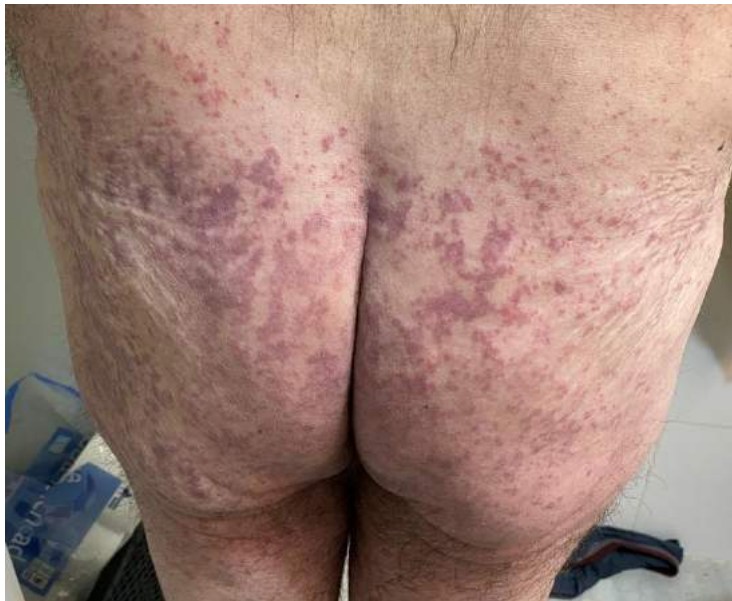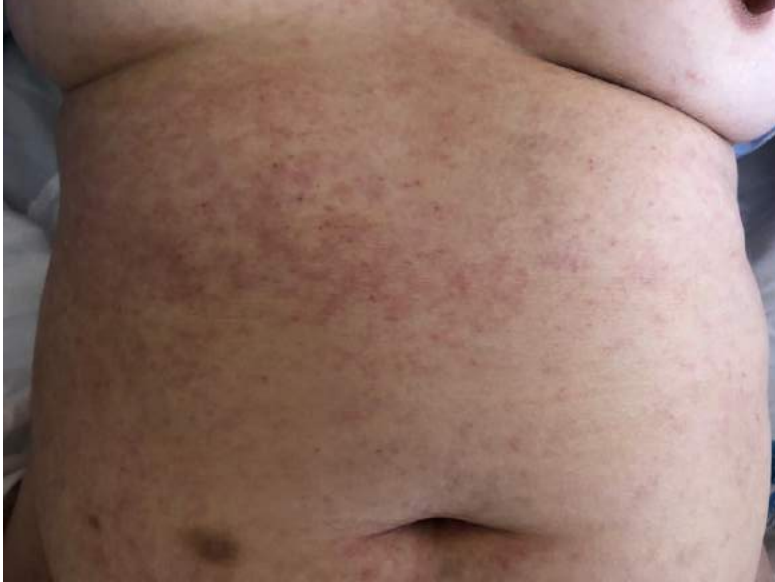Palmar erythema



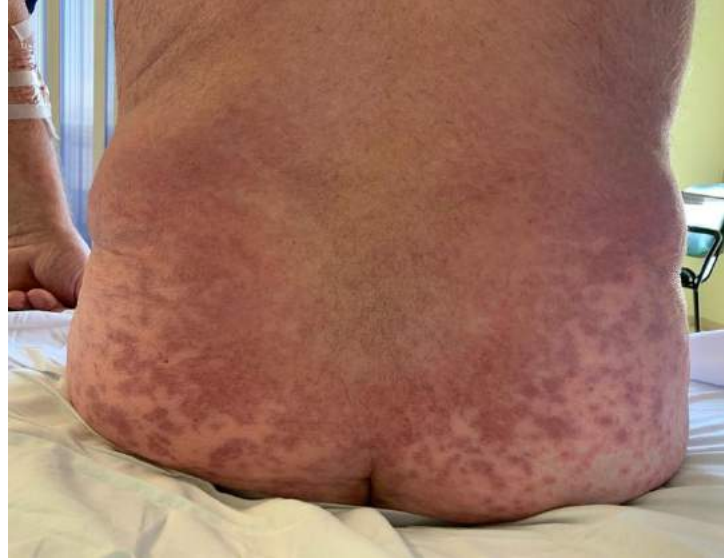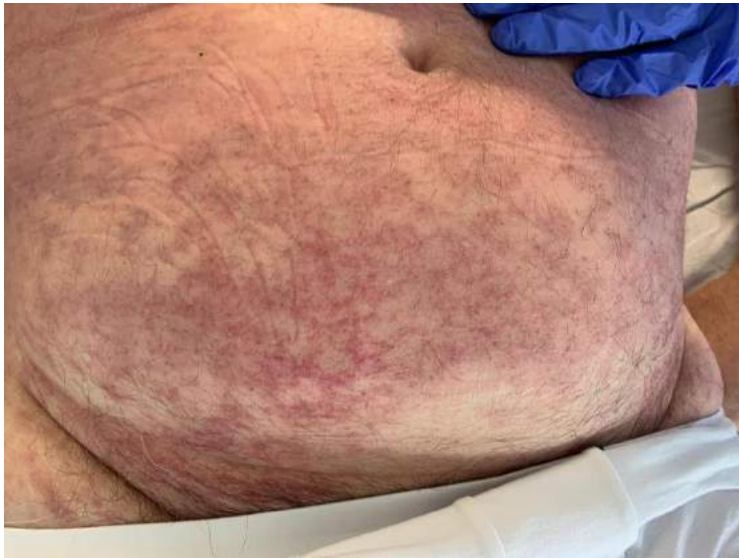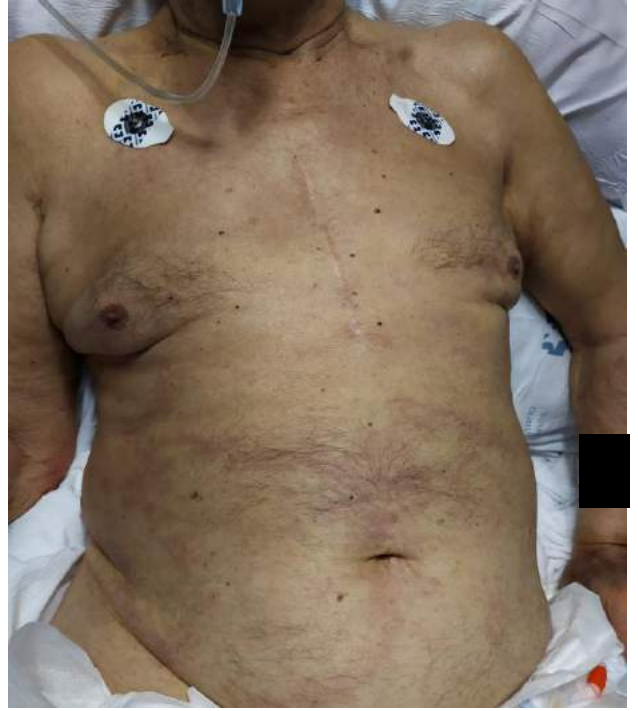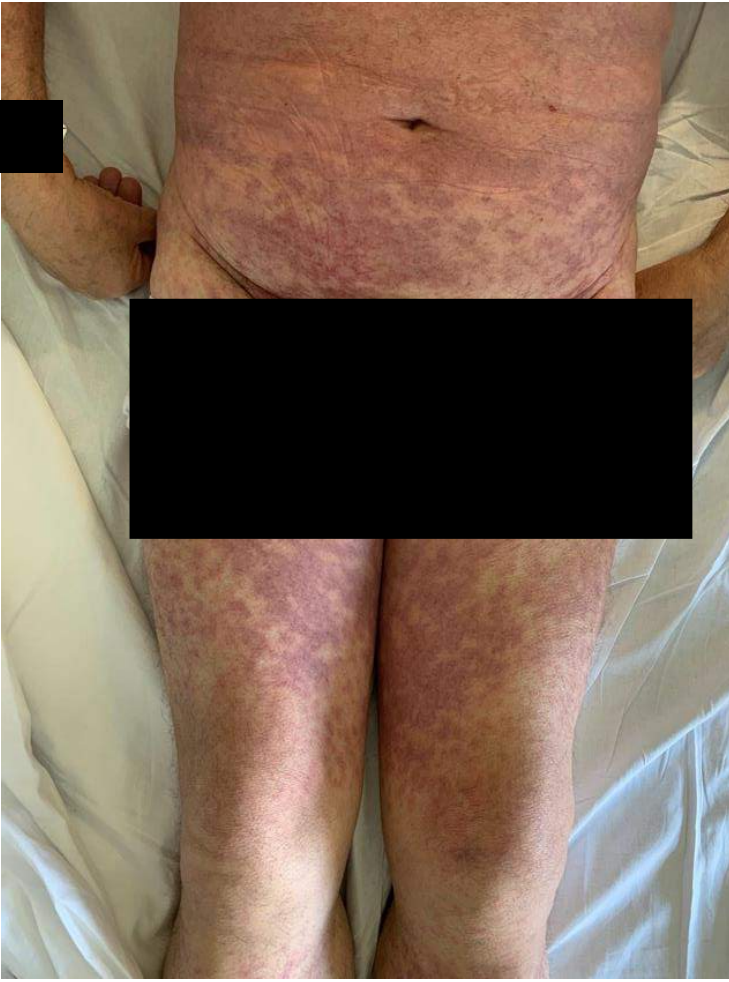Enanthem

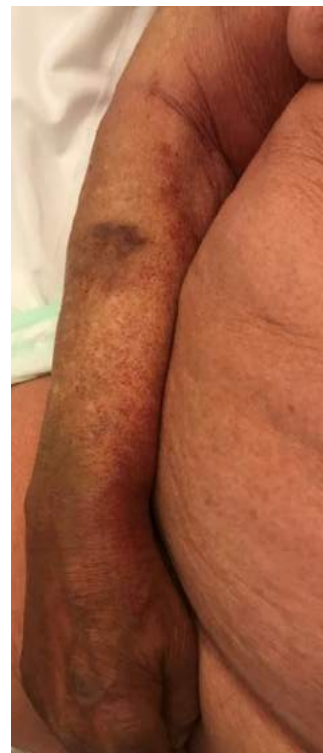
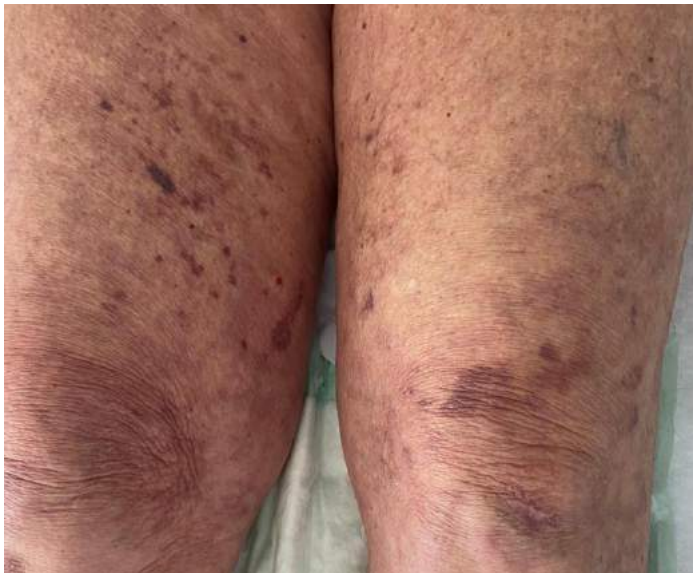
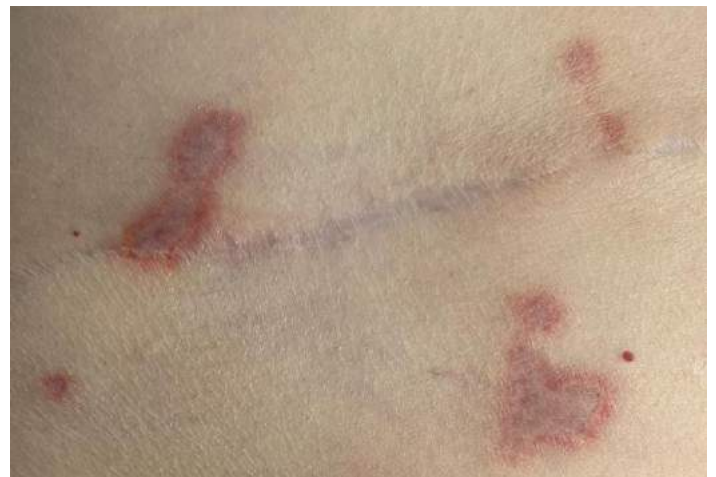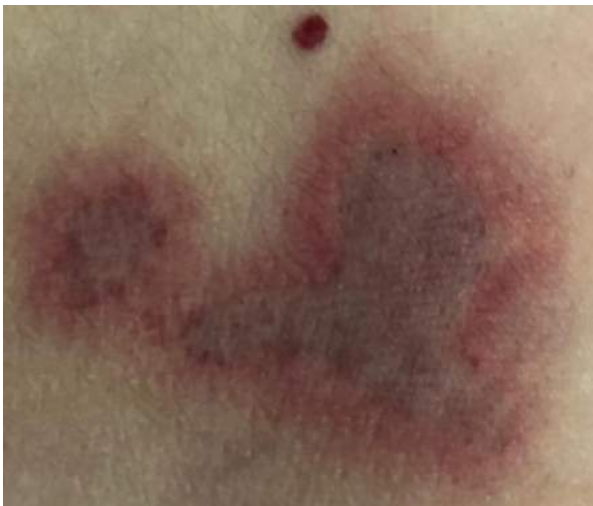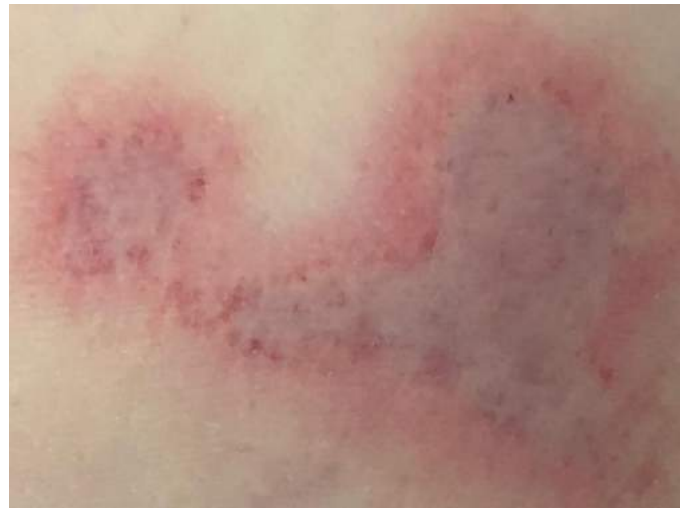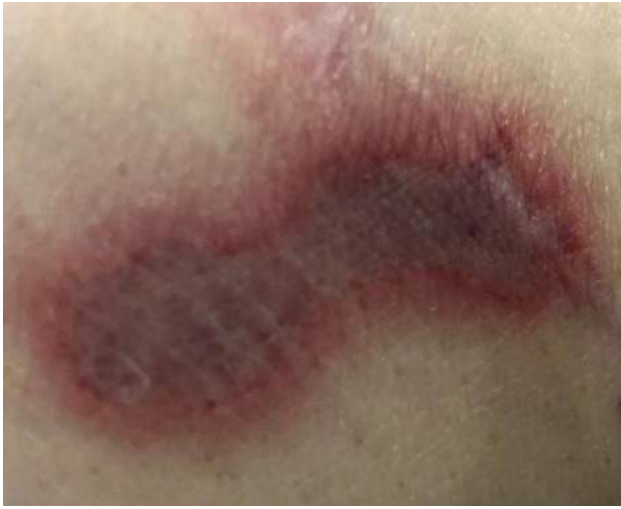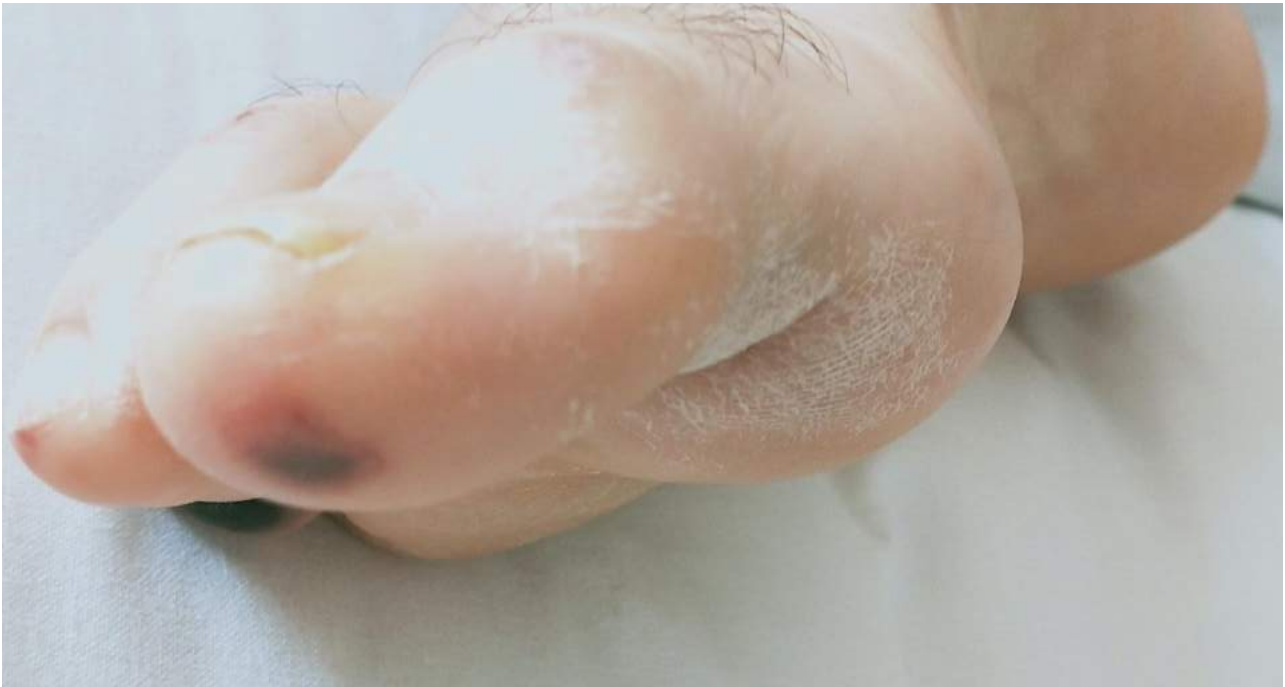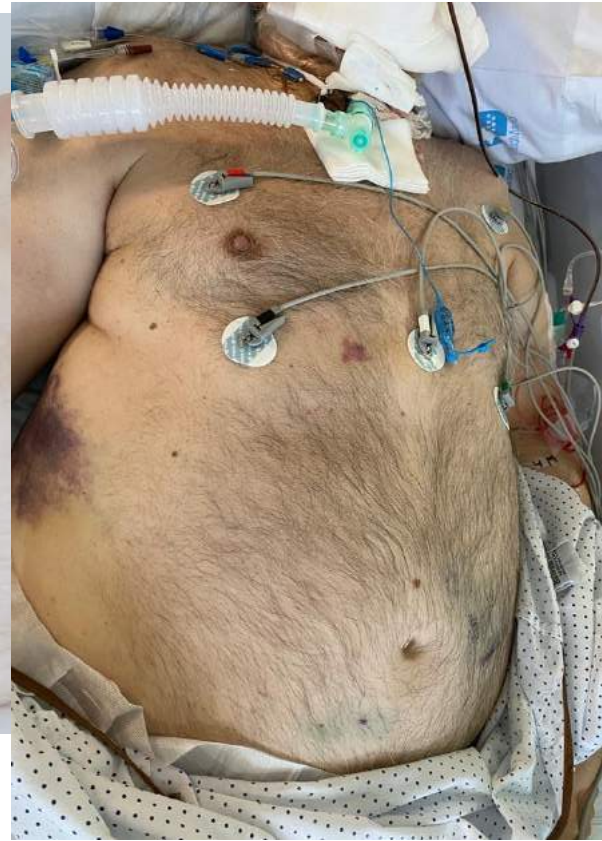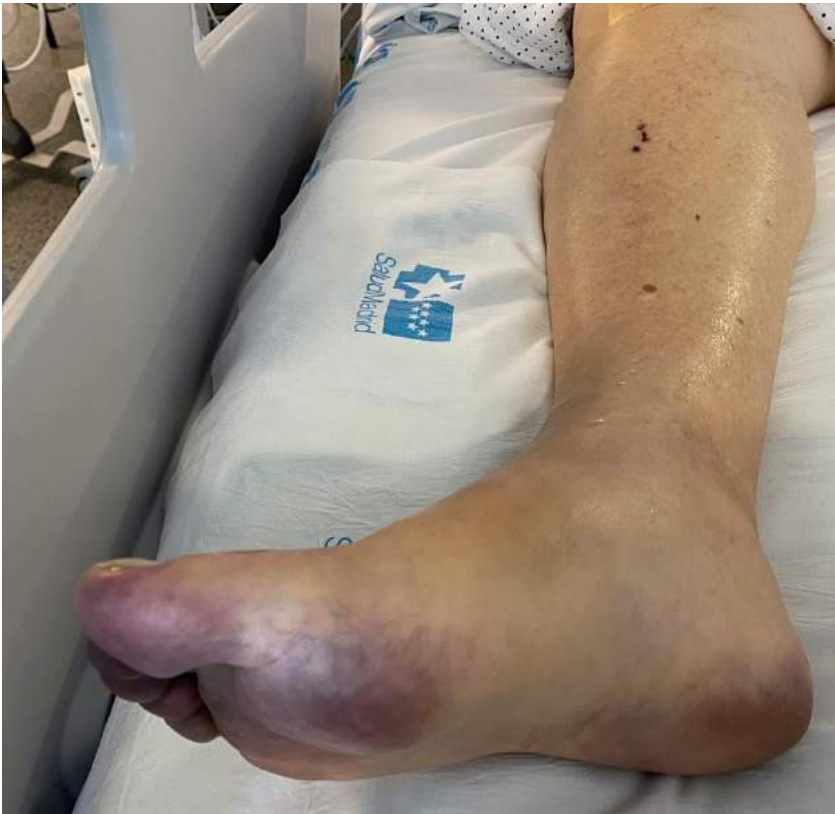Livedoid or necrotic lesions - Confirmed cases



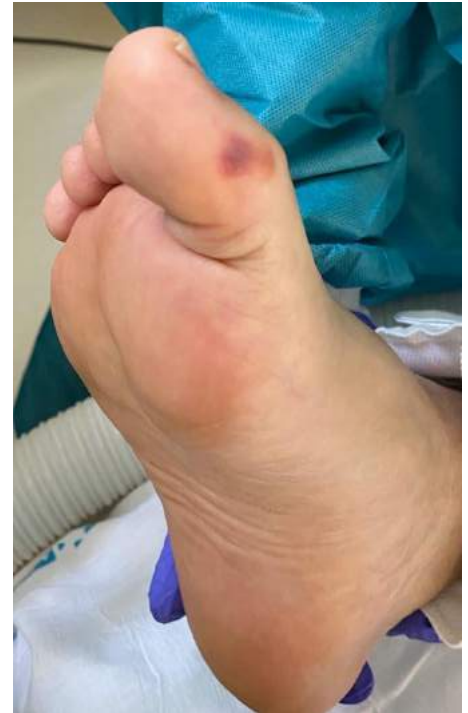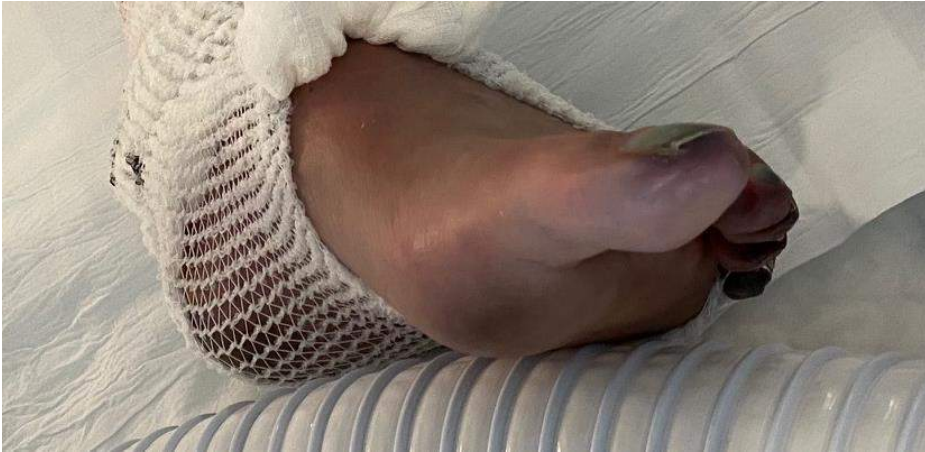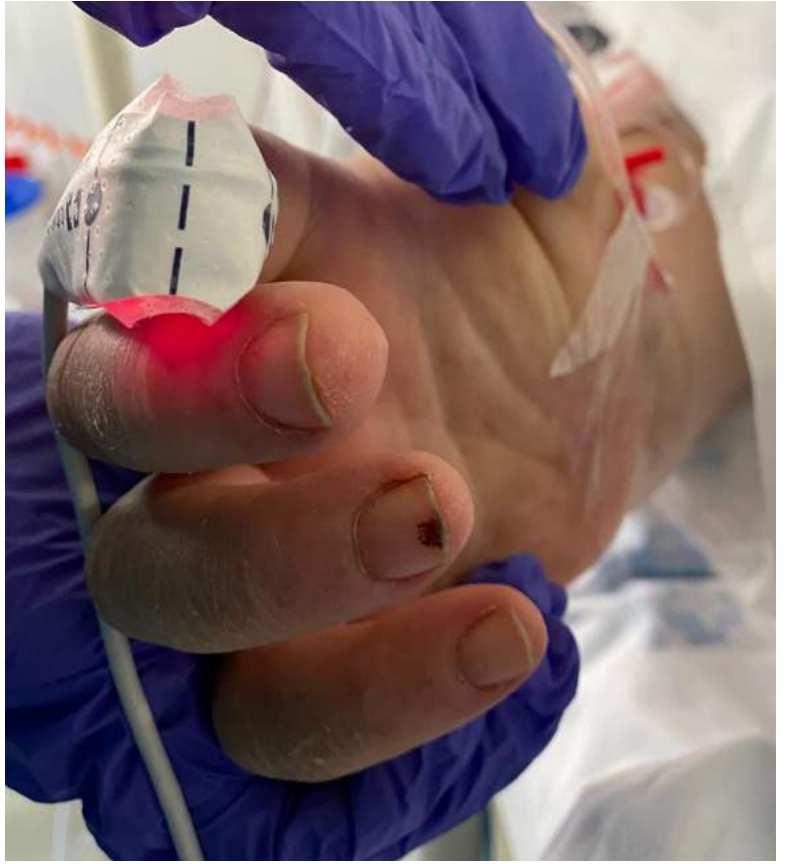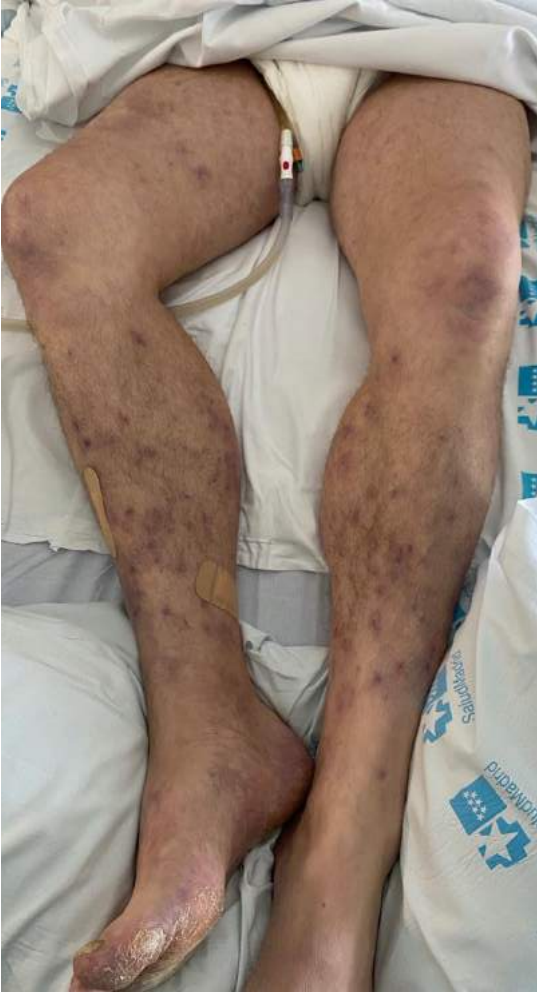use is forbidden

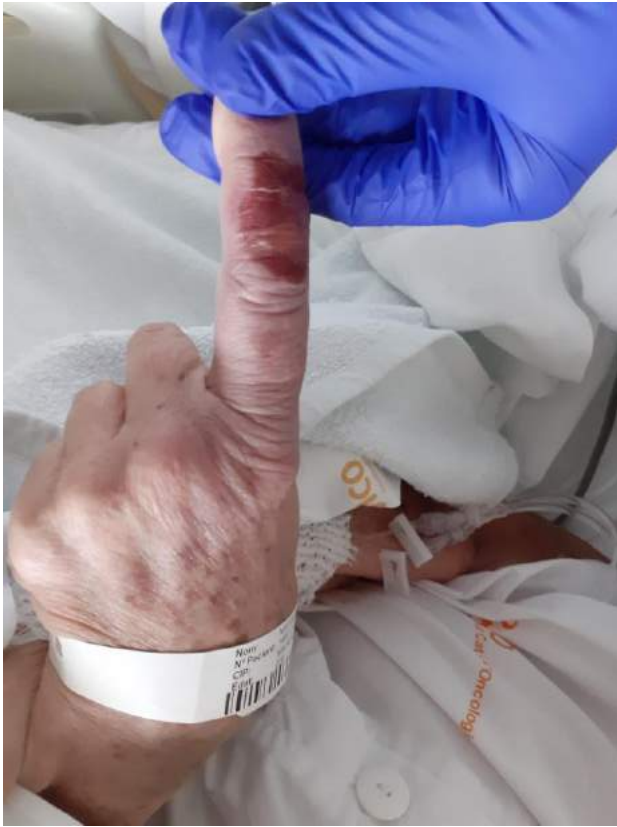





g. Any other use is forbidden.





Livedoid or necrotic lesions - Suspected cases

