

INTERNATIONAL **CONSENSUS**

Best Practice Guidelines

Skin and wound care in
EPIDERMOLYSIS BULLOSA

An expert working group consensus

Wounds_{UK}

PUBLISHED BY:

Wounds International
1.01 Cargo Works
1-2 Hatfields
London SE1 9PG, UK
Tel: + 44 (0)20 3735 8244
www.woundsinternational.com

© Wounds International 2017



This document has been developed by Wounds International and supported by an unrestricted educational grant from the L&R, Coloplast, Ferris/PolyMem, H&R Healthcare and medi UK

The Spanish translation of this document has been funded by DEBRA Spain

The views expressed are those of the expert working group and review panel and may not reflect those of L&R, Coloplast, Ferris/PolyMem, H&R Healthcare and medi UK

How to cite this document:

Denyer J, Pillay E, Clapham J. *Best practice guidelines for skin and wound care in epidermolysis bullosa. An International Consensus*. Wounds International, 2017.

Disclaimer

This document does not seek to be prescriptive, but it provides a framework for practice. It is not intended to replace clinical judgement and in each situation the clinician must use their own judgement about their patient and their particular wounds. In addition, manufacturers' instructions for product usage should also be noted.

Conflict of interest

None of the authors declared a conflict of interest. The original guidelines were funded by an educational award from the Urgo Foundation; there was no influence on the content or process of developing the guidelines. Publication of this updated document is funded by L&R, Coloplast, Ferris/PolyMem, H&R Healthcare and Medi UK and again there was no influence on the content or process of developing the guidelines.

All rights reserved. © 2017

No reproduction, copy or transmission of this publication may be made without written permission. No paragraph of this publication may be reproduced, copied or transmitted save with written permission or in accordance with the provisions of the Copyright, Designs and Patents Act 1988 or under the terms of any license permitting limited copying issued by the copyright licensing agency, 90 Tottenham Court Road, London W1P 0LP.

GUIDELINE DEVELOPMENT TEAM

Authors

Jacqueline Denyer, EB Senior Clinical Nurse Specialist, Great Ormond St Hospital for Children NHS Foundation Trust, London and DEBRA UK (Retired)

Elizabeth Pillay, EB Advanced Nurse Practitioner, Guy's and St Thomas' NHS Foundation Trust Hospital, London and DEBRA UK (EB research)

Jane Clapham Lead EB CNS, Adults, Guy's and St Thomas' NHS Foundation Trust Hospital, London and DEBRA UK

EXPERT REVIEWERS AND CLINICAL TEAMS

Reviewers

Magnus Agren, Professor, Department of Surgery and Copenhagen Wound Healing Center, Bispebjerg Hospital, Copenhagen, Denmark

Jo-David Fine, Professor of Medicine (Dermatology) and Professor of Paediatrics, Vanderbilt University School of Medicine, Nashville, Tennessee, USA

Ravi Hiremagalore, Paediatric Dermatologist, Dr Malathi Manipal Hospital, Banaglore, India

Avril Keenan, Research Manager, DEBRA Ireland

Anna Martinez, Consultant, Paediatric Dermatology, Great Ormond Street Hospital for Children, London, UK

Kattya Mayre-Chilton, Clinical Practice Guideline Coordinator/Psychosocial CPG Project Manager and Research Dietician, Guy's and Thomas' NHS Foundation Trust, London, UK

Jemima Mellerio, Professor, Consultant Dermatologist, St John's Institute of Dermatology, Guy's and Thomas' NHS Foundation Trust and Great Ormond Street Hospital NHS Trust, London, UK

Elizabeth Orrin, EB Clinical Research Fellow, Guy's and Thomas' NHS Foundation Trust and Great Ormond Street Hospital NHS Trust, London, UK

REVIEW BY EB TEAMS

Great Ormond Street Hospital, London
St Thomas' Hospital, London
Birmingham Children's Hospital
Heartlands Hospital, Birmingham
DEBRA Ireland and DEBRA International.



Introduction

What is this Scottish Intercollegiate Guidelines Network (SIGN)?

■ *The Scottish Intercollegiate Guidelines Network (SIGN) develops evidence-based clinical practice guidelines for the National Health Service (NHS) in Scotland. SIGN guidelines are derived from a systematic review of the scientific literature and are designed as a vehicle for accelerating the translation of new knowledge into action to meet our aim of reducing variations in practice, and improving patient-important outcomes.*

PURPOSE AND SCOPE

These guidelines have been developed to aid all clinicians who manage the skin and wound care of patients with the genetic skin fragility disorder epidermolysis bullosa (EB). Management strategies for wounds or wound complications are suggested for patients of any age diagnosed with any form of this genetically inherited disorder. It is a tool that can be used globally and includes advice for practitioners who have limited access to wound care materials. A variety of options for managing EB wounds will be presented.

ABOUT THIS DOCUMENT

This document was developed using a survey of clinicians from different countries who work with the condition and who were prepared to share their knowledge of EB wounds and their management. A systematic literature search (described overleaf) was undertaken to provide further evidence for recommendations. However, as EB is a rare condition with small patient numbers, the literature is predominantly made up of non-analytic studies or expert opinion (Scottish Intercollegiate Guidelines Network Level 3-4 or D). A review of dressings conducted by Ly (Ly and Su, 2008) noted the difficulties in evaluating wound care options in EB where patient numbers are small and there is inconsistency in the outcome measures used.

The information was supplemented by day-to-day experience of people living with EB and their carers' testimonials. This was gathered informally at home visits and clinic attendances by EB nursing teams.

Cost is always a factor to be considered in any healthcare recommendations and this is particularly relevant for EB treatments where vast quantities of expensive dressings can be used over a lifetime (Kirkorian, Weitz et al, 2014; Angelis, Kanavos et al, 2016). We have recommended only products that we have experience of using over many years and where we are confident of the results they can achieve.

HOW THE GUIDELINES WERE DEVELOPED

The initial work was carried out in workshops in 2012; opinions were gathered from clinicians working with patients with EB, both in the UK and worldwide.

As part of an advanced course on EB management, nurses and doctors working with EB patients were asked to complete a questionnaire relating to the management of a range of EB wounds. These wounds ranged from chronic ulcerated areas seen in the more severe forms of EB, to new blister sites; they were chosen by the authors as they represent the most common wound types seen in all forms of EB, or a particular problem area.

The group was supplied with photographs of both typical and atypical wounds and asked which primary and secondary dressings, the preferred method of retention and any topical treatments they would use in managing the wound. They were asked to give a range of options for each category.

There was a wide range of experience of wound management for EB within the group: some clinicians had large caseloads having worked solely with EB for many years; others had only experienced one or two cases. Some of the group worked as individuals while others worked as part of a team, largely reflecting their common working practices. In addition, some participants had limited access to modern wound management products (see Table 17, page 38).

The results of the surveys were drawn together to supply evidence for the guidelines. Opinions were given from clinicians from different countries. The draft guidelines were then subject to international peer review by recognised experts in the field of EB, and modifications were made accordingly. The guidelines were then reviewed by a small group of patients and carers, and their feedback was used to make further modifications.

In order to develop the 2017 update, we conducted a more comprehensive literature review and used the results as a basis for recommendations. The 2012 guidelines search was limited to papers published between 2000 and 2011: the search years have been extended and the search methodology improved, both of which are detailed below. In addition, new wound management products, which have been used and evaluated by the guideline group and other EB professionals, have been included.

PLANS FOR UPDATING THE GUIDELINES

The guidelines will be reviewed and updated in three years time following a further literature review.

LITERATURE REVIEW

Search methodology

A systematic literature search was undertaken concluding in July 2016. The databases searched were Medline, Embase, British Nursing Index and CINAHL. The search limits were papers published from 1980 to July 2016, papers published in English and involving humans. As wound management is a rapidly evolving field, it was felt that papers published prior to 1980 were unlikely to yield information that is appropriate to today. This latter point was proven as many papers published in the earlier decades of our search recommended out-dated strategies such as the use of continuous topical antibiotics; a measure now known to lead to bacterial resistance (Moy, Caldwell-Brown et al, 1990; Amirthalingam, Yi et al, 2015).

In order to be thorough the initial search term used was 'epidermolysis bullosa' followed by separate searches on 'wound', 'erosion', 'dressing', 'exudate', 'pruritus', 'itch', 'odour', 'pain', 'cancer', 'malignancy', 'carcinoma', 'wound dressing', 'wound care', 'wound pain', 'wound management'. The search terms were then individually combined with 'epidermolysis bullosa' using the Boolean operator 'and'.

SEARCH RESULTS

The papers were then appraised and graded by the reviewers as per the SIGN guidelines and a synopsis made of the information they contained. SIGN now uses a new methodology for grading; however, the older system was chosen both because it is familiar to the guideline development group and because it had been used in all previous EB guidelines.

Initial results were screened at the abstract stage
1,342 abstracts were retrieved
422 were duplicates
920 unique results
102 further duplicates were removed manually
818 abstracts to review
636 abstracts rejected as not relevant; these were excluded because they did not relate to the topic (e.g. papers discussing EB <i>acquisita</i> , surgical management or related purely to non-clinical issues)
182 were identified for reading of the full papers

After reading the full papers
70 were identified to be included in the review
112 were excluded as not relevant or contained information that was deemed potentially harmful, such as the use of topical antibiotics as cited above


The majority of the papers were graded level 3, being small-scale case studies with many others being level 4 i.e. expert opinions. Given the rarity of EB and the many compounding factors that impact healing, it is difficult to conduct statistically valid studies to provide evidence to support the efficacy of any particular wound management strategy.

There is variation in study methodology and outcome measures, as noted previously Ly (Ly and Su, 2008) in a review of EB blister management. Additionally and importantly Petrof (Petrof, Martinez-Queipo et al, 2013), while investigating the use of fibroblasts in wound healing in EB, highlights the fact that the natural history of wound healing in the condition is unknown, and that the chronic wounds previously assumed to be static can in fact change and reduce in size over time with no new treatment modality being introduced. A lesson to be drawn from the literature review may be that we need to be more rigorous and consistent about the methodologies used in evaluating any wound management strategy.

However, the combination of knowledge of good wound care practice, the evidence presented here and the generous sharing of information and experience among professionals, patients and carers provides a substantial body of evidence to support current wound care practice in EB.

SIGN GRADING SYSTEM

Levels of evidence	
1	<ul style="list-style-type: none"> ++ High-quality meta-analyses, systematic reviews of RCTs, or RCTs with a very low risk of bias + Well-conducted meta-analyses, systematic reviews, or RCTs with a low risk of bias - Meta-analyses, systematic reviews, or RCTs with a high risk of bias
2	<ul style="list-style-type: none"> ++ High-quality systematic reviews of case control or cohort or studies High-quality case-control or cohort studies with a very low risk of confounding or bias and a high probability that the relationship is causal + Well-conducted case-control or cohort studies with a low risk of confounding or bias and a moderate probability that the relationship is causal - Case-control or cohort studies with a high risk of confounding or bias and a significant risk that the relationship is not causal
3	Non-analytic studies, e.g. case reports, case series
4	Expert opinion

Grades of recommendations	
A	<p>At least one meta-analysis, systematic review or RCT rated as 1++, and directly applicable to the target population; or</p> <p>A body of evidence consisting principally of studies rated as 1+, directly applicable to the target population, and demonstrating overall consistency of results</p>
B	<p>A body of evidence including studies rated as 2++, directly applicable to the target population, and demonstrating overall consistency of results; or</p> <p>Extrapolated evidence from studies rated as 1++ or 1+</p>
C	<p>A body of evidence including studies rated as 2+, directly applicable to the target population and demonstrating overall consistency of results; or</p> <p>Extrapolated evidence from studies rated as 2++</p>
D	<p>A body of evidence rated level 3 or 4; or</p> <p>Extrapolated evidence from studies rated as 2+</p>
	<p>Good practice points</p> <p>Recommended best practice based on the clinical experience of the guideline development group</p>

Source: SIGN 50 Guideline Developer's Handbook. NHS Scottish Intercollegiate Guidelines Network, 2014

Key recommendations

Key recommendations

Key recommendations are based on the results of the literature review and the experience of the guideline development group. The recommendations in this table are not arranged according to importance but rather in the order they occur in the main body of the document.

Box 1				
Key recommendations	Strength of recommendation	Level of evidence	Key references	
EB is a lifelong disorder that requires specialist intervention and consideration to minimise complications and improve quality of life. Ideally, management should take place in a specialised centre by a multi-disciplinary team	D	4	Badger, O'Haver et al, 2013; Denyer 2009; Pope, Lara-Corrales et al, 2012; Pillay 2008, El, Zambruno et al, 2014	
In severe EB the individual's ability to heal can be compromised by malnutrition, anaemia, pruritus and pain, and should be treated appropriately	D	4	Badger, O'Haver et al, 2013; El, Zambruno et al, 2014; Lara-Corrales, Arbuckle et al, 2010; Mellerio 2010; Pope, Lara-Corrales et al, 2012; Schober-Flores 2003; Pope, Lara-Corrales et al, 2013	
Careful skin and wound assessment should be undertaken regularly. Management must be tailored to both the type of EB and wound characteristics	D	4	Badger, O'Haver et al, 2013; Denyer 2009; Denyer 2010; Elluru, Contreras et al, 2013; Pope, Lara-Corrales et al, 2012; Pope, Lara-Corrales et al, 2013; Schober-Flores 2003; Sibbald, Zuker et al, 2005; El, Zambruno et al, 2014	
Atraumatic dressings should be used to prevent further blistering, skin and wound bed damage	D	4	Abercrombie, Mather et al, 2008; Badger, O'Haver et al, 2013; Denyer 2009; Denyer 2000; Denyer 2010; El, Zambruno et al, 2014; Kirkorian, Weitz et al, 2014; Lara-Corrales, Arbuckle et al, 2010; Mellerio, Weiner et al, 2007; Pillay 2008; Pope, Lara-Corrales et al, 2012; Elluru, Contreras et al, 2013; Gonzalez 2013	
People with EB and their carers are experts in the management of their condition and their involvement is paramount	D	4	Badger, O'Haver et al, 2013; Pope, Lara-Corrales et al, 2012; van, Lettinga et al, 2008	
The choice of wound management strategies should balance efficacy, patient choice and quality of life with cost-effectiveness	D	3,4	Kirkorian, Weitz et al, 2014; Sibbald, Zuker et al, 2005; Stevens 2014	
Staff caring for EB patients must be trained in specific handling techniques to avoid further harm	D	4	Gonzalez 2013	
Blisters are not self-limiting and intact blisters should be lanced and drained	D	4	Denyer 2009; El, Zambruno et al, 2014; Elluru, Contreras et al, 2013; Lara-Corrales, Arbuckle et al, 2010; Pillay 2008; Herod, Denyer et al, 2002; Schober-Flores 2003; Pope, Lara-Corrales et al, 2012	
Management of EB wounds must address issues such as critical colonisation, infection, and protection from trauma	D	4	Badger, O'Haver et al, 2013; Denyer 2009; Denyer 2010; El, Zambruno et al, 2014; Mellerio, Weiner et al, 2007; Schober-Flores 2003; Sibbald, Zuker et al, 2005; Azizkhan, Denyer et al, 2007	

Every effort should be made to treat the intense pruritus seen in EB and thereby minimise scratching that leads to further skin damage	C	2+4	Badger, O'Haver et al, 2013; Danial, Adeduntan et al, 2015a; Danial, Adeduntan et al, 2015b; El, Zambruno et al, 2014; Pillay 2008; Pope, Lara-Corrales et al, 2013; Snauwaert, Morren et al, 2011; Snauwaert, Yuen et al, 2014
Silicone medical adhesive removers (SMARS) should be used when removing adherent dressings or clothing	D	3,4	Denyer 2009; Denyer 2010; El, Zambruno et al, 2014; Lara-Corrales, Arbuckle et al, 2010; Mather and Denyer 2008; Stephen-Haynes 2008
To ensure adequate nutrition and optimise wound healing long-term, enteral feeding may be indicated in severe EB	D	4	El, Zambruno et al, 2014; Haynes 2010; Haynes, Mellerio et al, 2012; Hubbard, Haynes et al, 2011; Pope, Lara-Corrales et al, 2012
Optimal pain management is vital for patients with all forms of EB and include pharmacological and non-pharmacological interventions	D	4	Denyer 2009; Denyer 2010; El, Zambruno et al, 2014; Goldschneider and Lucky 2010; Herod, Denyer et al, 2002; Wattersson, Howard et al, 2004; Mellerio, Weiner et al, 2007; Goldschneider, Good et al, 2014
When a surgical or interventional procedure is indicated adjustments to anaesthesia and theatre protocols will be required to minimise skin damage and protect the airway	D	4	El, Zambruno et al, 2014; Elluru, Contreras et al, 2013; Herod, Denyer et al, 2002; Goldschneider, Lucky et al, 2010
The principles of wound bed preparation (WBP) are applicable to wounds seen in patients with EB, particularly wounds which have become chronic	D	4	Lara-Corrales, Arbuckle et al, 2010; Pope, Lara-Corrales et al, 2012; Mellerio, Weiner et al, 2007; Pope, Lara-Corrales et al, 2013; Sibbald, Elliott et al, 2015
In patients with severe forms of EB there is a high risk of squamous cell carcinoma (SCC). Regular monitoring is essential with a low threshold for biopsy of suspect areas.*	D	4	Fine, Johnson et al, 2009; Mellerio, Weiner et al, 2007; Mellerio, Robertson et al, 2016

* Although the evidence supplied by the US EB Registry (Fine, Johnson et al, 2009) supported by a subsequent review in 2016 (Montaudie, Chiaverini et al, 2016) for the high risk of SCC in severe forms of EB most notably RDEB-GS is unequivocal and are graded C -2+, the evidence for recommended actions are based on expert opinion.

Evidence for wound management strategies

Box 2: Evidence for the use of specific wound management strategies					
Wound management strategy	Comments	Strength of recommendation	Level of evidence	References	
Soft silicone dressings	No evaluation of products but widely used and accepted in the management of EB	D	4	Abercrombie, Mather et al, 2008; Badger, O'Haver et al, 2013; Denyer 2009; Denyer 2010; El, Zambruno et al, 2014; Kirkorian, Weitz et al, 2014; Lara-Corrales, Arbuckle et al, 2010; Mellerio, Weiner et al, 2007; Pillay 2008; Pope, Lara-Corrales et al, 2012	
Polymeric membrane	Limited patient numbers and case study evidence	D	3	Stevens 2010; Pillay 2009; Denyer 2009; Clapham 2011; Denyer, Foster & Turner 2013; Bauer, Diem & Ploder 2013; Carbone, Gonclaves, Grandi & Desbordes 2013; Denyer, Foster & Turner 2013	
Honey	Single patient case study with complete healing of a recalcitrant wound unresponsive to previous interventions	D	3	Hon, 2005	
Saltwater baths to reduce pain	2010 paper expert opinion. 2015 retrospective observational study 21 patients showing substantially reduced pain and some reduction in other wound related symptoms	C	2+, √	Arbuckle, 2010; Petersen, Arbuckle et al, 2015	
Lipido-collloid dressings	Blanchet-Bardon 2005 included 20 patients with a variety of forms of EB and reported improved quality of life and healing as did Stevens reporting on 2 patients	D	3	Blanchet-Bardon and Bohbot 2005; Blanchet-Bardon and Bohbot 2007; Stevens 2009	
*Biological dressings including cadaveric allografts, amniotic membrane, cord blood platelet gel, cultured keratinocyte allografts, type 1 collagen skin substitute, non-biological skin substitutes	Many interventions had small patient numbers or were single case studies apart from some artificial skin substitute studies that had larger numbers. All reported improved healing and/or reduction in wound related symptoms. McGrath using cultured keratinocyte allografts reported little clinical benefit	C,D	2+, 3	Buonocore and Ariyan 2009; Hasegawa, Mizoguchi et al, 2007; Sibbald, Zuker et al, 2005; Falabella, Valencia et al, 2000; Lo, Lara-Corrales et al, 2010; Ng, Nguyen et al, 2014; Tadini, Pezzanti et al, 2015; McGrath, Schofield et al, 1993; Fivenson, Scherschun et al, 2003; Gorelli, Leung et al, 2015	

Keratin gel	Denyer variety of forms of generalised EB (n=10) 6 reported faster healing. 2 gel was ineffective and 2 reported increased pruritus. Kirsner (n=1) improved healing. Than (n=1) improved healing. In cases where healing reported faster treated areas said to be more robust	D	3	Denyer, Marsh et al, 2015; Kirsner, Cassidy et al, 2012; Than, Smith et al, 2013
*Botulinum toxin in EBS	In a case series of patients with EBS (n=6) 5 reported some improvement in global foot related symptoms	D	2+	Swartling, Karlqvist et al, 2010
*Systemic G-CSF	Pilot trial in DEB (n=7) 7 showed reduction in wound size and blister/erosion frequency	C	2+	Fine, Manes et al, 2015
*Ablative fractional resurfacing	Single patient case study treatment of a chronic wound leading to almost complete healing at 8 weeks	D	3	Krakowski and Ghasri 2015
Systemic trimethoprim	RDEB patients (n=7) with 42 wounds. Prospective, randomised, double-blind, placebo-controlled crossover trial. 6 of 7 patients showed greater than 50% reduction in chronic wound size. In the control group 2 of 7 patients showed a similar result. Limited by small sample size	C	2+	Lara-Corrales, Parkin et al, 2012
*Topical gentian violet in Non-H JEB	EBS-DM (n=5) randomised controlled pilot study with reported reduction in blistering. Limitation small sample size	D	2+	Wally, Kitzmueller et al, 2013
*Punch grafting in Non-H JEB	Retrospective analysis of punch grafting (n=4) with 23 ulcers. Complete healing in 16 lesions, 7 improved and at 3 months 2 had recurred	D	3	Yuen, Huizinga et al, 2013
*Oral epigallocatechin-3-gallate	RDEB (n=16). Randomised, crossover, double-blind, placebo trial. Findings were improvement in healing and reduction in blisters but results did not achieve statistical significance	C	2+	Chiaverini, Roger et al, 2016
Thalidomide	RDEB-P (n=2). Two patients showed reduction in pruritus and improved healing	D	3	Ranugha, Mohanan et al, 2014
Piscean collagen	D: Limited case study evidence of improved healing	D	3	Westgate S et al, 2012
* Not used by guideline development group . Recommendation based on published evidence				

Special considerations

Box 3: Key recommendations for management of neonates			
Key recommendations	Strength of recommendations	Level of evidence	Key references
Ideally an outreach service should be offered for severely affected neonates. Where this is not possible infants should be transferred in appropriate dressings and clothing, and in a padded car seat rather than a portable incubator if local policy permits	D	4	Denyer 2009
Advice should be sought from a paediatric pain specialist to enable adequate analgesia for procedural and chronic multi-factorial pain	D	4	Goldschneider and Lucky 2010 Goldschneider, Good et al, 2014 Herod, Denyer et al, 2002 Weiner 2004 Morash and Fowler 2004
Infant to be nursed on neonatal mattress, and staff and family trained in specific handling to avoid trauma	D	4	Denyer 2009
Limbs and vulnerable areas should be protected with suitable dressing material to reduce skin loss from baby movements such as kicking	D	4	Denyer 2009
Secure umbilical cord with a ligature rather than a cord clamp	D	4	Denyer et al 2014
Use greasy emollient such as 50% liquid/50% white soft paraffin to cleanse napkin area in preference to water	D	4	Denyer 2009 Denyer et al, 2014
Line the napkin with a liner, a continence cloth, such as Conticloth or a piece of muslin or fleece cloth, to prevent friction and subsequent trauma from the edges	D	4	Denyer 2009
Avoid bathing until inter-uterine and birth damage have healed	D	4	Denyer and Stevens 2010

BOX 4: Additional recommendations for the care of neonates with severe EB

Procedure	Rationale
Remove from incubator unless prescribed for other medical condition such as prematurity	Heat and humidity exacerbate blistering
Remove cord clamp and replace with ligature	To prevent trauma to umbilical area
Line nappy with soft material	To prevent blistering at edges of nappy
Cleanse nappy area with 50% liquid/50% white soft paraffin in ointment or spray (Emollin) form	To ensure cleansing without trauma. To reduce pain
Delay bathing until prenatal and birth trauma have healed	To avoid damage from infant being handled naked
Nurse on neonatal incubator mattress	To enable infant to be lifted on mattress and avoid shearing forces from carer's hands
Use long soft teat such as lamb's teat or a Haberman (specialist needs feeder)	To avoid friction damage to underside of nose and oral mucosa
Apply teething gel to teat (use a preparation that is safe to use from birth)	To alleviate pain from blistered mucosa
Avoid heel prick for neonatal blood screening — obtain blood via venepuncture	To avoid de-gloving injury

Understanding epidermolysis bullosa



Key recommendations are highlighted in blue throughout the text and references can be found in Appendix 1

EB describes a rare complex group of inherited skin fragility disorders. Ideally patients should be managed in a specialist centre. EB is a lifelong disorder that requires specialist intervention and considerations to minimise complications and improve quality of life.

The most recent classification for EB, agreed in 2014, names four categories of the condition defined by the level of cleavage at the dermal/epidermal junction (Fine, Bruckner-Tuderman et al, 2014). These are:

- EB simplex (EBS)
- Junctional EB (JEB)
- Dystrophic EB (DEB)
- Kindler syndrome.

The common factor in all types of EB is the tendency for skin and mucous membranes to blister or shear away in response to minimal everyday friction and trauma.

The severity of EB varies from simple blistering affecting the hands and feet, particularly in warm weather, to death in early infancy from the devastating combination of laryngeal disease and failure to thrive. Those with DEB develop microstomia and oesophageal strictures as a result of contractures and scarring.

People with more severe forms of EB can experience recurrent blistering and skin loss. There is also a tendency to develop chronic wounds resulting from the underlying gene defect, compromised nutrition, chronic anaemia and repeated infection, together with constant trauma.

Non-cutaneous complications, such as anaemia due to iron deficiency and chronic disease, osteoporosis, growth failure and pubertal delay (Haynes 2010) further compromise wellbeing. There is also a greatly increased risk of aggressive squamous cell carcinoma in those with severe forms of EB (Mellerio, Robertson et al, 2016).

ASSESSMENT AND DIAGNOSIS

Within each of the four categories of EB there are subtypes that display individual clinical effects (see pages 13–15). Definitive diagnosis is most commonly made from analysis of a skin biopsy using positive immunofluorescence (IF), antigenic mapping and transmission electron microscopy. These key diagnostic tools help confirm diagnosis and indicate the particular subtype of EB (Uitto, Richard et al, 2007).

Identification of the different causative genes responsible for EB enables the recognition of the precise location of and type of mutation. Due to the rarity of expertise and facilities, however, diagnosis is generally made using IF and antigen mapping. Some laboratories are moving towards molecular diagnosis from exome sequencing of a panel of known skin fragility genes.

Pre-implantation genetic diagnosis or first trimester DNA-based prenatal diagnosis from chorionic villus samples or amniocentesis can be offered to families in which causative mutations or informative genetic markers have been identified. Experienced clinicians can often make a provisional diagnosis on clinical observations, but a definitive diagnosis will always be required, particularly in neonates where a clear diagnosis is crucial to ensure correct management.

CAUSES OF EB

EB can be inherited autosomal recessively or autosomal dominantly; in general, recessive forms tend to be more severe. More than 1,000 recorded mutations in 14 genes contribute to the various forms of EB, resulting in a huge variety of clinical presentations (Fine, Bruckner-Tuderman et al, 2014).

These guidelines outline each main subtype and focus on the different skin and wound management requirements, as well as general principles for wound management for all types of EB.

EB SIMPLEX

Almost all forms of EB Simplex (EBS) are inherited autosomal dominantly, although some rare forms are recessively inherited. EBS is a disorder of keratin proteins with the primary defects lying within proteins encoding for keratin 5 and keratin 14. These proteins form the keratin scaffolding within the basal epidermal cells.

Dysfunction of the keratin proteins in EBS leads to mechanical weakness of these cells; breakdown occurs due to minor friction or rubbing resulting in blistering (Uitto, Richard et al, 2007).

All forms of EBS are most troublesome in hot and humid environments due to an increase in sweat production, which exacerbates frictional forces.

The three main types of EBS are classified as basal EBS:

- EBS localised (EBS-loc; previously called Weber-Cockayne) — primarily affects the hands and feet with blisters arising from friction or spontaneously when the environment is hot or humid
- EBS generalised intermediate (EBS-GI; previously called Köbner), — causes more widespread blistering at an earlier onset with blisters and skin loss frequently present at birth. Blistering persists throughout life but becomes less troublesome, with the main problematic areas being the hands, feet and where clothing causes friction
- EBS generalised severe (EBS-GS; previously called Dowling-Meara) — a more serious type of EBS and can be severe in the neonatal period. There is a significant risk of death in this age group resulting from sepsis and laryngeal blistering. Blisters typically occur in clusters and often beneath and around nails and in the mouth. Blistering tends to reduce late in childhood and hyperkeratosis develops over the palms and soles.

Additional rare basal subtypes are:

- EBS with mottled pigmentation (EBS-MP)
- EBS migratory circinate (EBS-migr)
- EBS autosomal recessive K14 (EBS-AR K14)
- EBS with muscular dystrophy (EBS-MD)
- EBS with pyloric atresia (EBS-PA)
- EBS Ogna (EBS-Og)
- EBS autosomal recessive BP230 deficiency (EBS-AR BP230)
- EBS autosomal recessive exophilin deficiency (EBS-AR exophilin 5).

EBS with muscular dystrophy is a form of autosomal recessive EBS that results from mutations in the gene encoding plectin (PLEC1). Plectin plays an important part in both skin and muscles, helping to maintain mechanical function. While skin involvement may be minimal, laryngeal involvement can be severe and the patient may require a tracheostomy. Progressive muscular dystrophy commonly starts any time from the first year onwards.

Suprabasal types of EBS are rare and include:

- Acral peeling skin syndrome (APSS)
- EBS superficialis (EBSS)
- Acantholytic EBS (EBS-acanth)
- Desmoplakin deficiency (EBS-desmoplakin) [associated cardio-myopathy]
- Plakoglobin deficiency (EBS-plakoglobin)
- Plakophilin deficiency (EBS-plakophilin).

JUNCTIONAL EB

Junctional EB (JEB) is a group of autosomal recessively inherited disorders, which are characterised by mechanically induced blistering at the *lamina lucida* level of the basement membrane zone, between the basal cells and *lamina densa*. All forms of JEB arise from mutations in genes that encode structural components of the hemidesmosomes or anchoring filaments, which provide mechanical integrity across this zone. Separation of the epithelium occurs within the *lamina lucida* between the *lamina densa* of the basement membrane and the basal keratinocytes.

There are three main forms of junctional EB:

- JEB generalised severe (JEB-GS previously called Herlitz junctional EB)
- JEB generalised intermediate (JEB-GI previously called Non-Herlitz junctional EB)
- JEB with pyloric atresia (JEB-PA).

In all forms of JEB, the most problematic wounds occur on the scalp and lower legs. Open nail beds and facial lesions occur in JEB generalised severe (JEB-GS). There is a tendency for chronic wounds to develop and a particular feature is for wounds to over-granulate from an early age. Common features include hypoplastic dental enamel, alopecia and genito-urinary tract involvement in longer-term patients (Fine 2010).

JEB generalised severe

In JEB-GS the protein laminin 332 is absent or greatly reduced. Laminin 332 is a major component of the basement membrane zone, providing anchorage across the *lamina lucida* (Nakano, Chao et al, 2002). For the vast majority, this type of EB carries a very poor prognosis with most not surviving beyond the first two years of life. Death results from a combination of laryngeal blistering/respiratory distress, a profound and uncorrectable failure to thrive, chronic wounds and sepsis (Fine, 2010). Despite the severity of the systemic disease, good management can help reduce the severity of the wounds.

JEB generalised intermediate

The majority of JEB-GI cases result from mutations in the genes encoding type XVII collagen or laminin 332, which are expressed in skin and other sites such as the urogenital tract. This protein has an important function and plays a major role in the anchorage of the epidermis to the dermis. Type XVII collagen is expressed in the skin, oral mucosa, the cornea, upper oesophagus and bladder epithelium (Van and Giudice, 2003).

JEB-GI carries a better prognosis than JEB-GS, with the majority of patients surviving to adulthood, but there is an increased risk (up to 25%) of developing a squamous cell carcinoma (SCC) after the age of 25 (Fine, Johnson et al, 2009).

Chronic wounds may remain a lifelong problem and areas of previous wounding can become atrophied. Nail dystrophy and scarring alopecia are common in older patients. Dental enamel defects in this subtype of EB are characteristic and a useful diagnostic pointer.

JEB with pyloric atresia

This is associated with pyloric atresia and is a rare subtype of JEB that results from mutations in the alpha-6-beta-4 integrin genes. This integrin is an important component of the hemidesmosomes and is found in skin and other epithelia including the gastrointestinal and urogenital tracts. JEB-PA frequently has a poor prognosis despite surgical correction of the atresia.

Many patients die in infancy, while milder phenotypes exhibit outcomes similar to those with JEB-GI. However, significant morbidity from urogenital tract involvement is frequently seen in those with this type of EB.

Other rare types of JEB

- JEB late onset (JEB-LO)
- JEB with respiratory and renal involvement (JEB-RR)
- JEB localised (JEB-loc)
- JEB inversa (JEB-I)
- Laryngo cutaneous syndrome (JEB-LOC syndrome; previously called Shabbir's syndrome).

DYSTROPHIC EB

EB can be inherited either dominantly or recessively, with the more severe forms in general being inherited recessively. In all cases there is a diminished or absent protein collagen VII, which is a crucial component of anchoring fibrils. Anchoring fibrils act rather like Velcro® hooks attaching the epidermis to the dermis. In DEB, separation occurs at the sub-*lamina densa* of the basement membrane zone.

The extent of skin fragility is extremely varied depending on whether the causative mutation predisposes to mild or severe disease and whether the affected individual has completely absent or reduced collagen VII.

In severe forms of DEB there are many complications, which have an impact on the individual's ability to heal and these should be addressed and corrected where possible. Common complications are malnutrition, anaemia, recalcitrant pruritus, pain, infection and critical colonisation (see page 20).





Types of dystrophic EB

Dominant dystrophic EB

Dominant dystrophic EB (DDEB) has autosomal dominant inheritance. Blistering can be localised to areas particularly subject to trauma such as the hands, feet, knees and elbows, or more generalised. Healing is usually accompanied by some scarring and milia are often present. Mucous membranes, particularly of the mouth and the anal margins, can be fragile leading to difficulties with eating and constipation.

Types of DDEB

- DDEB generalised (DDEB-gen)
- DDEB acral (DDEB-ac)
- DDEB pretibial (DDEB-pt)
- DDEB *pruriginosa* (DDEB-pr)
- DDEB nails only (DDEB-na)
- DDEB bullous dermolysis of the newborn (DDEB-BDN).

Recessive dystrophic EB (RDEB)

- RDEB generalized severe (RDEB-GS)
- RDEB generalised intermediate (RDEB-GI)
- RDEB bullous dermolysis of the newborn (RDEB-BDN)
- RDEB inversa (RDEB-I)
- RDEB localised (RDEB-loc)
- RDEB pretibial (RDEB-pt)
- RDEB *pruriginosa* (RDEB-pr)
- RDEB centripetalis (RDEB-ce).

Recessive dystrophic EB — generalised severe

In RDEB-GS the skin is extremely fragile, often with extensive blistering and wounding. Patients with this form of EB will frequently develop hard-to-heal or never-to-heal areas, or areas that do heal but can very quickly break down. Atrophic scarring and healing leading to disabling contractures are common. Pseudosyndactyly (see pages 21–22) is often present and may require repeated surgery (Formsma, Maathuis et al, 2008; Bernardis and Box 2010). Severe pain, nutritional compromise and profoundly difficult-to-correct anaemia will all impact negatively on wound healing. Recalcitrant pruritus can lead to destructive scratching and disruption to wound healing.

Recessive dystrophic EB — generalised intermediate

RDEB-GI has an autosomal recessive inheritance. Generally, the affected individual is able to express some type VII collagen, with variable qualitative and quantitative abnormalities of the anchoring fibrils. The clinical presentation will vary with a tendency for generalised blistering and consequent wounding. The development of anaemia is common with this type of EB and there is often mucosal involvement. The hands will be scarred with some webbing, but full pseudosyndactyly is not seen in RDEB-GI.

Dystrophic EB *pruriginosa*

DEB-pr can be inherited by dominant or recessive transmission. Patients will experience the skin fragility already described above, but will also exhibit intense pruritus, which is exceptionally difficult to manage. Scratching and skin breakdown can lead to the formation of disfiguring linear scarring in some patients, which appears almost like keloid scarring. Other patients will have extensive blistering and skin breakdown.

Recessive dystrophic EB inversa (RDEB-I)

RDEB-I may be recessive or, less commonly, dominant. The majority of wounds develop in the flexures such as neck, groin and axillae. Hands become scarred but do not progress to mitten deformity. Oesophageal strictures are problematic in this group and may be particularly severe.

KINDLER SYNDROME

Kindler syndrome is an autosomal recessive disorder caused by mutations in the FERMT1 gene. It is rare, difficult to diagnose and is often confused with other subtypes of EB. Blistering, epidermal atrophy and delayed healing result from FERMT1 gene mutations. Trauma-induced skin blisters occur in early life and are prevalent together with skin loss and wounding during the neonatal period.

The blistering reduces in infancy but over time photosensitivity and signs of poikiloderma (a skin condition characterised by pigmentary and atrophic changes) develop where the skin takes on a mottled appearance (Lai-Cheong and McGrath, 2010; Lai-Cheong and McGrath, 2011).

Other clinical features include periodontitis, oesophageal strictures, malabsorption and diarrhoea in early life, and urethral strictures. There is also an increased risk of mucocutaneous SCC in later life (Fine, Johnson et al. 2009).

In Kindler syndrome the family fermitin homolog 1 is typically markedly reduced or absent within the epidermis and at the dermal—epidermal junction. Unlike all other types of EB, the level of cleavage is variable, with blister formation taking place within the epidermis, *lamina lucida* or beneath the *lamina densa*, thus explaining the variable features demonstrated in Kindler syndrome.

Skin and wound management: general principles

All types of EB are characterised by fragile skin and a range of cutaneous involvement from blistering, primarily on the hands and feet, through to more generalised wounding. The presence of multiple wounds of varying duration and ability to heal makes management of EB difficult and complex.

Careful skin and wound assessment should be undertaken regularly. Management must be tailored to suit both the type of EB and the specific characteristics of the wound.



QE Level 4



The underlying principle of lesion management is to apply an atraumatic dressing to prevent blistering, and skin and wound bed damage leading to pain and bleeding on removal.

People with EB and their carers are experts in the management of their condition and their involvement in their care is paramount.

It is important to listen to the patient and/or carer as many people with EB will have a tried and tested dressing regimen that avoids injury. For example, they may use soft padding to prevent blistering from the edges of a dressing or apply bandaging in a certain way to reduce the risk of contractures. These dressing techniques will have been developed over years of living with EB and many techniques will be atypical.

Careful discussion will usually reveal the reasons why patients use products in a particular way and the clinician should be prepared to be open-minded. In countries where suitable dressings are not available, dressings can often be modified or alternative materials used (Table 17, page 38). In addition, clinicians need to educate patients about wound management and inform them of new products as they appear on the market.



QE Level 4



The choice of wound management strategies should balance efficacy, patient choice and quality of life with cost effectiveness.

Staff caring for EB patients must be trained in specific handling techniques to avoid causing harm.

Healthcare settings are fraught with danger for the EB patient as routine procedures, such as the use of a PATSLIDE® to move a patient or removal of ECG electrodes, can result in extensive skin loss. Care must be taken not to cause further injury (Gonzalez, 2013) (Table 8, page 28).

MANAGEMENT OF BLISTERS

Blisters occur in all types of EB following friction and relatively minor trauma. They can be present anywhere on the skin and also on the mucous membranes.



QE Level 4



Blisters are not self-limiting and will extend rapidly if left unchecked.

In contrast to recommendations for other dermatological conditions or wound management, intact blisters should be lanced at their lowest point to limit tissue damage (Denyer 2010). A fresh hypodermic needle should be used or, if this is not available, a sterilised sewing needle. The needle should be passed through the blister roof, parallel to the skin, to create an entry and exit hole through which fluid can be expelled (Figure 2, page 18).

A soft piece of material, such as gauze, can be used to gently compress the blister to encourage complete emptying. If this compression is painful, a syringe can be attached to the needle to aspirate the fluid.

Some patients advocate using sterilised scissors or a scalpel blade to create a larger hole to prevent the blister from refilling. The roof should be left on the blister unless personal preference is to deroof it to prevent refilling, but deroofing can lead to additional pain and should be discouraged if possible.

The location of a particular blister may be EB-type specific. For example EBS localised will occur mainly on the hands and feet (Figure 1, page 18) whereas mild forms of dystrophic EB will occur on the areas subject to the most trauma, such as the bony prominences. The blisters can occur alone or in clusters depending on the initial degree of trauma and they may be filled with serous or blood-stained fluid.

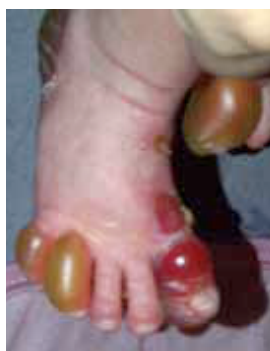

Figure 1. Blisters on toes in patient with EBS

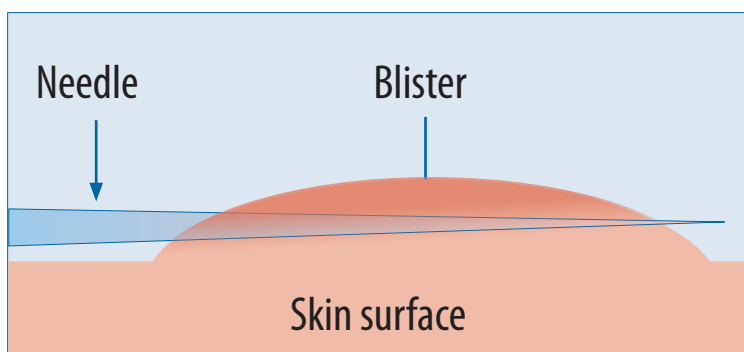


Figure 2. Recommended method of blister lancing. Used with permission from Birmingham Children's Hospital

SKIN AND WOUND MANAGEMENT

Dressings listed have been tried and found suitable for use on skin and wounds of children and adults with EB. Where 'preferred choice' is indicated this should be selected if available. A wide range is included to offer selection to those with a limited formulary. Dressings within tables are listed in order of their suitability.

MANAGEMENT OF EB SIMPLEX

Dressing management in EB Simplex (EBS) focuses on preventing infection, cooling the blister sites and protecting the skin from trauma. However, observation within the authors' large caseloads indicates many patients prefer to leave blisters undressed.

Dressings can lead to overheating which increases the tendency to blister as sweating increases friction. The patient may also blister around the edge of dressings on areas subject to great pressure such as the feet. Dressings and padding on the feet may make it impossible to wear shoes and dressings on the hands may hamper the patient's dexterity. For information on recommended wound dressings see Table 1. For further information on the podiatric management of EBS see *Podiatric Management of EB* (Khan 2010).

The most effective management is lancing the blisters (Laimer, Lanschuetzer et al, 2010). For patients who dislike dressings or find they exacerbate the blister sites, commercial cornflour (corn starch) may be used to dry up the blistered areas and provide a low friction surface. Silk socks or Skinnies WEB socks can help to reduce friction and are seam free (Grocott, Blackwell et al, 2013). Clinical experience also suggests that silver socks may help to keep feet cool (Denyer 2010).

EBS-GS needs specific management as any dressing materials have the potential to create blisters around the edges of the dressing (Table 2, page 20).



Neonates may present at birth with widespread skin loss and although dressings are required, measures must be taken to protect the skin around the dressing. Once the wounds are healed dressings are not used for protection in view of the resulting damage. A thin layer of equal parts of white soft and liquid paraffin can reduce friction and soft seam-free clothing offers protection (Denyer 2009).

MANAGEMENT OF JUNCTIONAL EB



Wound management in Junctional EB (JEB) is focused on managing chronic wounds and excessive granulation tissue (Table 3, page 21).

Open nail beds, and the umbilical and nappy area all pose particular challenges in infants with JEB-GS. Use of very potent topical steroid ointments greatly reduces over-granulation and may encourage healing.

From the authors' experience, a soft silicone mesh has a tendency to encourage over-granulation even to the extent where the tissue grows through the mesh and forms a bridge over the dressing.

SELECTING AND USING A DRESSING

There are number of considerations when selecting an appropriate dressing, including:

Wear time

Most dressings recommended in this document should be changed every 1-3 days unless

- Patient/carer preference differs
- Otherwise stated by the manufacturer
- Levels of exudate dictate more frequent change as does wound infection or if there is obvious strikethrough.

It is important to ensure that there are no folds or creases in the dressing that would result in blistering and further damage to the skin.

Removal dressings

Dressings must be removed with great care to avoid further skin damage. If necessary the dressing can be soaked off in the bath, hydrated with tepid water or saline or a silicone medical adhesive remover (SMAR) could be used. In particular this applies to patients with RDEB or those using a bordered dressing.

Sensitivity

Any sensitivity to components of a particular dressing should be established prior to use. Silicone sensitivity resulting from impurities in the silicone is rare but has been reported.

Table 1: Recommended dressings for EBS localised and generalised ✓

Preferred choice when available: blister sites — Spycra Protect (ReSkin/Bullen healthcare) or Kerralite Cool (Crawford Healthcare)

Dressing type	Brand	Manufacturer	Indication/function	Contraindication/comments
Bi-stretch soft silicone	<ul style="list-style-type: none"> • Spycra Protect 	<ul style="list-style-type: none"> • ReSkin/Bullen Healthcare/ Curea Medical 	<ul style="list-style-type: none"> • Protection • Minor blister sites and non-exudating wounds 	
Sheet hydrogel	<ul style="list-style-type: none"> • Kerralite Cool/ Kerralite Cool Border • ActiFormCool 	<ul style="list-style-type: none"> • Crawford Healthcare • L&R 	<ul style="list-style-type: none"> • Blister sites • Cooling • Pain reduction 	<ul style="list-style-type: none"> • Keep backing on to keep moist for longer • ActiFormCool — rarely pain reactions are reported
Bordered foam dressing	<ul style="list-style-type: none"> • Mepilex Border/ Border Lite • Biatain Silicone Lite • Allevyn Gentle Border • Allevyn Lite • Allevyn adhesive (non silicone) • UrgoTul Absorb Border 	<ul style="list-style-type: none"> • Mölnlycke Health Care • Coloplast • Smith & Nephew • Urgo Medical 	<ul style="list-style-type: none"> • Protection • Blister sites 	
Soft silicone mesh	<ul style="list-style-type: none"> • Mepitel • Mepitel One • Adaptic Touch • Cuticell Contact 	<ul style="list-style-type: none"> • Mölnlycke Health Care • Acelity • BSN Medical 	<ul style="list-style-type: none"> • Wound contact layer 	
Lipido-colloid	<ul style="list-style-type: none"> • UrgoTul 	<ul style="list-style-type: none"> • Urgo Medical 	<ul style="list-style-type: none"> • Wound contact layer 	<ul style="list-style-type: none"> • Alternative to soft silicone mesh
Hydrogel	<ul style="list-style-type: none"> • Intrasite Conformable 	<ul style="list-style-type: none"> • Smith & Nephew 	<ul style="list-style-type: none"> • Cooling • Pain reduction 	<ul style="list-style-type: none"> • Do not allow to dry out
Foam	<ul style="list-style-type: none"> • Mepilex • Mepilex Lite • Mepilex Transfer 	<ul style="list-style-type: none"> • Mölnlycke Health Care 	<ul style="list-style-type: none"> • Protection 	<ul style="list-style-type: none"> • May cause heat-related blistering • Soft silicone tape can be used with for fixation
Soft silicone fixation tape	<ul style="list-style-type: none"> • Siltape • Mepitac 	<ul style="list-style-type: none"> • Advancis Medical • Mölnlycke Health Care 	<ul style="list-style-type: none"> • Retention of non-bordered dressings 	
Fixation bandage	<ul style="list-style-type: none"> • CoFlex Haft • Soft-One • Acti-Wrap 	<ul style="list-style-type: none"> • Aspen Medical Europe • Snogg • L&R 	<ul style="list-style-type: none"> • Retention 	<ul style="list-style-type: none"> • Do not stretch bandage on application to avoid tourniquet effect
Powder	<ul style="list-style-type: none"> • Cornflour (corn starch) 	<ul style="list-style-type: none"> • Commercial 	<ul style="list-style-type: none"> • To aid drying of blister • Reduce friction 	<ul style="list-style-type: none"> • Apply following lancing of blisters • Do not use cornflour in nappy area where it will turn into a paste

Table 2: Recommended dressings for patients with EBS-GS				
<i>Preferred choice when available: Spycra Protect (ReSkin/Bullen Healthcare); Open wounds — PolyMem (Ferris Mfg Corp [Aspen Medical Europe, UK])</i>				
Dressing type	Brand	Manufacturer	Indication/function	Contraindication/comments
Bi-stretch protection	<ul style="list-style-type: none"> Spycra Protect 	<ul style="list-style-type: none"> ReSkin/Bullen Healthcare/ Curea Medical 	<ul style="list-style-type: none"> Protection Blister sites 	
Polymeric membrane	<ul style="list-style-type: none"> PolyMem 	<ul style="list-style-type: none"> Ferris Mfg Corp (Aspen Medical Europe, UK) 	<ul style="list-style-type: none"> Wounds present at birth 	<ul style="list-style-type: none"> Strips of a Hydrofiber dressing (see below) will need to be placed under the edges of the dressing to protect the skin Change when wet in small infants to avoid hypothermia (See Table 7, page 27)
Lipido-colloid	<ul style="list-style-type: none"> UrgoTul 	<ul style="list-style-type: none"> Urgo Medical 	<ul style="list-style-type: none"> Wound contact layer 	<ul style="list-style-type: none"> Use as a primary dressing if there is risk of adhesion
Hydrofiber	<ul style="list-style-type: none"> Durafiber Aquacel 	<ul style="list-style-type: none"> Smith & Nephew ConvaTec 	<ul style="list-style-type: none"> Protection from the edges of dressings (see above) 	<ul style="list-style-type: none"> Hydrate with water or saline to remove if necessary
Tubular bandage	<ul style="list-style-type: none"> Tubifast with 2-way stretch ActiFast 2-way stretch Comifast multi stretch 	<ul style="list-style-type: none"> Mölnlycke Health Care L&R Synergy Health 	<ul style="list-style-type: none"> Retention 	<ul style="list-style-type: none"> Available in a range of sizes for appropriate fit May need protection at edges to prevent blistering
Powder	<ul style="list-style-type: none"> Cornflour (cornstarch) 	<ul style="list-style-type: none"> Commercial 	<ul style="list-style-type: none"> To aid drying of blister Reduce friction 	<ul style="list-style-type: none"> Do not use in the nappy area where it will turn into a paste Apply following lancing of blisters



MANAGEMENT OF DYSTROPHIC EB

Management of dystrophic EB (DEB) must address critical colonisation and infection, offer protection from trauma, avoid contractures and reduce pruritus.



Dressings are often extensive and large sizes must be sought in order to avoid blistering where two smaller dressings join (Table 4, page 23). Exudate can be copious and needs careful containment to avoid maceration and leakage (see pages 34–35). Odour can be a feature and must be addressed to avoid embarrassment and social compromise although eradication can be impossible (see Table 18, page 40).

Practical approaches

If the skin is lacking in moisture it has a tendency to be more itchy. However, when treating pruritus in EB there has to be a balance between moisturising the skin without it becoming too soft and therefore more prone to blistering. Topical emollients, including moisturisers and bath oils are helpful.

Moisturisers containing sodium lauryl sulphate should be avoided as this can exacerbate skin damage (Kurgyis, Eros et al, 2013). Moisturisers that contain an antimicrobial agent such as benzalkonium chloride and chlorhexidine dihydrochloride, both found in Dermal™ products (Dermal Laboratories), have been reported to be helpful both in reducing itch and helping to reduce bacterial colonisation.

Other topical applications that may be useful include menthol in an oil-based product (such as Dermacool®, Pern Consumer Products). Topical steroids may be helpful for particularly acute severe itch. A modified

Table 3: Recommended dressings for patients with JEB

*Preferred choice of dressing when available:
 Infants and eroded blister sites — IntraSite Conformable
 Chronic or acute wounds — PolyMem with UrgoTul as the primary dressing
 Open nailbeds — Kytocel if bleeding; Mepitel One or Cuticell Contact with PolyMem as a secondary dressing if wet*

Dressing type	Brand	Manufacturer	Indication/function	Contraindication/comments	Wear time
Hydrogel impregnated gauze	▪ Intrasite Conformable	▪ Smith & Nephew	<ul style="list-style-type: none"> ▪ Eroded blister sites ▪ Neonates and infants 	<ul style="list-style-type: none"> ▪ Small neonates at risk of hypothermia as dressing is cooling ▪ May be used with topical morphine only when pain is difficult to control 	<ul style="list-style-type: none"> ▪ Change daily or when dry ▪ May need Urgotul as primary contact layer
Polymeric membrane	<ul style="list-style-type: none"> ▪ PolyMem ▪ PolyMem Max 	▪ Ferris Mfg Corp (Aspen Medical Europe, UK)	<ul style="list-style-type: none"> ▪ Chronic and acute wounds where cleansing is required 	<ul style="list-style-type: none"> ▪ Stimulates high levels of exudate — use barrier film to protect periwound skin if required ▪ Distinct smell does not necessarily indicate infection ▪ Can be difficult to retain on vertical surfaces 	<ul style="list-style-type: none"> ▪ As determined by exudate level ▪ Change frequently until exudate reduces
Lipido-colloid	▪ UrgoTul	▪ Urgo Medical	<ul style="list-style-type: none"> ▪ Wound contact layer 	<ul style="list-style-type: none"> ▪ Can be combined with an absorbant layer for moderately to heavily exuding wounds 	
Soft silicone mesh	<ul style="list-style-type: none"> ▪ Mepitel One ▪ Cuticell Contact ▪ Adaptic Touch 	<ul style="list-style-type: none"> ▪ Mölnlycke Health Care ▪ BSN Medical ▪ Acelity 	<ul style="list-style-type: none"> ▪ Soft silicone wound contact layer 		
Hydrofiber	<ul style="list-style-type: none"> ▪ Aquacel ▪ Durafiber 	<ul style="list-style-type: none"> ▪ ConvaTec ▪ Smith & Nephew 	<ul style="list-style-type: none"> ▪ Very moist wounds where it is difficult to keep dressing in place 	<ul style="list-style-type: none"> ▪ Lightly exuding or dry wounds 	<ul style="list-style-type: none"> ▪ Rehydrate with water or saline to remove, if necessary
Soft silicone foam	<ul style="list-style-type: none"> ▪ Mepilex ▪ Mepilex Lite ▪ Mepilex Transfer 	▪ Mölnlycke Health Care	<ul style="list-style-type: none"> ▪ Protection ▪ Absorption ▪ Excessive exudate 	<ul style="list-style-type: none"> ▪ May adhere if placed directly on wound bed, use an atraumatic contact layer 	
Soft silicone foam with super-absorbers	▪ Cutimed Siltec	▪ BSN medical	<ul style="list-style-type: none"> ▪ Protection ▪ Absorption ▪ Excessive exudate 	<ul style="list-style-type: none"> ▪ Can be cut between super-absorbent crystals 	

wet-wrap technique similar to that used for severe eczema may be helpful. It is important to cover the skin with a suitable primary dressing before applying the wet-wrap to avoid adherence.

As pruritus in EB is not mediated by histamine, antihistamines tend to be of limited value. However, the sedating effect of some antihistamines may be valuable in managing the urge to scratch, which can occur at night when there is little else to distract the patient. Other medications that have been used for severe recalcitrant itch include, gabapentin, amitriptyline, ondansetron, thalidomide and ciclosporin.



Management of pseudosyndactyly

Neonates with RDEB-GS are frequently born with wounds extending over their limbs, hands and feet, caused by intrauterine movement and delivery trauma. In many cases careful dressing of these wounds, with attention paid to separating the digits, can prevent early fusion (Denyer 2010).

De-gloving injuries are not uncommon following trauma and these also require immediate action to separate the digits to prevent digital fusion. Despite these measures, over time and following repeated trauma the web spaces are gradually lost and digital fusion and contractures will develop (Breitenbach, Gruber et al, 2012).

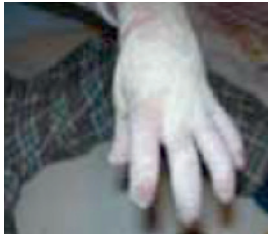

Figure 3: Full hand wrapping in a patient with RDEB-GS

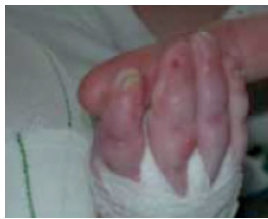

Figure 4: Modified hand wrapping to allow greater freedom of fingers (to be used in infants/toddlers for messy play and finger feeding). May be preferred by older children and adults



Silicone medical adhesive removers (SMAR) should be used when removing adherent dressings or clothing.

SMAR products enable adhesive materials to be used safely to secure intravenous cannulae, central lines and nasogastric tubes. In addition, accidental application of an adhesive product need not result in skin stripping (Figure 6). SMARs are available in sterile sachets and can be used for the face and around central lines (Denyer 2011). Spray presentations can be used in other areas.

GENERAL MANAGEMENT PRINCIPLES

In addition to the importance of monitoring the integrity of the skin and providing wound care, attention must also be paid to optimising nutrition and dental health, minimising deformity, and monitoring for ophthalmic complications and genitourinary problems (Fine, Johnson et al, 2004).

Abnormal bone health may also further compromise wellbeing and can lead to osteopenia, osteoporosis and fractures (Martinez and Mellerio, 2010). This is a multifactorial complication and causes may be due to lack of weight-bearing exercise, poor nutritional intake, abnormal biochemistry, pubertal delay and a generalised inflammatory state which leads to bone catabolism (Fine and Mellerio 2009).

Surgery is usually successful in releasing the contractures and separating the fingers, but this is complex and requires skin grafting, repeated general anaesthesia and compliance with post-surgical splinting. In many patients, the process of fusion and contractures begins again within a short time (Fine, Johnson et al, 2005). Some adult patients may refuse hand surgery because of the need for repeat procedures, preferring instead to manage with hands that may in some cases exhibit complete ‘mitten deformity’.

Hand wrapping using a soft conforming 2.5cm bandage that provides downward pull on the web spaces and around the palm, is useful in preventing the loss of web spaces by forcing down the skin (Figures 3, 4 and 5). In some children extending this technique to wrapping each finger individually has been successful in maintaining good results after surgery. Any open wounds or blister sites should be covered with a non-adherent dressing before wrapping and intact skin should be protected with a layer of greasy emollient.

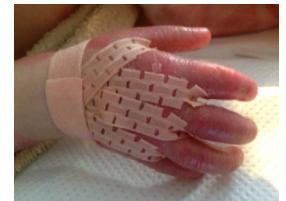

Figure 5: Using strips of dressing material (Spycra Protect) to preserve web spaces

MANAGEMENT OF KINDLER SYNDROME

The level of cleavage in Kindler syndrome is variable at an ultrastructural level, but this is not clinically relevant and does not affect how a patient may present, see Table 5 (Page 24) for the recommended dressings. The lancing of blisters is important in infants and the rate of blistering decreases with age. Application of high factor sun protection is essential from an early age.

WOUND DRESSING CONSIDERATIONS

Retention of dressings

Great care must be taken to ensure dressings do not slip, which can tear the fragile skin and cause adherence of existing wounds to clothing or bedding.

The retaining bandage or tape can also lead to additional blistering from movement or contact with the surrounding skin. Retention must allow for freedom of movement to discourage development of contractures in those with DEB. A range of EB-specific retention garments, Skinnies WEB™ have been developed with the aid of patients and carers (Grocott, Blackwell et al, 2013) (Table 6, page 25).

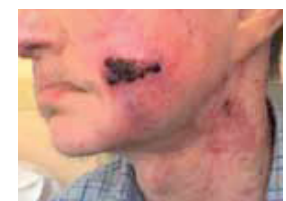

Figure 6: Skin loss following removal of soft silicone tape (without using SMAR)

Table 4: Recommended dressings for DEB

*First choice of dressing when available:
Chronic or acute wounds — PolyMem
Super-absorbent — Cutimed Siltec*

Dressing type	Brand	Manufacturer	Indication/function	Contraindication/ comments	Wear time
Polymeric membrane	<ul style="list-style-type: none"> ▪ PolyMem 	<ul style="list-style-type: none"> ▪ Ferris Mfg Corp (Apsen Medical Europe, UK) 	<ul style="list-style-type: none"> ▪ Where cleansing is required ▪ Chronic wounds 	<ul style="list-style-type: none"> ▪ Stimulates high levels of exudate ▪ Distinct smell does not necessarily indicate infection ▪ Can be difficult to retain on vertical surfaces 	<ul style="list-style-type: none"> ▪ Change frequently until exudate reduces
Super-absorbent dressings	<ul style="list-style-type: none"> ▪ Cutimed Siltec ▪ Sorbion Sachet S ▪ Flivasorb/Vliwasorb Pro ▪ Kerramax Care 	<ul style="list-style-type: none"> ▪ BSN Medical ▪ L&R ▪ Crawford Healthcare 	<ul style="list-style-type: none"> ▪ High exudate levels 	<ul style="list-style-type: none"> ▪ Can be cut between super-absorbent crystals, which appear in rows (as opposed to cutting across the crystal lattice) 	
Soft silicone mesh	<ul style="list-style-type: none"> ▪ Mepitel ▪ Mepitel One ▪ Adaptic Touch ▪ Cuticell Contact 	<ul style="list-style-type: none"> ▪ Mölnlycke Health Care ▪ Acelity ▪ BSN Medical 	<ul style="list-style-type: none"> ▪ Moist wound ▪ Contact layer 		
Lipido-colloid	<ul style="list-style-type: none"> ▪ UrgoTul 	<ul style="list-style-type: none"> ▪ Urgo Medical 	<ul style="list-style-type: none"> ▪ Moist wound, drier wounds and protection of vulnerable healed areas ▪ Use as an alternative to soft silicone (see above) in the presence of over-granulation 	<ul style="list-style-type: none"> ▪ Where retention is difficult (e.g. vertical surfaces) 	
Soft silicone foam	<ul style="list-style-type: none"> ▪ Mepilex ▪ Mepilex Lite ▪ Mepilex Transfer 	<ul style="list-style-type: none"> ▪ Mölnlycke Health Care 	<ul style="list-style-type: none"> ▪ Absorption of exudate ▪ Protection ▪ Lightly exuding wounds ▪ To transfer exudate to absorbent dressing ▪ Where conformability is required e.g. digits, axillae 	<ul style="list-style-type: none"> ▪ Over-heating ▪ May need to apply over recommended atraumatic primary dressing 	
Foam	<ul style="list-style-type: none"> ▪ Allevyn ▪ UrgoTul Absorb ▪ Aquacel Foam 	<ul style="list-style-type: none"> ▪ Smith & Nephew ▪ Urgo Medical ▪ ConvaTec 	<ul style="list-style-type: none"> ▪ Absorption and protection 	<ul style="list-style-type: none"> ▪ May adhere if placed directly on wound bed, use alternative contact layer 	
Bordered foam dressings	<ul style="list-style-type: none"> ▪ Mepilex Border/Meplix Border Lite ▪ Biatain Silicone Border/Biatain Border Lite ▪ Allevyn Gentle Border ▪ Allevyn Border Lite ▪ Kerrafoam ▪ UrgoTul Absorb Border 	<ul style="list-style-type: none"> ▪ Mölnlycke Health Care ▪ Coloplast ▪ Smith & Nephew ▪ Crawford Healthcare ▪ Urgo Medical 	<ul style="list-style-type: none"> ▪ Isolated wounds ▪ DDEB and mild RDEB 	<ul style="list-style-type: none"> ▪ Bordered dressings may require removal with SMAR to avoid skin stripping ▪ May require primary contact layer ▪ Poor absorption of highly viscous exudate 	<ul style="list-style-type: none"> ▪ Up to 4 days depending on personal choice
Keratin	<ul style="list-style-type: none"> ▪ keragel 	<ul style="list-style-type: none"> ▪ Keraplast (distributed by H&R Healthcare) 	<ul style="list-style-type: none"> ▪ Chronic wounds 	<ul style="list-style-type: none"> ▪ Dilute with bland emollient if stinging occurs 	<ul style="list-style-type: none"> ▪ Reapply with dressing changes



Nutritional support

To ensure adequate nutrition and optimise wound healing long-term enteral feeding in severe EB.

Nutrition may be compromised due to poor appetite, oral blistering and dysphagia (Colomb, Bourdon-Lannoy et al, 2012). In addition, vastly increased nutritional requirements are needed to compensate for losses and to aid wound healing (Haynes 2010, Hubbard, Haynes et al, 2011). Regular oesophageal dilations can temporarily improve swallowing when strictures present in patients with dystrophic EB (Azizkhan, Stehr et al, 2006; Spiliopoulos, Sabharwal et al, 2012).

For further advice on pain management see Pain care for patients with epidermolysis bullosa: best care practice guidelines. (Goldschneider, Good et al, 2014). Available via www.debra.international.com

Table 5: Recommended dressings for patients with Kindler syndrome* ✓

Dressing type	Brand	Manufacturer	Indication/function	Contraindication / comments	Wear time
Soft silicone mesh	<ul style="list-style-type: none"> Mepitel Adaptic Touch 	<ul style="list-style-type: none"> Mölnlycke Health Care Acelity 	<ul style="list-style-type: none"> Moist wound Suitable for most dry wounds 		<ul style="list-style-type: none"> Up to 4 days in neonates Older child/adult less likely to need such dressings but if used change in line with patient preference
Lipido-colloid	<ul style="list-style-type: none"> UrgoTul 	<ul style="list-style-type: none"> Urgo Medical 	<ul style="list-style-type: none"> Wound contact layer 		
Polymeric membrane	<ul style="list-style-type: none"> PolyMem 	<ul style="list-style-type: none"> Ferris Mfg Corp (Aspen Medical Europe, UK) 	<ul style="list-style-type: none"> Chronic and acute wounds Wounds where cleansing is required 	<ul style="list-style-type: none"> Stimulates high levels of exudate Distinct smell does not necessarily indicate infection Can be difficult to retain on vertical surfaces 	<ul style="list-style-type: none"> Change frequently until exudate reduces Protect periwound skin
Soft silicone foam	<ul style="list-style-type: none"> Mepilex/Mepilex Lite/Mepilex Transfer 	<ul style="list-style-type: none"> Mölnlycke Health Care 	<ul style="list-style-type: none"> Manage exudate Protection 		
Bordered foam dressings	<ul style="list-style-type: none"> Mepilex Border/Mepilex Border Lite Allevyn Gentle Border Biatain Silicone Border Kerafoam UrgoTul Absorb Border 	<ul style="list-style-type: none"> Mölnlycke Health Care Smith & Nephew Coloplast Keraplast Urgo Medical 	<ul style="list-style-type: none"> Isolated wounds 	<ul style="list-style-type: none"> Lightly exuding or dry wounds 	



Pain management

Optimal pain management is vital for patients with all forms of EB and includes pharmacological and non-pharmacological interventions.

Simple analgesia such as paracetamol and ibuprofen may be sufficient to manage mild pain, while opioids and anxiolytics are necessary for severe pain associated with dressing changes (Fine, Johnson et al, 2004).

For further advice on mouth and dental care see oral health care for patients with epidermolysis bullosa: best care practice guidelines 2012. S Kraemer available via www.debra.international.com

Table 6: Recommendations for dressing retention				
Type	Brand	Manufacturer	Indications/function	Contraindications/comments
Bandage	<ul style="list-style-type: none"> • K-Band • Easifix-K 	<ul style="list-style-type: none"> • Urgo Medical • BSN medical 	<ul style="list-style-type: none"> • Dressing support and retention • Use 2.5cm width for hand wrapping 	<ul style="list-style-type: none"> • Protect dry skin with emollient prior to bandaging • Cover all wounds before bandaging to avoid adhesion
Tubular bandage	<ul style="list-style-type: none"> • Tubifast 2-way stretch • ComfiFast MultiStretch • CliniFast • ActiFast 2-way stretch 	<ul style="list-style-type: none"> • Mölnlycke Health Care • Synergy Health • CliniSupplies • L&R 	<ul style="list-style-type: none"> • Dressing support and retention 	<ul style="list-style-type: none"> • As above
Garments	<ul style="list-style-type: none"> • Skinnies WEB • Skinnies • Dreamskin • DermaSilk • Tubifast garments • ComfiFast Easywrap 	<ul style="list-style-type: none"> • Skinnies UK • Dreamskin • Espère Health Care • Mölnlycke Health Care • Synergy 	<ul style="list-style-type: none"> • Skinnies manufactured range of garments designed with clinical teams and the patient group, specifically for EB patients 	<ul style="list-style-type: none"> • As above
Cohesive bandage	<ul style="list-style-type: none"> • ActiWrap • Coflex Haft 	<ul style="list-style-type: none"> • L&R • Andover Healthcare 	<ul style="list-style-type: none"> • Dressing support and retention 	<ul style="list-style-type: none"> • Do not apply too tightly or it will have a tourniquet effect
Soft silicone tape	<ul style="list-style-type: none"> • Siltape • Mepitac 	<ul style="list-style-type: none"> • Advancis Medical • Mölnlycke Health Care 	<ul style="list-style-type: none"> • Use in place of normal adhesive tape 	

Severely affected patients benefit from long-acting opioids. Some EB patients may benefit from treatment with amitriptyline or gabapentin to help control neuropathic pain. Effective non-pharmacological interventions include guided imagery and distraction therapies. A validated pain scoring system should be used to evaluate a patient's pain experience (Goldschneider and Lucky 2010, Denyer 2012). When a new dressing regimen is recommended it should not add to the patient's experience of pain (Denyer 2009).



Management of pruritus

Pruritus is one of the most challenging aspects of the management of DEB. Intense itch provokes damaging scratching leading to further cutaneous harm.

Wounds that have almost healed are particularly pruritic and scratching can lead to wound breakdown. Apart from skin breakdown, intense pruritus can be seen as part of the pain spectrum and can lead to insomnia and depression. This is particularly marked in DEB *pruriginosa*. In a study patients reported pruritus to be more troublesome than pain (Danial, Adeduntan et al. 2013).

Bathing

Cleansing of patients with EB is a contentious issue, with some advocating daily bathing and others discouraging the practice due to difficulties, such as handling and time factors or intractable pain.

While patients with severe EB benefit from bathing or showering in terms of general hygiene and wound cleansing, many find this too difficult, painful and time-consuming. There is also a wide difference of opinion as to what constitutes best practice in wound cleansing for EB patients (Arbuckle 2010), with clinicians recommending a variety of techniques including:

Practical advice on patients experiencing pruritus ✓

- Avoid sudden changes in temperature and overheated environments where possible
- Some patients may benefit from air conditioning, a Dyson fan which is non-buffering and Chillow pillows in the hotter months. This is a particular consideration in overheated hospital environments
- Avoid using highly perfumed products on the skin
- Use laundry products for sensitive skin
- Clothing should be loose fitting and many people avoid products made of wool. DermaSilk® (Espère) and DreamSkin® garments are cool and have antipruritic qualities
- Stress may exacerbate itch and patients may benefit from relaxation techniques and other methods of stress management

- Using an antimicrobial in the bath or vinegar soaks to gain control of gram-negative organisms, such as *pseudomonas* (Nagoba, Wadher et al, 2008; Nagoba, Selkar et al, 2013)
- Diluted bleach has been shown to reduce rates of infection in those with atopic dermatitis (Huang, Abrams et al, 2009). The dilute bleach should be rinsed off with plain water after bathing to prevent itch. This method has been advocated in some centres for patients with EB
- Salt baths have proved popular with some patients, possibly because the osmotic effect is useful in preventing pain. Add approximately 90g of table salt to 10 litres of water to achieve a 0.9% solution. Salt can be used in combination with antiseptics to reduce their potential to sting (Arbuckle 2010; Petersen, Arbuckle et al, 2015).

However, all these methods require the patient to get into a bath or shower and many are simply unwilling or unable to do this. If they shower care must be taken to ensure a low, gentle flow is used. Therefore, other methods of cleansing and reducing the bioburden of wounds must be deployed (see Tables 11 and 12, pages 33–34).

Psychological evaluation

Depression, social isolation and despair can all have a significant impact on people with EB and their families (Moss 2008), as well as on occasion those professionals caring for them (Dures, Morris et al, 2010). Families living with severe EB will suffer at an emotional level and are frequently impacted financially as parents unable to work due to the burden of care giving (Van, Lettinga et al, 2008; Jeon, On et al, 2016).

The negative feelings that result from living with a chronic incurable disease can lead to the patient becoming disillusioned with healthcare provision and non-concordant with treatments offered. It may result in patients not attending appointments and refusing certain medications. When recommending new dressings, healthcare professionals may be greeted with scepticism and should be prepared to explain carefully why they are suggesting new treatments and what its benefits might be.

MANAGEMENT OF HEAD LICE INFESTATION

Infestations of head lice are common among school children worldwide. However, treatment is not always effective and options are limited, even for those with a healthy skin and scalp, while resistance to insecticides is an increasing problem (Glaziou, Nyguyen et al, 1994, Thomas, McCarroll et al, 2006). (See Case Study 5, page 48).

Management of lice in those with EB can be difficult and may result in excoriation of the scalp, infection and hair loss. Simple measures should be deployed initially. Many children have been treated at the EB Centre at Great Ormond Street Hospital, London, where Dermol 500 lotion (Dermal Laboratories), an emollient containing an antimicrobial agent, has been found to be effective. This can be applied to the hair and scalp before being combed out with a fine-toothed comb. If proprietary insecticides are used, all wounds, blister sites or areas of excoriation on the scalp should first be protected using a thick layer of Vaseline (Unilever).

If the lice cannot be controlled quickly by using the above methods there is a danger that scratching of the scalp will lead to infection, permanent hair-loss and problematic crusting. The lice live under the crusts found on the scalps of many people with severe forms of EB, making mechanical or chemical elimination impossible.

An alternative is to use Ivermectin; the drug selectively binds to specific neurotransmitter receptors of the peripheral motor system of invertebrates. This treatment is also effective in the management of scabies and again eliminates the need for insecticides to be applied to fragile skin. The drug is not recommended for those weighing less than 15kg.



CARE OF NEONATES WITH EB

In severe forms of EB, blisters and wounds are usually present at delivery or result from handling immediately after birth. In milder forms of disease these will often appear during the neonatal period.

Secondary infection is a primary complication. For the recommended dressings used in the management of neonates with EB see Table 7 (below).

In addition, there are several wound care, blister lancing and avoidance techniques that can be used when caring for a newborn that may help lessen the risk of infection and reduce procedural pain (See Box 3 Key recommendations for management of neonates [page 10] and Box 2 Evidence for use of specific wound management strategies [pages 8–9]).

Additionally, there are several wound care and blister prevention techniques that can be administered when caring for a newborn that may help lessen the chance of infection and reduce pain (see Box 3, page 10).

Table 7: Recommended dressings for neonates with EB

<i>First choice of dressing when available: PolyMem</i>					
Dressing type	Brand	Manufacturer	Indications/function	Contraindications/comments	Wear time
Polymeric membrane	<ul style="list-style-type: none"> PolyMem PolyMem Max 	<ul style="list-style-type: none"> Ferris Mfg Corp (Aspen Medical Europe, UK) 	<ul style="list-style-type: none"> First choice dressing for severe neonatal wounding Critical colonisation/infection 	<ul style="list-style-type: none"> Change when wet to avoid hypothermia Distinct smell does not necessarily indicate infection Protect periwound skin 	<ul style="list-style-type: none"> As determined by exudate level
Hydrogel impregnated gauze	<ul style="list-style-type: none"> Intrasite Conformable 	<ul style="list-style-type: none"> Smith & Nephew 	<ul style="list-style-type: none"> JEB-GS Eroded blister sites Wounds/blister sites in nappy area Use a barrier product such as Proshield Plus to remainder of nappy area 	<ul style="list-style-type: none"> Small neonates at risk of hypothermia 	<ul style="list-style-type: none"> Change daily or when dry May need primary contact layer (e.g. UrgoTul)
Hydrofiber	<ul style="list-style-type: none"> Durafiber 	<ul style="list-style-type: none"> Smith & Nephew 	<ul style="list-style-type: none"> Very moist wounds where it is difficult to keep dressings in place Between digits where there is a risk of fusion 	<ul style="list-style-type: none"> Lightly exuding or dry wounds 	<ul style="list-style-type: none"> Change every 3–4 days or when saturated
Lipidocolloid	<ul style="list-style-type: none"> UrgoTul 	<ul style="list-style-type: none"> Urgo Medical 	<ul style="list-style-type: none"> Wound contact layer 	<ul style="list-style-type: none"> Can be difficult to retain on vertical surfaces 	<ul style="list-style-type: none"> Change every 3–4 days
Soft silicone mesh	<ul style="list-style-type: none"> Mepitel Adaptic Touch 	<ul style="list-style-type: none"> Mölnlycke Health Care Acelity 	<ul style="list-style-type: none"> Wound contact layer 	<ul style="list-style-type: none"> Increased risk of over-granulation in JEB Increased risk of blistering in EBS-GS 	<ul style="list-style-type: none"> Change every 3–4 days
Soft silicone foam	<ul style="list-style-type: none"> Mepilex Mepilex Lite Mepilex Transfer Biatain Non Adhesive 	<ul style="list-style-type: none"> Mölnlycke Health Care Coloplast 	<ul style="list-style-type: none"> Protection Absorption 	<ul style="list-style-type: none"> Use as secondary dressing over primary layer of soft silicone or lipido-colloid mesh to prevent adherence 	<ul style="list-style-type: none"> As determined by exudate level
Soft silicone foam with super-absorbers	<ul style="list-style-type: none"> Cutimed Siltec 	<ul style="list-style-type: none"> BSN Medical 	<ul style="list-style-type: none"> Protection Absorption where exudate excessive 	<ul style="list-style-type: none"> For lightly exuding wounds Can be cut between super-absorbent crystals 	<ul style="list-style-type: none"> As determined by exudate level



CARE OF EB PATIENTS IN THE OPERATING THEATRE

When a surgical or interventional procedure is indicated adjustments to anaesthesia and theatre protocols will be required to minimise skin damage, protect the airway and prevent pressure damage.

Common surgical procedures include repair of 'mitten glove' deformity, release of contractures, dental extraction, oesophageal dilatation, formation and repair of gastrostomy sites, excision of squamous cell carcinoma, skin grafting and limb amputation (Table 8, below).

GASTROSTOMY SITE MANAGEMENT

The combination of fragility of the mucosa of the upper gastrointestinal tract (which can lead to blistering of the mouth and pain on eating, dysphagia secondary to narrowing and scarring of the oesophagus, raised

Table 8: Care of the EB patient in the operating theatre ✓

Procedure	Action	Rationale	Comments
ECG monitoring OR	<ul style="list-style-type: none"> Stick electrodes directly to skin Cut sticky part of electrode off and secure with silicone tape Stick electrodes to silicone contact layer e.g. Mepitel One (Mölnlycke Health Care) 	<ul style="list-style-type: none"> To achieve effective monitoring without damaging the skin 	<ul style="list-style-type: none"> Only stick electrodes directly to the skin if SMAR is available When SMAR is not available cover open wounds with non-adherent dressing before bandaging
Blood pressure monitoring	<ul style="list-style-type: none"> Place layer of padding such as Velband/Softban beneath cuff 	<ul style="list-style-type: none"> To minimise skin damage and reduce the risk of blistering 	<ul style="list-style-type: none"> Cover any open wounds with non-adherent dressing before applying Velband Where possible avoid placing cuff over wounded area
Oxygen saturation monitoring	<ul style="list-style-type: none"> Cover digit with commercial plastic food wrap or Mepitel One (Mölnlycke Health Care) 	<ul style="list-style-type: none"> To avoid skin damage 	<ul style="list-style-type: none"> Apply under probe
Protection of the eyes and lids	<ul style="list-style-type: none"> Apply lubricating drops/ointment Cover with non adhesive light moist dressing or Neoheal (Laser Physics) 	<ul style="list-style-type: none"> To reduce risk of eyelid damage or corneal abrasions 	<ul style="list-style-type: none"> Omit lubrication in small children Warn older children or adults about blurred vision upon recovery
Venepuncture	<ul style="list-style-type: none"> Avoid use of elastic tourniquet or glove Squeeze limb firmly, avoiding shearing forces Avoid excessive rubbing during skin preparation 	<ul style="list-style-type: none"> To minimise skin trauma 	<ul style="list-style-type: none"> Wrap dressing material/softband around limb before squeezing Cover any broken or blistered areas with non-adherent dressing before applying the protective layer
Retention/securing of cannula and equipment	<ul style="list-style-type: none"> Mepitel Film (Mölnlycke Health Care) Use soft silicone tape (see Table 6, page25) Use commercial plastic food wrap 	<ul style="list-style-type: none"> To avoid skin stripping Fixation 	<ul style="list-style-type: none"> May need to use SMAR if skin is very fragile If SMAR not available and adhesive used apply 50% liquid/50% white soft paraffin to saturate tape and slowly work free Use clingfilm if soft silicone tape or SMAR not available
Using face mask	<ul style="list-style-type: none"> Apply Mepitel One (Mölnlycke Health Care) or Cuticell Contact (BSN Medical) or Vaseline (Unilever) over face and chin 	<ul style="list-style-type: none"> To avoid shearing forces when using a face mask (especially when there is a change of personnel) To avoid blistering from mask 	<ul style="list-style-type: none"> May need sterile SMAR (Appeel Sterile, CliniMed) to remove if skin is very fragile Take care during change of personnel as the mask may slip Lubricate gloves to avoid gloves from sticking to dressings or skin

nutritional requirement exacted by exuding wounds) and the chronic inflammation seen in severe forms of EB mean oral intake alone can be inadequate. Enteral feeding may be indicated.

Additionally, chronic constipation and painful dentition can lead to a reluctance to eat (Fine and Mellerio, 2009). Despite the advantages in enteral feeding, cutaneous complications following the intractable leakage of acidic stomach contents onto the skin of the abdomen lead to skin loss and chronic wounds (Table 9, below and the Case Study 3 on page 46).

Careful selection of the device can help to reduce complications. 'Button' type gastrostomy tubes are popular as they are discrete; however, they need the feeding tube to be connected very close to the abdomen with possible trauma to the stoma and skin as a result. Trauma to the stoma may cause leakage. Gastrostomy tubes are longer and allow connection to take place well away from the stoma and delicate abdominal skin.

Table 9: Gastrostomy site management ✓

Dressing type	Brand	Manufacturer	Indications/function	Contraindication/ comments
Barrier — creams, sprays, films	<ul style="list-style-type: none"> Proshield Plus Skin Protectant Equal parts of sucralfate/ Cavilon Durable Barrier Cream/No Sting Barrier Film (spray) Sorbaderm Sillesse Medihoney Barrier Cream 50% white soft/50% liquid paraffin 	<ul style="list-style-type: none"> Smith & Nephew In-house pharmacy 3M Health Care Aspen Medical Europe ConvaTec Derma Sciences 	<ul style="list-style-type: none"> Protection 	<ul style="list-style-type: none"> Some patients may experience stinging when applied to very raw skin Avoid contact with gastrostomy device Can make retention of dressings difficult
Soft silicone mesh	<ul style="list-style-type: none"> Mepitel Adaptic Touch 	<ul style="list-style-type: none"> Mölnlycke Health Care Acelity 	<ul style="list-style-type: none"> Wound contact layer 	<ul style="list-style-type: none"> Use double layer with the pores in the mesh non-aligned if over-granulation tissue present
Lipido-colloid	<ul style="list-style-type: none"> UrigoTul 	<ul style="list-style-type: none"> Urigo Medical 	<ul style="list-style-type: none"> Wound contact layer 	
Super-absorbent	<ul style="list-style-type: none"> Sorbion Drainage Sorbion Sachet S Cutimed Siltec KerraMax Care Flivasorb/Vliwasorb Pro 	<ul style="list-style-type: none"> BSN Medical Crawford Healthcare L&R 	<ul style="list-style-type: none"> Leakage 	<ul style="list-style-type: none"> Use over primary dressing Use over superabsorbent drainage dressing
Steroid cream	<ul style="list-style-type: none"> Maxitrol eye ointment Dermovate Cutivate 	<ul style="list-style-type: none"> Alcon Laboratories Glaxo Wellcome UK (Glaxo Labs) PharmaDerm (Fougera Pharmaceuticals) 	<ul style="list-style-type: none"> Over-granulated tissue 	<ul style="list-style-type: none"> As required — not longer than 7 days
Anti-fungal topical cream	<ul style="list-style-type: none"> Nystaform Canesten 	<ul style="list-style-type: none"> Typharm Bayer 	<ul style="list-style-type: none"> Where fungal and/or bacterial infection is present 	<ul style="list-style-type: none"> Twice a day for up to 7 days
Anti-fungal topical with steroid	<ul style="list-style-type: none"> Trimovate Nystaform HC Canestan HC Dermovate NN 	<ul style="list-style-type: none"> GlaxoSmithKline Typharm Bayer Glaxo Wellcome UK (Glaxo Labs) 	<ul style="list-style-type: none"> Treatment of steroid-responsive dermatoses where candida/bacterial infection is present/suspected in children, adults and elderly Short-term treatment of more resistant inflammatory and pruritic manifestations in children (over one years old) adults and elderly 	<ul style="list-style-type: none"> Twice a day for up to 7 days Twice a day until improvement occurs
Oral antifungal	<ul style="list-style-type: none"> Fluconazole 	<ul style="list-style-type: none"> AvKare 	<ul style="list-style-type: none"> Treating and preventing certain yeast and fungal infections, including vaginal candidiasis, oral thrush, fungal pneumonia 	<ul style="list-style-type: none"> To be taken with or without food (at least 2 hours before a PPI, e.g. omeprazole) as prescribed

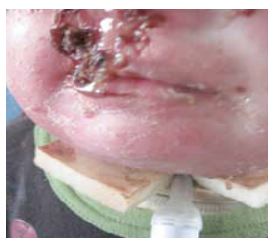

Figure 7: When using a tracheostomy tube in small infants an extension tube may be needed to prevent it rubbing under the chin

Some children and adults with DEB develop delayed gastric emptying, which encourages leakage from the site. In severe cases gastrostomy feeding is not tolerated and jejunal feeding may be necessary. The gastrostomy is replaced with a gastro-jejunal or naso-jejunal device. Although jejunal feeding allows adequate delivery of nutrition, the gastrostomy will continue to leak gastric contents.

Jejunal feeding requires a sterile technique to be used and certain medications commonly given via a gastrostomy cannot be delivered via the jejunal route. Systemic treatments with H₂-receptor antagonists and proton pump inhibitors can be used singly or in combination to reduce the acidity of the gastric contents.

TRACHEOSTOMY MANAGEMENT

In our centres very few patients with EB have tracheostomies, but we have experience of their management both in dystrophic and junctional EB. The main problem for protection of the skin from the tightly fastened securing tapes (Table 10, below).

The stoma site requires protection from the phalange of the tube and the tapes can cut into the back of the neck particularly in young infants where the neck is short. Use of a suitable barrier product may be helpful to protect vulnerable skin. The proximity of the tube in relation to the underside of the chin in small infants can lead to wounds in this area and an extension to the tube should be considered to avoid this (Figure 7).

Dressing type	Brand	Manufacturer	Indications/function	Contraindication/comments
Lipido-colloid	<ul style="list-style-type: none"> UrgoTul 	<ul style="list-style-type: none"> Urgo Medical 	<ul style="list-style-type: none"> Wound contact layer Use underneath tapes 	<ul style="list-style-type: none"> Use wide strip to prevent embedding
Soft silicone mesh	<ul style="list-style-type: none"> Mepitel/ Mepitel One Cuticell Contact Adaptic Touch 	<ul style="list-style-type: none"> Mölnlycke Health Care BSN Medical Acelity 	<ul style="list-style-type: none"> Wound contact layer 	<ul style="list-style-type: none"> Over-granulation tissue (if soft silicone is required use a double layer with pores in mesh misaligned; Silflex) Adherence may be too strong for very fragile skin
Soft silicone foam	<ul style="list-style-type: none"> Mepilex Transfer Mepilex Lite 	<ul style="list-style-type: none"> Mölnlycke Health Care 	<ul style="list-style-type: none"> Use around stoma site 	
Polymeric membrane	<ul style="list-style-type: none"> PolyMem 	<ul style="list-style-type: none"> Ferris Mfg Corp (Aspen Medical Europe, UK) 	<ul style="list-style-type: none"> Around stoma site for cleansing and protection 	<ul style="list-style-type: none"> Check with tracheostomy nurse regarding thickness of dressings for safety reasons to avoid risk of decannulation
Gelling dressing	<ul style="list-style-type: none"> KytoCel 	<ul style="list-style-type: none"> Aspen Medical Europe 	<ul style="list-style-type: none"> Infection 	<ul style="list-style-type: none"> Use over UrgoTul or soft silicone mesh if risk of adherence
Pressure relieving pad/gel	<ul style="list-style-type: none"> Kerrapro Aderma 	<ul style="list-style-type: none"> Crawford Medical Smith & Nephew 	<ul style="list-style-type: none"> Damage from tube phalange or tapes 	<ul style="list-style-type: none"> Do not place directly onto wound

MANAGEMENT OF CHRONIC WOUNDS IN EB

It is vitally important that when dealing with non-healing wounds clinicians try to establish the cause of chronicity. Although this sounds obvious, it is often easy in the context of severe EB to be overwhelmed by the wide variety of presenting wound-related problems. The negative psychological effects of living with a chronic wound(s) should not be underestimated (Adni, Martin et al, 2012).

The most common causes of chronic wounds in EB are likely to be:

- High bioburden (critical colonisation)
- Frank infection due to the loss of the protective function of the skin with large wounded areas and intense pruritus leading to destructive scratching (Abercrombie, Mather et al, 2008; Pillay 2008)
- Presence of necrotic material, commonly soft slough
- The disordered cellular activity seen in all chronic wounds
- Poorly controlled exudate: extremely alkaline exudate is a wounding agent
- The suspected presence of a biofilm will inhibit wound healing and should be suspected in non-healing EB wounds. A biofilm is a multi-species microbial community that secretes a protective matrix. Biofilms interfere with normal wound healing by 'locking' the wound bed into the chronic inflammatory state that leads to elevated levels of proteases and reactive oxygen species (ROS), damaging the proteins and molecules essential for healing. Biofilms communities are often dormant and therefore tolerant to antimicrobials (Wounds International, 2016)
- The margins of chronic wounds in EB are frequently hyperkeratotic with the presence of dried crusty exudate and this devitalised tissue will inhibit the migration of epidermal cells from the wound edges
- There is evidence to support the notion that skin stem cells become 'exhausted' in their never-ending battle to heal wounds (Dellambra, Vailly et al, 1998; Dowsett 2008; Velarde, Demaria et al, 2015).

Beyond the wound the whole patient must be considered and the context in which wound healing is failing to take place must be assessed and addressed. Anaemia and malnutrition will have a negative impact on the patient's ability to heal. Pain also affects the patient's ability to heal, and this may arise from sources other than the wounds. Pruritus may contribute, with scratching frequently leading to the breakdown of newly healed or healing skin.

On occasions the aim of management may not be to heal the wound but to manage it. Focus may need to be on the effective management of wound-related symptoms, i.e. exudate, infection, odour and pain, as well as providing a dressing regimen that is acceptable to the patient and carer.



WOUND BED PREPARATION AND EB

The principles of wound bed preparation (WBP) are applicable to wounds seen in patients with EB, particularly wounds that have become chronic.

The purpose of this document is not to re-state the WBP concept but, briefly, that the principle of it is to remove barriers to healing and to create an optimal wound healing environment.

TIME is a framework that can be used to apply the principles of WBP in practice (Schultz, Sibbald et al, 2003). This comprises the following components:

- Tissue — the wound bed should be free of necrotic material
- Infection or inflammation — the bacterial burden should be controlled by systemic or topical therapies. Inflammatory stimuli due to scratching seen in recalcitrant pruritus in EB may be difficult to manage effectively
- Moisture — excess exudate should be controlled resulting in a moist wound bed and preservation of the periwound skin
- Epithelial advancement — may be inhibited by abnormal cellular activity within the wound (Dowsett 2008).

T — Tissue

Debriding necrotic tissue

This may be an on going process in a chronic wound and so-called 'maintenance debridement' may be required. There are four main debridement options (Table 11, page 33):

- Autolytic debridement is a normal process within a wound whereby proteolytic enzymes and macrophages remove necrotic material. Some dressings can enhance this process
- Surgical debridement is performed in theatre. However, this is not usually an option in EB due to the fact that most of the chronic wounds are exceptionally painful and bleed profusely
- Mechanical debridement can be as simple as wound cleansing or the use of a monofilament debridement pad to remove sloughy tissue (NICE 2014). In some centres whirlpool baths have been used with good effect to cleanse wounds and skin for patients with EB and remove necrotic material. Appropriate analgesia must be given prior to attempting mechanical debridement
- Larval therapy to remove necrotic material has been successful, particularly since the larvae have been available in a 'tea-bag' presentation, rather than free range, which led to difficulties in containment given that adhesive products cause skin damage. However, larval therapy can cause pain in some patients.

I — Infection/critical colonisation

In all forms of EB, skin fragility may result in bacterial colonisation or infection, particularly in the more severe forms where wounds may be multiple and long-standing. This is because the body has lost some of its first-line defences against microbes. The increased bioburden in critically colonised or infected wounds impairs healing and therefore recognition of these situations, and appropriate measures to promote a healing environment, are fundamental to the care of EB wounds (Schober-Flores, 2009; Mellerio 2010; van Duipmans et al, 2014) (Table 12, pages 34–35).

M — Moisture control (exudate management)

Exudate is frequently difficult to manage in chronic wounds seen in patients with EB (Table 13, page 35). This is because of the quantity of exudate, which is often highly viscous. The high viscosity can mean there are difficulties with absorption into the dressing, leading to pooling under dressings causing damage to the wound bed and the surrounding skin. It should be noted that the absorptive capacity of many dressings may be demonstrated using a low viscosity fluid.

The ability of a dressing to manage exudate is also affected by its ability to 'vent' excess fluid from the back of the dressing. Dressings with a backing that allows for a high moisture vapour transmission rate (MVTR) will assist greatly in the management of wound exudate.

In addition, adhesive dressings that may have formed a 'seal' around a wound, thereby containing the exudate, cannot be used, because of the potential for skin stripping on removal.

E — Epithelial advancement

The wound care practitioner may have addressed all the causes of chronicity, and may now have a wound bed that appears healthy, but the wound can still fail to epithelialise. The practitioner may then have to consider such factors as dressings-induced trauma, particularly if dressings are adherent, or are changed with inappropriate frequency. The wound margins may be inhibited from progression by the presence of callus and hyperkeratosis. A further consideration is the concept of skin stem cell exhaustion as mentioned previously (Dellambra, Vailly et al, 1998).

Management of the periwound skin

In all patients with chronic wounds the periwound skin is vulnerable to further damage (Hollinworth 2009). This is particularly true in EB where a large area of the skin can be considered as periwound, while other unbroken areas are vulnerable to damage and breakdown because of the nature of the condition itself.

Chronic wound exudate is potentially corrosive to intact skin and is itself a wounding agent. Maceration of the periwound skin with wound extension is common particularly in areas where exudate drains downward. Red fiery excoriation also leads to skin breakdown and increases pain (Hollinworth 2009).

Choosing a dressing appropriate to the level of exudate is crucial. A dressing should be selected that provides protection by absorbing exudate and holding the moisture within the dressing. Some dressings also protect against lateral wicking of exudate across intact skin.

Table 11: Recommendations for wound debridement in patients with EB ✓

Dressing type	Brand	Manufacturer	Indications/function	Contraindications/comments	Wear time
Hydrogel	<ul style="list-style-type: none"> Many available 	<ul style="list-style-type: none"> No specific brand recommended 	<ul style="list-style-type: none"> Dry necrotic material 	<ul style="list-style-type: none"> Be aware of additional moisture causing maceration Can be used to debride hyperkeratosis and areas of dried exudate Remove once softened with plastic forceps 	<ul style="list-style-type: none"> 1-3 days
Honey (medical grade only)	<ul style="list-style-type: none"> Melloxy Algivon Medihoney Antibacterial Honey Gel Sheet (for sensitive wounds) Mesitran Ointment S 	<ul style="list-style-type: none"> Ideal Medical Solutions Advancis Medical Derma Sciences Aspen Medical Europe 	<ul style="list-style-type: none"> Dry necrotic material Soft slough 	<ul style="list-style-type: none"> Can cause stinging and pain Can increase exudate May need super-absorbent secondary dressing 	
Sheet hydrogel	<ul style="list-style-type: none"> KerraLite Cool ActiFormCool 	<ul style="list-style-type: none"> Crawford Healthcare L&R 	<ul style="list-style-type: none"> As above particularly in keloid type scarring seen in EB <i>pruriginosa</i> 	<ul style="list-style-type: none"> Be aware of product drying out and adhering to wound bed 	<ul style="list-style-type: none"> Change when product becomes discoloured
Hydrofiber	<ul style="list-style-type: none"> Durafiber Aquacel 	<ul style="list-style-type: none"> Smith & Nephew ConvaTec 	<ul style="list-style-type: none"> Soft slough 	<ul style="list-style-type: none"> Be aware of product adhering to hyperkeratotic material at wound margins (e.g. the wound can be wet, but still have dry margins) Risk of strengthening fibres adhering to wound bed, use emollient spray to reduce risk 	<ul style="list-style-type: none"> Change when gel formed Re-wet if dried out before removing
Enzyme alginogels	<ul style="list-style-type: none"> Flaminal Forte Flaminal Hydro 	<ul style="list-style-type: none"> Flen Pharma 	<ul style="list-style-type: none"> Slough with high exudate Slough with low exudate 	<ul style="list-style-type: none"> Keep away from eyes Select appropriate secondary dressing based on exudate levels 	<ul style="list-style-type: none"> Daily initially Decrease to every 3-4 days
Polymeric membrane	<ul style="list-style-type: none"> PolyMem 	<ul style="list-style-type: none"> Ferris Mfg Corp (Aspen Medical Europe, UK) 	<ul style="list-style-type: none"> Soft slough 	<ul style="list-style-type: none"> Be aware of initial increase in exudate 	<ul style="list-style-type: none"> Daily initially then decreasing frequency as per exudate levels
<ul style="list-style-type: none"> Monofilament fibre debridement pad Debridement cloth 	<ul style="list-style-type: none"> Debrisoft UCS debridement 	<ul style="list-style-type: none"> L&R medi UK 	<ul style="list-style-type: none"> Soft slough Hyperkeratosis and dried exudate 	<ul style="list-style-type: none"> Moisten with water or saline Lay on wound bed up 10 minutes as tolerated 	
Sterile maggots	<ul style="list-style-type: none"> Larvae (free range larvae or contained in a mesh pouch with foam) 	<ul style="list-style-type: none"> Bio Monde 	<ul style="list-style-type: none"> Soft slough and necrotic tissue 	<ul style="list-style-type: none"> Not to be used in patients with clotting disorders, on anticoagulant therapy, or on wounds with exposed blood vessels or that bleed easily Free-range maggots must be contained within the wound bed All maggots must be kept moist May reduce patient distaste if contained in a pouch Larval therapy may cause pain 	
Sharp debridement in theatre by a plastic surgeon under general anesthesia					

Table 12: Recommended antimicrobial treatments for infected and critically colonised wounds

First choice of treatment when available: PolyMem, Flaminal, Prontosan X, Octenilin

Dressing type	Brand	Manufacturer	Indications/function	Contraindications/comments	Wear time
Polymeric membrane	<ul style="list-style-type: none"> PolyMem PolyMem Max 	<ul style="list-style-type: none"> Ferris Mfg Corp (Aspen Medical Europe, UK) 	<p>Note: not marked as antimicrobial, but has found to be effective in infected wounds</p> <ul style="list-style-type: none"> Debrides, de-sloughs and antimicrobial Has some action in modulating excess proteases 	<ul style="list-style-type: none"> Change when wet to avoid hypothermia Distinct smell does not necessarily indicate infection Protect periwound skin 	<ul style="list-style-type: none"> Reapply at each dressing change Dictated by condition of wound
Enzyme alginate	<ul style="list-style-type: none"> Flaminal Hydro (low exudate) Flaminal Forte (high exudate) 	<ul style="list-style-type: none"> Flen Pharma 	<ul style="list-style-type: none"> Regular cleansing, rehydration and removal of bacteria and debris Regular cleansing, rehydration and removal of bacteria and debris 	<ul style="list-style-type: none"> Can be used on all wounds apart from third degree burns Do not use if patient has sensitivity to alginates or polyethylene glycol 	<ul style="list-style-type: none"> Apply at each dressing change
Polyhexamethylene biguanide	<ul style="list-style-type: none"> Prontosan Wound Irrigation Solution Wound Gel/GelX Octenilin Wound Gel 	<ul style="list-style-type: none"> B Braun Schulke 	<ul style="list-style-type: none"> Body wash daily as a liquid soap, for a shower, bath or washing 	<ul style="list-style-type: none"> Use over primary dressing to prevent adherence 	<ul style="list-style-type: none"> With primary dressing
Antimicrobial body wash	<ul style="list-style-type: none"> Octenisan 	<ul style="list-style-type: none"> Schulke 	<ul style="list-style-type: none"> Malodorous wounds Chronic wounds where biofilm may be present Sensitive wounds where dressing removal is difficult 	<ul style="list-style-type: none"> General note: Only use medical, gamma-irradiated products due to risk of transmission of botulism spores On occasion, pain levels can be initially increased Is difficult to use in warmer climates where there is poor hygiene/sanitary conditions and no air conditioning and where insects are rife Can cause transient stinging or pain due to its acidity and high osmotic 'pull' In turn this will result in high levels of exudate 	<ul style="list-style-type: none"> May need to change secondary dressing more frequently due to increase in exudate For Medihoney Antibacterial Honey Gel Sheet replace when no evidence of gel sheet remains Apply at each dressing change
Gelling fibre dressing	<ul style="list-style-type: none"> KytoCel 	<ul style="list-style-type: none"> Aspen Medical Europe 	<ul style="list-style-type: none"> Use over atraumatic primary dressing (a soft silicone mesh or lipido-collid) 	<ul style="list-style-type: none"> Superficial infection 	<ul style="list-style-type: none"> As dictated by strike-through on secondary dressing
Honey	<ul style="list-style-type: none"> See Table 11, page 33 for product list 		<ul style="list-style-type: none"> For use on chronic exuding wounds, will assist in the removal of wet necrotic material (slough) 	<ul style="list-style-type: none"> With caution in paediatrics, pregnancy and breast-feeding because of the risk of thyroid suppression Do not use when receiving lithium 	<ul style="list-style-type: none"> Iodoflex is a paste which should be covered with an absorbent pad Daily changes required initially Iodosorb is an ointment Change frequency as above
Hydrogen peroxide	<ul style="list-style-type: none"> Crystacide 	<ul style="list-style-type: none"> Derma UK 			
Dialkylcarbonyl chloride (DACC)	<ul style="list-style-type: none"> Cutimed Sorbact 	<ul style="list-style-type: none"> BSN Medical 			
Cadexomer iodine	<ul style="list-style-type: none"> Iodoflex Idosorb 	<ul style="list-style-type: none"> Smith & Nephew 			

Metronidazole gel	<ul style="list-style-type: none"> Numerous brands available 	<ul style="list-style-type: none"> Malodorous wound/ anaerobic infection/ fungating wounds 	<ul style="list-style-type: none"> Recommended for short-term use only unless in palliative care Most effective in JEB for malodour 	<ul style="list-style-type: none"> Apply at dressing change
Silver	<ul style="list-style-type: none"> PolyMem Silver Mepilex Ag UrigoTul Silver/SSD Aquacel Ag Flamzine 	<ul style="list-style-type: none"> Infected wounds where foam dressing required Primary dressing Short-term use only 	<ul style="list-style-type: none"> Silver products should be used with caution particularly in infants under one year Potential risk of raised plasma silver levels/argyria Restrict use to 14 days and apply to small area for short-term use only 	<ul style="list-style-type: none"> Every 3–4 days or as dictated by strikethrough or personal preference

Table 13: Moisture/exudate management ✓

First choice of dressing when available:

Cutimed Siltec

PolyMem Max

Periwound skin should be assessed for maceration particularly when using PolyMem, which can initially stimulate high exudate levels

Dressing type	Brand	Manufacturer	Indications	Contraindication/comments	Wear time
Carbon dressing	<ul style="list-style-type: none"> Zorflex 	<ul style="list-style-type: none"> Chemviron Carbon (distributed by H&R Healthcare) 	<ul style="list-style-type: none"> Antimicrobial dressing for use over discharging, partial or full thickness wounds 	<ul style="list-style-type: none"> Can be cut to size Moisten or soak dressing to aid removal 	<ul style="list-style-type: none"> Up to 7 days
Super-absorbent	<ul style="list-style-type: none"> Cutimed Siltec Sorbion Sachet S Flivasorb/Viwasorb Pro KerraMax 	<ul style="list-style-type: none"> BSN Medical L&R Crawford Healthcare 	<ul style="list-style-type: none"> Heavily exuding wounds 	<ul style="list-style-type: none"> Arterial bleeds 	<ul style="list-style-type: none"> Change when wet/heavy
Polymeric membrane	<ul style="list-style-type: none"> PolyMem 	<ul style="list-style-type: none"> Ferris Mfg Corp (Aspen Medical Europe, UK) 	<ul style="list-style-type: none"> Note: not marked as antimicrobial, but has found to be effective in infected wounds 	<ul style="list-style-type: none"> May provoke initial increase in exudate and frequent changes may be require This should decrease with time Distinct smell does not necessarily indicate infection Protect periwound skin 	<ul style="list-style-type: none"> When strikethrough observed
Specialised foam	<ul style="list-style-type: none"> PolyMem/Max PolyMemWIC 	<ul style="list-style-type: none"> Ferris Mfg Corp (Aspen Medical Europe, UK) 	<ul style="list-style-type: none"> Moderate/heavy exudate 	<ul style="list-style-type: none"> Contains highly absorbent starch Distinct smell does not necessarily indicate infection Protect periwound skin 	<ul style="list-style-type: none"> Change when wet or heavy
Foam	<ul style="list-style-type: none"> MepilexXT/Mepilex Border/Mepilex Transfer KerraFoam Allevyn Gentle/Gentle Border Biatain Silicone Border 	<ul style="list-style-type: none"> Mölnlycke Health Care Crawford Healthcare Smith & Nephew Coloplast 	<ul style="list-style-type: none"> Low to moderately exuding wounds Moderate to highly exuding wounds Moderate to highly exuding wounds 	<ul style="list-style-type: none"> Poor absorption of highly viscose exudate with secondary padding Silicone sensitivity for border range 	<ul style="list-style-type: none"> Change secondary padding when wet As dictated by exudate levels

The frequency of dressing change is also important in protecting the periwound skin as damage from maceration can result if the dressing change frequency is inappropriate for the volume of exudate. Some dressings, for example honey products and polymeric membrane dressings, may initially increase the level of exudate and require more frequent dressing changes (Denyer 2010).

At dressing changes the periwound skin should be gently cleansed to remove exudate. Adhesive dressings should be routinely avoided in EB to prevent skin stripping — even dressings with low adherence may need to be used with caution in patients who have extremely fragile skin. If an adhesive dressing is used ensure SMARS are available to aid removal.

Table 14: Recommendations for the management of periwound skin ✓

Type	Brand	Manufacturer	Indications/function	Contraindication/comments
Barrier creams	<ul style="list-style-type: none"> Proshield Plus Cavilon Medihoney Barrier Cream Equal parts of liquid paraffin and white soft paraffin 	<ul style="list-style-type: none"> Smith & Nephew 3M Health Care Derma Sciences Various 	<ul style="list-style-type: none"> Barrier against body fluids 	<ul style="list-style-type: none"> Avoid use under adhesive products as it can increase adhesion Barrier creams may interfere with the ability of soft silicone products to adhere properly to the skin and may exacerbate lateral wicking of exudate Also moisturises the skin so be aware of making it 'too soft' and increasing the tendency to blister
Barrier films	<ul style="list-style-type: none"> Sorbaderm No-Sting Barrier Film Cavilon No Sting Barrier Film LBF No Sting Barrier Film 	<ul style="list-style-type: none"> Aspen Medical Europe 3M Health Care CliniMed 	<ul style="list-style-type: none"> Barrier against body fluids 	<ul style="list-style-type: none"> May prevent adherence of soft silicone products
Cleansing agents	<ul style="list-style-type: none"> Emollin Emollient Spray 	<ul style="list-style-type: none"> CD Medical 	<ul style="list-style-type: none"> Can be used on intact skin and wounds 	<ul style="list-style-type: none"> Does not require rinsing from the skin Use in place of water on sore skin

Table 15: Treatment of choice for chronic wounds based on consensus opinion ✓

First choice of treatment when available: PolyMem, Flaminal Hydro/Forte

Dressing type	Brand	Manufacturer	Indications	Contraindication/comments	Wear time
Polymeric membrane	<ul style="list-style-type: none"> PolyMem PolyMem Max PolyMem WIC (under a secondary dressing or further layer of PolyMem) 	<ul style="list-style-type: none"> Ferris Mfg Corp (Aspen Medical Europe, UK) 	<ul style="list-style-type: none"> Infected wounds Recalcitrant wounds 	<ul style="list-style-type: none"> Can provide an initial increase in exudate resulting in further skin damage if not properly controlled Distinct smell does not necessarily indicate infection Protect periwound skin 	<ul style="list-style-type: none"> Change when wet to avoid hypothermia
Enzyme alginate	<ul style="list-style-type: none"> Flaminal Hydro Flaminal Forte 	<ul style="list-style-type: none"> Flen Pharma 	<ul style="list-style-type: none"> Low exudate High exudate 	<ul style="list-style-type: none"> Debrides, de-sloughs and antimicrobial Has some action in modulating excess proteases Can be used on all wounds apart from third degree burns Do not use if patient has sensitivity to alginates or polyethylene glycol 	<ul style="list-style-type: none"> Re-apply at each dressing change at least 2mm thick
Honey	<ul style="list-style-type: none"> See Table 11, page 33 		<ul style="list-style-type: none"> Sensitive wounds 	<ul style="list-style-type: none"> Can cause transient stinging or pain due to its acidity and high osmotic 'pull' In turn this will contribute to high levels of exudate 	
Protease modulator	<ul style="list-style-type: none"> UrgoTul Start range Promogran Promogran Prisma (with silver) 	<ul style="list-style-type: none"> Urgo Medical Acelity 	<ul style="list-style-type: none"> When excess protease may be present 	<ul style="list-style-type: none"> Promogran/Promogran Prisma may cause initial transient stinging Excess product cannot be saved once opened as it degrades on contact with air A secondary dressing required and the product may provoke initial heavy exudate 	<ul style="list-style-type: none"> Frequent dressing changes may be required to avoid maceration

A variety of topical products can be used to protect the periwound skin when it is thought to be vulnerable (Table 14). Padding of vulnerable areas, particularly those that are scarred, may also help prevent further injury and skin breakdown.

Other advanced therapies

Other advanced therapies, directed towards wound healing such as injected fibroblasts, bone marrow transplants and gene corrected skin grafts are also being used in limited numbers of EB patients within research trials. This is a rapidly developing field.

Table 16 highlights wound care products that have been particularly helpful in either improving or healing stalled wounds in EB at the London EB Centres. Dressing choice will, of course, depend on the complete clinical picture following a holistic assessment.

Table 16: Advanced therapies for chronic wounds ✓				
Dressing type	Brand	Manufacturer	Indications	Contraindication/ comments
Bioengineered skin grafts	<ul style="list-style-type: none"> Dermagraft Apligraf 	<ul style="list-style-type: none"> Organogenesis 	<ul style="list-style-type: none"> Long-standing non-healing wounds 	<ul style="list-style-type: none"> Careful wound bed preparation required Expensive
Other products to consider				
Keratin dressing	<ul style="list-style-type: none"> keragel 	<ul style="list-style-type: none"> Keraplast (distributed by H&R Healthcare) 	<ul style="list-style-type: none"> For hard-to-heal wounds 	<ul style="list-style-type: none"> May cause stinging and need to be diluted with emollient Apply a thin layer and allow to dry if not adding secondary dressing
Collagen dressings	<ul style="list-style-type: none"> Helisorb Particles/ Neuskin-F 	<ul style="list-style-type: none"> Medira Ltd 	<ul style="list-style-type: none"> For hard-to-heal wounds 	<ul style="list-style-type: none"> Helisorb Particles and Neuskin-F contain piscean collagen and may provide a cost-effective alternative. No odour is associated with piscean collagen

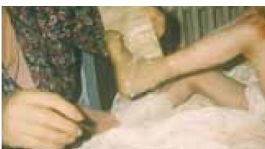

Figure 8-10: Melted fat is spread onto toilet paper; the toilet paper is wrapped around skin and wounds; it is easily removed without adherence

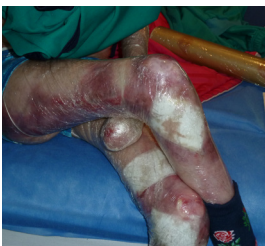

Figure 11: Clingfilm is applied directly to intact skin and open wounds

Treatment of EB with limited resources

While those with EB in the UK are fortunate to have access to an extensive range of dressings, other countries that have limited resources may need to seek alternative methods of wound care.

A survey of 15 patients with complex EB by Dr Ravi Hiremagalore, Consultant Paediatric Dermatologist, Bangalore Manipal Hospitals, Bangalore, India, identified some commonalities in their self-management:

- Most interviewed were not aware of the need to lance blisters
- Few had knowledge of commercial dressings
- Those with knowledge did not have resources to purchase dressings
- Most preferred not to dress wounds due to the heat, which results in increased blistering
- Most had been prescribed topical antibiotic treatment which is easily accessible
- They have no awareness of antibiotic resistance
- Some use Betadine cream
- Two patients used traditional Indian complimentary medicine, Ayurveda.

Dr Hiremagalore concluded from this small sample that his patients prefer not to use dressings but to use topical antibacterial creams. The reasons given are financial and to avoid increased blistering.

Where patients successfully manage their wound care without dressings in hot climates we would suggest they continue this practice. In light of this information we recommend education regarding lancing of blisters and possible antibiotic resistance. Figures 8-11 show examples of alternative wound products that patients

Material type	Indication/function	Contraindication/comments
Clingfilm/clear food wrap	<ul style="list-style-type: none"> Open wounds/intact skin for protection Use if no dressings available 	<ul style="list-style-type: none"> Apply antiseptic/antimicrobial product under film Use padding between two layers of film for areas needing protection Be aware of potential for over-heating
Cotton material/gauze	<ul style="list-style-type: none"> Open wounds/intact skin Use if no dressings available 	<ul style="list-style-type: none"> Spread with greasy emollient Change frequently to prevent adherence
Cigarette papers	<ul style="list-style-type: none"> Use if no dressings are available 	<ul style="list-style-type: none"> Change daily Allow to float off if bathing or irrigate to remove
Toilet paper spread with melted fat	<ul style="list-style-type: none"> Wrap around as a bandage (See Figures 8-10) 	<ul style="list-style-type: none"> Change daily Allow to float off if bathing or irrigate to remove

with limited resources have found helpful. Table 17 (page 38) shows a few examples we have learned from resourceful families and healthcare professionals.



MANAGEMENT OF SQUAMOUS CELL CARCINOMA (SCC)

In patients with severe forms of EB there is a high risk of SCC. Regular monitoring is essential with a low threshold for biopsy for suspect areas.

A histopathologist with experience of EB skin cancers should ideally examine a tissue sample. Suspicion should be aroused if:

- The wound has been present for more than 3 months
- Exuberant tissue growth above the level of the surrounding skin
- The wound is ulcerated
- The wound has little feeling
- The wound is intensely painful
- The patient reports that the wound feels different.

Patients and their carers are frequently the first people to recognise that there is a problem and their concerns should be listened to. At the London EB Centres there is a very low threshold for biopsy as it is now recognised that even wounds that at first may appear insignificant can in fact harbour an SCC.

MANAGEMENT OF FUNGATING WOUNDS

Patients who are at the end of life as a result of an inoperable SCC will often have a fungating wound (Abercrombie, Mather et al, 2008; Mellerio, Robertson et al, 2016). They are generally unresponsive to chemotherapy, but radiotherapy may help in the palliation of symptoms (Fine 2004; Venugopal and Murrell 2010; Mellerio, Robertson et al, 2016).

When caring for a patient who has a fungating or malignant wound the overall aim is to promote patient comfort and maintain or improve quality of life, by addressing the following issues:

- Pain
- Exudate
- Odour
- Bleeding
- Infection

(Grocott 2000; Grocott, Gethin et al; 2013, Gethin, Grocott et al; 2014)

While use of multiple dressings should generally be avoided, the clinician caring for a patient with a malignant wound is frequently required to use a variety of dressings 'layered up' to achieve optimal results. This is because the ideal dressing to manage the complex range of symptoms and challenges seen in fungating wounds has yet to be developed (Grocott, 2000) (Table 18, pages 40-41).

**For further advice see
*Best Practice Guidelines
for the Management
of Squamous Cell
Carcinoma in
epidermolysis bullosa*
is available via [www.
debra.international.
com](http://www.debra.international.com)**

Frequent dressing changes should be avoided, both to prevent additional pain, discomfort and possible bleeding, which is common in fungating tumours as blood vessels are eroded by the growth of the tumour. Dressing changes should also be kept to a minimum to avoid possible distress to the patient and their carers by the visible appearance and the severe odour. This has to be balanced with the need for exudate management (Grocott, 2000).

A careful, regular, structured assessment must be carried out to ensure the effectiveness of the wound care regimen and to enable adjustments where necessary. Effectiveness may be assessed by the patient, carers and professional team (Grocott, 2000). An interdisciplinary approach is imperative in ensuring that the patient receives the best possible care.

Table 18: Recommendations for the management of fungating wounds ✓

Dressing type	Brand	Manufacturer	Contraindications/comments	Wear time
Topical analgesia	<ul style="list-style-type: none"> Topical morphine (unlicensed) 	<ul style="list-style-type: none"> 10mg morphine for injection in 10g of hydrogel This dosage can be increased as required Evidence shows there is little if any systemic absorption, apart from when used over large areas 	<ul style="list-style-type: none"> Do not exceed total daily dose of NSAIDs if patient is also taking systemically 	<ul style="list-style-type: none"> Re-apply when analgesic effect diminished
Barrier creams and films	<ul style="list-style-type: none"> Biatain Ibu Non-adhesive 	<ul style="list-style-type: none"> Coloplast 	<ul style="list-style-type: none"> Barrier against body fluids to prevent further destruction of periwound skin and reduce pain and pruritus 	<ul style="list-style-type: none"> Re-apply at dressing change
Debriding agents	<ul style="list-style-type: none"> Debrisoft Hydrogel UCS debridement cloths Honey (See Table 11, page 33) Surgical debridement 	<ul style="list-style-type: none"> L&R Various medi UK Various 	<ul style="list-style-type: none"> Extremely effective for removing soft slough, hyperkeratosis and dried exudate Should be moistened with saline or water. The pad should be folded not cut Promotes autolytic debridement, however this will increase exudate levels and the gains must be balanced against the difficulties of managing extra moisture Honey is very effective in combating infection, odour and assisting in autolytic debridement Not indicated due to the tendency of these wounds to bleed (see special considerations, Table 19, below) 	
Topical deodorisers	<ul style="list-style-type: none"> Melloxy Metronidazole gel 0.75%/0.8% Activon Tuile Medihoney Antibacterial Wound Gel Mesitran Ointment 	<ul style="list-style-type: none"> Ideal Medical Solutions Various Advancis Medical DermaSciences Aspen Medical Europe 	<ul style="list-style-type: none"> Can also be mixed with morphine to combat both pain and odour (unlicensed) Some patients may experience stinging or pain, the clinician should be aware that exudate levels may increase 	
Odour-absorbing dressings	<ul style="list-style-type: none"> CarboFlex CliniSorb Zorflex Actisorb Silver 220 	<ul style="list-style-type: none"> ConvaTec CliniMed Chemiviron Carbon (distributed by H&R Healthcare) Acellity 	<ul style="list-style-type: none"> The authors have used these dressings over a primary non-adherent layer. Many will also lose effectiveness when wet Cannot be cut to size. Has a wound contact layer and is highly absorbent Can be cut to size Can be cut to size Cannot be cut to size 	<ul style="list-style-type: none"> Dictated by exudate levels
Systemic antibiotics	<ul style="list-style-type: none"> Various 	<ul style="list-style-type: none"> Various 	<ul style="list-style-type: none"> As per clinical presentation/swab results May be effective in reducing pain, odour and levels of exudate 	

Non-adherent primary dressings	<ul style="list-style-type: none"> • UrgoTul • Mepilex Transfer 	<ul style="list-style-type: none"> • Urgo Medical • Mölnlycke Health Care 	<ul style="list-style-type: none"> • The fine weave of this dressing makes it the first choice primary dressing for a delicate fungating wound • Highly conformable foam dressing which allows for passage of exudate through to a secondary dressing 	<ul style="list-style-type: none"> • Primary dressing can be used for up to 7 days for primary layer • Secondary dressing dictated by exudate levels
Hydrofiber	<ul style="list-style-type: none"> • Durafiber • Aquacel 	<ul style="list-style-type: none"> • Smith & Nephew • ConvaTec 	<ul style="list-style-type: none"> • Multiple layers (as determined by exudate levels) may provide a soft highly conformable secondary dressing • Do not apply direct to the wound as it may adhere 	
Super-absorbent	<ul style="list-style-type: none"> • Eclypse • KerraMax Care • Cutimed Siltec • Flivasorb/Vliwasorb Pro 	<ul style="list-style-type: none"> • Advancis Medical • Crawford Medical • BSN Medical • L&R 	<ul style="list-style-type: none"> • Cannot be cut to size unless otherwise indicated 	
Bandage/retention	<ul style="list-style-type: none"> • K-Band • Hospiform • Slinky • Skinnies WEB retention garments 	<ul style="list-style-type: none"> • Urgo Medical • Hartmann • Mölnlycke Health Care • Skinnies UK 	<ul style="list-style-type: none"> • Variety of retention bandages available • The bandage should not put additional pressure on the wound but must be firm enough to prevent the dressings slipping • Tubular bandages can also be used 	

Table 19: Special considerations for bleeding
Note: Careful cleansing and avoidance of adherent dressings can help prevent bleeding. It is useful and reassuring to the patient/family to have a small supply of haemostatic products in the home

Dressing type	Brand	Manufacturer	Contraindication/comments	Wear time
Alginates	<ul style="list-style-type: none"> • Kaltostat • Sorbsan 	<ul style="list-style-type: none"> • ConvaTec • Aspen Medical Europe 	<ul style="list-style-type: none"> • Haemostat • Haemostat 	
Gelling fibre	<ul style="list-style-type: none"> • KytoCel 	<ul style="list-style-type: none"> • Aspen Medical Europe 	<ul style="list-style-type: none"> • Haemostat 	
Haemostatic sponge	<ul style="list-style-type: none"> • Spongostan 	<ul style="list-style-type: none"> • Johnson & Johnson 	<ul style="list-style-type: none"> • Haemostat 	
Sucralfate paste	<ul style="list-style-type: none"> • 1g mixed with KY Jelly 		<ul style="list-style-type: none"> • Self-mixed 	
Oral antifibrinolytics such as tranexamic acid			<ul style="list-style-type: none"> • Careful attention to contraindications and side effects 	
Adrenaline 1:1000			<ul style="list-style-type: none"> • Applied topically • Used with great caution and under medical supervision • Can cause local necrosis and be absorbed systemically 	
Palliative radiotherapy			<ul style="list-style-type: none"> • Can reduce tumour size 	

General measures for end-of-life care

Analgesia and symptom management

The palliative care team will likely manage pain and symptom management. However, there is a requirement for fast-acting analgesia for dressing changes. A regular review of the patient's pain levels is crucial (Goldschneider, Good et al, 2014).

Syringe drivers

Syringe drivers are well tolerated in EB and can be secured with a soft silicone tape or film (Table 8 page 28).

Analgesic 'patches'

These can be used even in severe EB and can safely be removed with a SMARS.

Amputation

Our experience of limb amputation is that patients generally heal well. However, there are difficulties in fitting prosthesis, particularly if this is on the lower limbs where pressure will potentially provoke skin damage.

With the aid of specialist prosthetist, well briefed on EB, patients in London centres have been supplied with prostheses with a mixed degree of success (Jain and De, 1988). One patient had a prosthetic leg, which he wore successfully for the last two years of his life. This was fitted a few weeks post-surgery when good healing had been achieved. A silicone liner was used to protect the stump.

The patient did report blistering and skin breakdown, but he felt this was no more than he would have experienced on his own foot. Another patient with EB, rejected an arm prosthesis, as the perfect prosthetic hand looked nothing like her own contracted and scarred hand.

Pressure relief and manual handling

One of the difficulties faced by patients at the end of life is moving in order to reduce pressure and possible skin damage. There are also potential difficulties in moving patients for procedures or toileting.

Lateral transfers

For lateral transfers the use of a 'Hover-Matt®' (HoverTech International) can be invaluable although this equipment is expensive. A more readily available alternative is Slide Sheets, however PAT slides should be used with extreme caution.

Pressure redistribution

When the requirement for pressure relief is of low-to-moderate risk, the 'Repose®' mattress (Frontier Therapeutics) may provide a cost-effective solution which is acceptable for most people with EB.

When the risk of pressure damage is high (such as at the end of life), a low air-loss system is very effective. As there is likely to be high levels of wound fluid, which may leak into the bed, a system which combines a Gore-Tex® sheet, allowing low air loss and moisture management, may be useful. Some patients may not accept this as movement is made more difficult once they are on the mattress.

Toileting

This is always challenging when patients near the end of life. For urinary control 'slipper' bed pans or a device called a 'Shewee' (Shewee Ltd) can be used. Alternatively, a well-lubricated urinary catheter can be inserted. The latter is generally contraindicated in severe EB, but at the end of life any resultant minimal damage has to be balanced with the patient's comfort.

Bowel management can be very challenging and pads or nappies may be required if the patient is unable to sit on a bedpan or commode. On occasion, patients have developed diarrhoea in the palliative phase. Dressings that are likely to be soiled can be protected with commercial cling film to avoid further distressing dressing changes.

Catastrophic bleeding

This is a rare event and various methods for control or prevention are cited (Pereira and Phan, 2004), however this is not within the scope of these guidelines. Good care can be achieved by having a clear management plan. Local policies must be followed when caring for a patient at risk of such a bleed and preparations must be made to manage the situation (Mellerio, Robertson et al, 2016).

Case studies

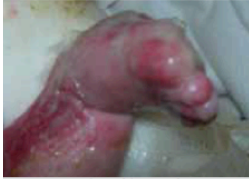

Figure 1: Patient at 18 days old. Soft silicone mesh and foam dressings were used to treat wounds

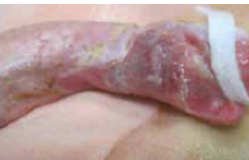

Figure 2: Strips of Hydrofiber are placed between the toes (all toes except the great toe fused in this infant).

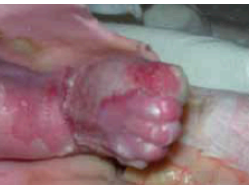

Figure 3: Patient at 28 days old after using polymeric membrane dressing

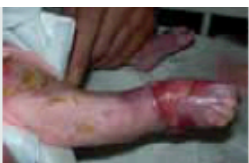

Figure 4 and 5: Patient at 48 days old using polymeric membrane dressings

CASE STUDY 1

NEONATE WITH RDEB-SG

This infant presented with skin fragility, wounds and nail dystrophy at birth. Extensive wounds over the right leg and left foot involving both dorsal and plantar aspects and de-gloving of all toes had been caused by a combination of damage from intrauterine movements and trauma from delivery.

Treatment plan

The treatment objectives were to help the wounds to heal while minimising contractural scarring and attempting to avoid digital fusion.

Wounds were dressed shortly after birth using Vaseline-impregnated gauze as a wound contact layer with several layers of dry gauze as a secondary dressing. Unfortunately the Vaseline gauze dried out causing the dressings to adhere firmly to the wounds. Removal was aided by SMARS but further skin stripping and trauma was inevitable.

The wounds were then dressed using soft silicone mesh as a primary dressing and soft silicone foam placed over the mesh to absorb exudate and offer protection against further trauma (Figure 1). These dressings were readily available and at the time were the standard initial management for severely affected neonates. These dressings were selected for atraumatic removal.

Strips of a hydrofiber dressing (Aquacel, ConvaTec) were placed between the toes to try and avoid digital fusion (Figure 2). Hydrofiber is highly conformable and, because it is very soft, it will not cause trauma. It turns to a gel when in contact with moisture and can remain *in situ* when placed between and around de-gloved digits.

The soft silicone dressing was used for 21 days; healing was slow and the exudate was offensive. The complexity of a two-layer dressing system meant prolonged dressing changes and therefore it was decided to change to polymeric membrane dressings (PolyMem, Ferris Mfg Corp [Aspen Medical Europe, UK]).

PolyMem is ideal for neonates because a primary dressing is not required, reducing the time taken to change dressings and therefore reducing pain and distress. The dressing contains a non-toxic cleanser (F68) that offers continual cleansing of the wounds, reducing the risk of infection. The cleansing is of particular value as bathing is not recommended until the damage caused at birth has healed as it is not possible to protect from trauma during this procedure.

PolyMem was wrapped around the legs and taped to itself and a two-way stretch tubular bandage (Tubifast, Mölnlycke Health Care) was used to further secure the dressing and to prevent rubbing from the overlapping area of PolyMem and the edges of the securing tape.

Outcomes

Initially the PolyMem dressing required changing daily due to excessive exudate and the resulting wetness which was at risk of lowering the baby's temperature. After that the dressings were changed every 3 days. The wounds remained clean and gradually healed over a period of eight weeks.

Unfortunately, during dressing changes on the neonatal unit hydrofiber strips were not always used to separate the toes and digital fusion resulted on one foot. This can occur within 24 hours of two raw surfaces being in apposition.

CASE STUDY 2

NEONATE WITH JEB-SG

This 3-week old baby had blistering around the umbilicus and inflammation around the nail beds that had been present at birth and they were dressed with soft silicone foam. The blistering had spread across the abdomen and sides. (Figure 1). Healing was compromised because of continual friction from the nappy edges.

Treatment plan

The objectives were to promote comfort, to avoid the spread of further blistering and to reduce friction affecting the wound area. The products chosen were 50% liquid/50% white soft paraffin in ointment or spray form (Emollin spray) for cleansing the nappy area and hydrogel impregnated gauze (IntraSite Conformable, Smith & Nephew) for the lesions in the nappy area (Figure 2). The remainder of the wounds remained dressed with soft silicone products. Morphine in a hydrogel was used as a topical analgesia.

Within a few days the lesions were much improved and were healed within 1 week. Pain scores at nappy changes were low but crying was noted when the hydrogel impregnated gauze was applied. This was thought to be because of the shock of the cold wet gauze contacting her warm skin. Dressings were changed with each nappy change.

As the gauze was at risk of drying out, lipido-colloid dressings (UrgoTul, Urgo Medical) were placed under the hydrogel impregnated gauze. A two-way stretch tubular bandage was used to keep the dressing in place. Dressings were initially changed daily but as the disease progressed and the infant became weaker these were reduced to every 2-3 days depending on her level of tolerance.

Outcomes

All lesions healed within 4 weeks and pain at dressing changes was reduced. The wounds remained clean. New blisters and wounds occurred only occasionally and these healed rapidly despite the progressive cachexia and breathing impairment. The infant died aged 14 months but the skin was largely intact before her death (Figure 3).

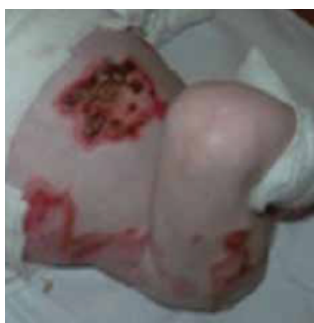

Figure 1: Patient aged 3 weeks using soft silicone mesh

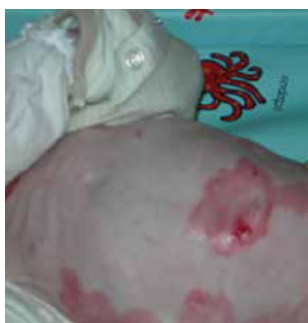

Figure 2: Patient aged 6 weeks after switching to a hydrogel impregnated gauze

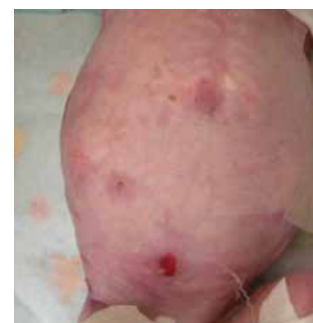

Figure 3: Aged 13 months following treatment with a lipido-colloid as a wound contact layer with a hydrogel impregnated gauze as a secondary dressing

CASE STUDY 3

WOUND CAUSED BY LEAKAGE FROM A GASTROSTOMY IN A PATIENT WITH RDEB-SG

Supplementary enteral feeding is necessary for many children and adults with severe forms of EB. In particular, those with severe generalised dystrophic EB require gastrostomy feeding to meet their increased nutritional requirements. One of the complications of gastrostomy feeding in this group is leakage of stomach contents onto the fragile surrounding skin. Leakage is difficult to control as it is partly caused by inflammation within the stomach wall leading to delayed gastric emptying. The excessive leakage of both enteral and oral feeds can compromise nutritional status. Jejunal feeding via a gastro-jejunal tube ensures adequate delivery of nutrition, but does not solve the problem of the leakage of stomach contents.

Case report

The patient was 12 years old and had a wound 5cm x 5cm around her stoma site and deep excoriation extending across her abdomen, sides and back caused by continual leakage of stomach contents from the gastrostomy site (Figure 1).

Medical management included systemic treatments of proton pump inhibitors and H₂-receptor antagonists and topical application of barrier products. Healing was continually compromised by the constant leaking of acidic stomach contents onto excoriated skin.

Treatment plan

The leakage could not be prevented despite all attempts to correct the problem. The aims of treatment were to ease pain and prevent the extension of the wound and further excoriation. The product chosen was a super-absorbent drainage dressing (Sorbion Sachet S drainage dressing, BSN Medical).

The wound was cleansed with saline and then a topical barrier was used (Proshield Plus, Smith & Nephew). The primary dressing was a lipido-colloid (UrgoTul, Urgo Medical) selected for its non-adherent properties, conformability and comfort. Sorbion Sachet Drainage and Sorbion Sana (BSN Medical) were used as secondary dressings. Sorbion Sachet Drainage was placed around the gastrostomy device to absorb stomach contents as they leaked and the Sorbion Sana placed on top as the drainage dressing was unable to absorb the large volume of fluid.

A tubular bandage was used for retention.

Outcomes

Leakage continued but was contained with the super-absorbent dressings. Clothing remained dry, which was important to the patient. Over the course of 6 weeks the wound decreased in size to a 1cm x 1.5cm area beneath the gastrostomy button and the large area of excoriation healed (Figure 2). Pain scoring on the Wong Baker Scale dropped from 10 to 2 during both dressing changes and wear time.

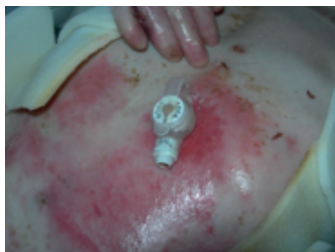

Figure 1: Gastrostomy wound before being treated with super-absorbent drainage dressings

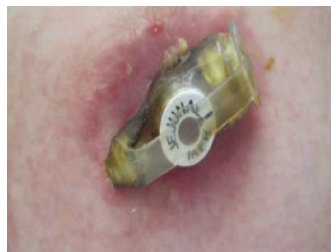

Figure 2: After 1 month of using super-absorbent drainage dressings

CASE STUDY 4

TREATING A SHIN WOUND FOR A PATIENT WITH JEB-I

A 23-year-old man with JEB-I sustained injuries while playing football, which resulted in extensive wounding to both of his shins. The wounds had been present for 17 years and had been treated with topical steroids for prolonged periods, but had extended and worsened over this time. Eventually the clinical team managed to persuade the patient to discontinue topical steroids in view of the undesirable side effects. The patient was working and was on his feet most days. Pain was not a particular feature of this wound, which was surprising. The wound appeared to have healed at times, as evidenced by the red, scarred areas around the wound, consistent with previous wounding. However, the scar tissue remained fragile and vulnerable, and frequently broke down thereby extending the wound. Pruritus and consequent scratching contributed to breakdown of previously healed areas.

The wound bed appeared clean, if somewhat over-granulated and fragile. The wound bed was a fiery unhealthy red, and while there were no signs of infection, which was a concern. There was some maceration of the periwound skin; the result of high levels of exudate. There was also evidence of hyperkeratosis in some areas of the periwound skin. The patient had been using two layers of silicone products for at least 7 years. A sensitivity to silicone dressings had been noted in other patients with EB who had used the products for long periods. Discontinuing silicone products in some patients had been noted to lead to substantial improvements. Silicone itself is inert; however, the sensitivities are thought to arise from impurities within the silicone. 'Silicone allergy' is a topic of some debate, but we based our approach on clinical experience and the fact that a dressing substitution will at worst do no harm, and at best will improve the situation.

Treatment plan

The treatment objectives were to:

- Control exudate levels
- Reduce over-granulation
- Protect the periwound skin
- Debride the hyperkeratotic areas
- Substitute a lipidocolloid dressing for the primary silicone layer
- Prevent infection.

The wound was washed with Octensian (Schülke) at each dressing change to prevent infection and Dermovate NN (GSK) was applied to over-granulated areas for 3 days after which there was a reduction in hypergranulation tissue. A 50/50 emollient was used to soften the hyperkeratotic areas and aid manual debridement with forceps. UrgoTul (Urgo Medical) was used as a primary dressing to ascertain whether the patient was intolerant to the impurities in the soft silicone dressings he had been using. Mepilex Transfer (Mölnlycke Health Care) was used to ensure that exudate transferred away from the wound bed and the periwound skin to the secondary absorbent dressing. Release (J&J) was used as this was the patient's preference. The patient also made the decision to resign from his employment to focus on trying to heal this wound by ensuring rest and regular dressing changes. K-Band (Urgo Medical) and Tubifast (Mölnlycke Health Care) were used for retention. Cavilon (3M) was used to protect the periwound from maceration.

Outcomes

Initial improvement was apparent within 1 week using a lipido-colloid dressing in place of a soft silicone dressing. The wound bed appeared much less inflamed. The wound healed almost completely over a period of 18 months (Figure 2). A large contributory factor to the healing was undoubtedly the fact that the patient stopped work and spent time with his legs elevated and was able to carry out dressing changes more regularly. This, however, had a psychosocial cost and although the patient was very pleased with the healing achieved he became socially isolated and depressed.

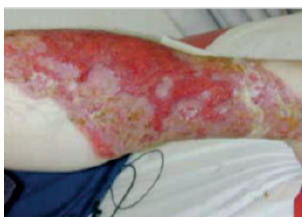

Figure 1: The patient's wound upon presentation

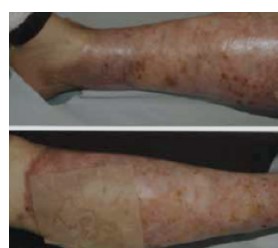

Figure 2: 18 months after change of dressing regimen and reduction in activity levels

CASE STUDY 5

CHRONIC HEAD WOUNDS IN A PATIENT WITH RDEB-SG

A 24-year-old woman with severe RDEB-SG developed chronic head wounds after an infestation with head lice as a child. The scratching following the infestation led to development of extensive wounding with lice being present under encrusted areas. The wounding and inaccessibility of some of the lice made treatments with pediculicide and/or fine-toothed combing inappropriate and potentially damaging. The wounds had been present and been gradually worsening for 6 years (Figure 1). The wounds were not healing because of recurrent infections (including with *Pseudomonas*) and possible biofilm formation. The wounds had heavy exudate with extreme leakage into aural canals and eyes, which further contributed to local infection such as conjunctivitis. The scalp was extremely sensitive and pain levels were high. She required opiates to tolerate dressing change and debridement was not a possibility due to the pain levels.

Treatment aims

- Absorb and reduce wound exudate
- Debride wounds
- Reduce malodour
- Reduce the incidence of infection

Treatment Plan

Flaminal Hydro (Flen Pharma), suitable for low exuding wounds and those at high risk of infection. It was applied as a thick layer using a soft swab and gently smeared into the scalp wounds. Although these wounds had a high level of exudate the patient was unable to tolerate Flaminal Forte (Flen Pharma) which would have been the formulation of choice. Mepitel and Mepilex Transfer (Mölnlycke Health Care) as primary and secondary dressings then held in place with Acti-Wrap (L&R) (Vandenbulcke 2006; Beele H, Durante C et al, 2012).

Outcomes

The exudate levels initially increased; the dressing was changed daily for the first 5 days. Subsequent exudate levels steadily decreased and dressing changes were reduced to every 3 days. The malodour decreased and the wounds began to debride. The patient commented that Flaminal Hydro had a cooling effect which improved comfort. Granulation tissue was noticed at the wound margins and the wounds appeared cleaner with no further evidence of infection. The wounds did not heal completely, however there was a remarkable improvement after four weeks of treatment (Figure 2).

This case study was contributed by Pauline Graham-King and Karen Snelson, EB nurse specialists, St Thomas' Hospital, London, UK

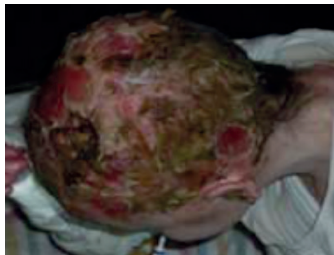

Figure 1: Wounds upon presentation

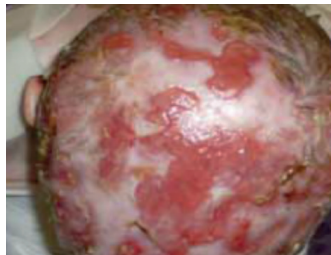

Figure 2: After four weeks of treatment with Flaminal Hydro

CASE STUDY 6

THE USE OF A HYDROGEL SHEET DRESSING IN THE MANAGEMENT OF PRURITUS AND SCARRING IN PATIENTS WITH DDEB-P

A 54-year-old patient with DDEB-P and a history of longstanding scarring to the anterior lower legs and ankles; this was tender and 'cobblestone'-like in appearance with open areas. It was intensely pruritic and the patient was sleep deprived and reported feelings of depression.

Treatment plan

A hydrogel sheet dressing (ActiFormCool, L&R) was applied over a bland moisturiser (Diprobase, Bayer) and antibacterials (Fucibet, LEO Pharma and Crystacide, Derma UK) applied to open areas. The only change in management was the application of the hydrogel sheet. The dressing was left in place for 3 days and the patient changed it after showering

Outcome

The patient reported a dramatic reduction in pruritus over his shins. This effect occurred rapidly after application of the dressing and lasted until the next application 3 days later. After the patient showered he dried his skin with a towel and a large quantity of scar tissue was removed from his legs. This was thought to be as a result of the hydrogel sheet dressing having hydrated the scar tissue and the mechanical debridement action of the towel.

*The backing to the hydrogel sheet dressing was left in place to prevent the dressing becoming desiccated as there were small volumes of exudate.

(Taken from a poster presentation: Pillay E. The use of a hydrogel sheet dressing in the management of pruritus and scarring. 2010; Wounds UK, Harrogate)

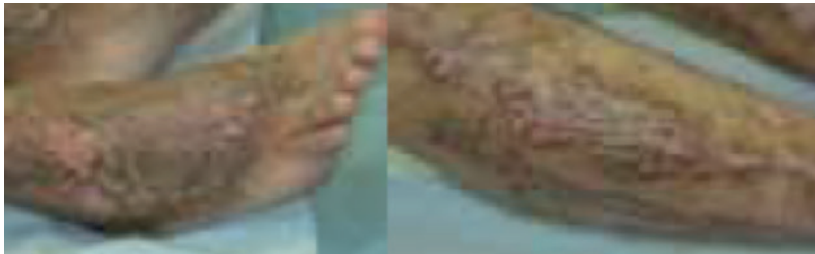

Figure 1: Patient before the application of hydrogel sheet dressings

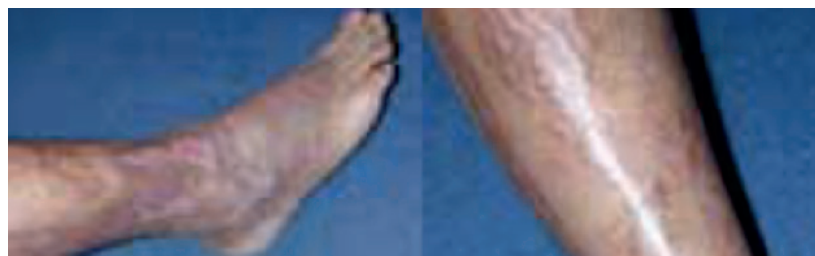
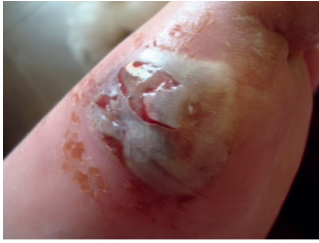
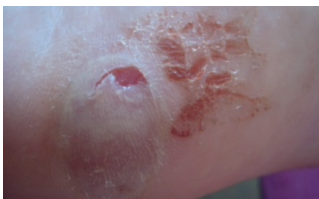Figure 2: Patient 2 months after commencement of treatment using sheet hydrogel dressings



Picture 1: Pre-KerraLite Cool



Picture 2: 5 days post KerraLite Cool

CASE STUDY 7

TREATING SEVERE BLISTERING ON THE FEET OF A CHILD WITH EBS LOCALISED

An 8-year-old girl with EBS localised developed extensive painful blisters on her feet as result of taking part in school activities during hot weather. The blisters were very painful and limited walking despite maximum oral analgesia of paracetamol, ibuprofen and tramadol.

Treatment plan

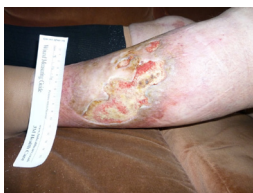The aim of the treatment was to offer comfort and pain relief while providing a suitable environment for healing. Care was taken to ensure additional damage to the blister sites and surrounding skin did not result from treatment.

The blisters were lanced with a hypodermic needle and then dressed with KerraLite Cool (Crawford Healthcare) bordered dressings.

The dressings were changed every 2 days and Silicone Medical Adhesive Remover was used to ensure atraumatic removal.

Outcomes

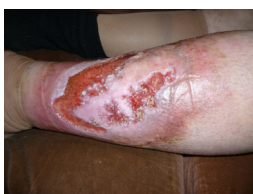Pain relief was instant and mobility increased. The dressings provided a cooling effect, which helped to reduce further heat-related blistering.



Picture 1

CASE STUDY 8

A 68-year-old male with DDEB, diabetes and oedema with lipodermatosclerosis to both lower legs who had a left partial knee replacement, right total knee replacement and ulceration on both lower legs for 2 years. The left leg ulcer deteriorated and the patient attended the practice nurse daily for dressings due to increased exudate (picture 1). Dressing regime included Atrauman (Hartmann UK) KerraMax Crawford Healthcare) dressing, and Class 2 British hosiery. A 2-week course of antibiotics resulted in a slight improvement. Wounds measured 13cmx6cm, 2.5cmx3cm, 1cmx2cm with approximately 60%–70% slough. Due to his employment on a farm the patient required a dressing regime that would enable him to wear his work boots.



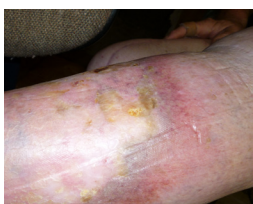Picture 2

Treatment plan

Objectives: to absorb exudate, debride the wound bed, reduce bacteria and promote wound healing

- Kytocel (Aspen Medical Europe) dressing: primary dressing, this is an antimicrobial, highly absorbent gelling fibre dressing
- Secondary KerraMax absorbent wound pad which also provides extra protection to lower leg
- Change compression hosiery to Medi Active Mens hosiery Class 2 RAL to improve venous return and reduce oedema
- Encourage leg elevation and ankle exercises to reduce oedema.

At 3 months the wound had reduced in size and exudate, the wound bed was cleaner and granulating. Unfortunately, a new wound had developed with maceration to the wound margins (picture 2). Wounds measured 9cmx3cm, 9cmx5cm with approximately 80% granulation.



Picture 3

Treatment plan

- Continue with Kytocel
- Medihoney barrier cream (Derma Sciences) to protect periwound skin from maceration
- Continue with compression therapy and leg elevation.

Outcomes

The absorbent properties of Kytocel we were able to reduce the visits to the practice nurse to 3 times a week and eventually once a week. This was time saving for the patient and cost effective.

At 6 months wound measuring 6cmx3cm with 90% granulation tissue and completely healed within a year (picture 3).

CASE STUDY 9

CASE STUDY MELLOXY (A HONEY BASED TOPICAL WOUND GEL)

A 16-year-old girl with RDEB-SG presented with a chronic wound to her shoulder, which had been present for several years. Multiple antimicrobial therapies had been used with limited success.

Melloxy (Ideal Medical Solutions) was applied to the wound daily. Initial stinging was transient.

Rapid cleansing and debridement of the wound was noted and healing progressed.

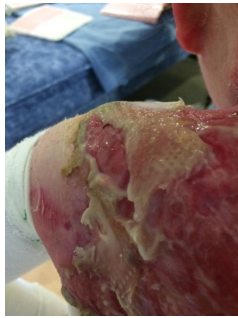

Figure 1: Pre-Melloxy treatment

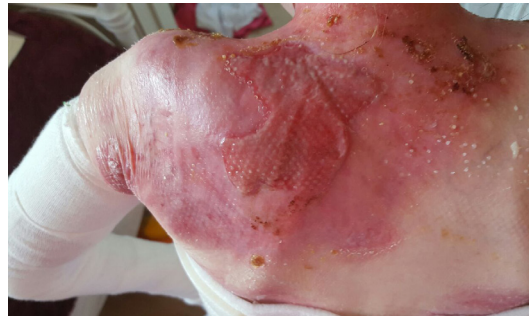

Figure 2: 8 weeks post Melloxy treatment

CASE STUDY 10

CASE STUDY — UCS DEBRIDEMENT CLOTHS

A 89-year-old male with DDEB presented with a chronic wound on lower leg. The wound bed was partially occluded by a large scab, which made it difficult to assess fully (Picture 1).

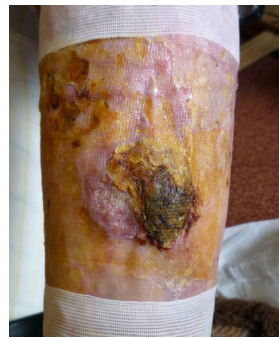Treatment plan

Remove scab and hyperkeratosis to allow wound assessment. A UCS (medi UK) pre-moistened debridement cloth was applied gently over the area for 5 minutes to soften the scab, which came off without trauma or pain enabling wound assessment (Picture 2).

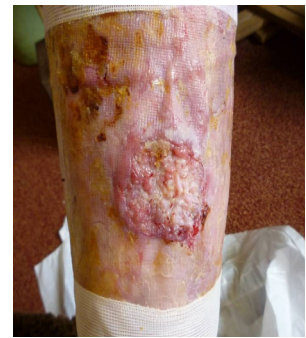Outcome

Biopsies were later taken and it was found to be a squamous cell carcinoma, which was surgically removed.

UCS wipes can be beneficial with some EB wounds to help soften hyperkeratosis and gently debrides wounds. This enables proper wound assessment and improves periwound skin.



Picture 1: Pre-UCS treatment



Picture 2: Post-UCS treatment

CASE STUDY 11

FACIAL WOUNDS IN A CHILD WITH JUNCTIONAL EB GENERALISED SEVERE

Baby D was the second child of unrelated parents. He developed inflammation of his nail beds and blistering shortly after birth and was diagnosed with JEB-GS. At 4 months of age D's main problems at the time were absent fingernails with raw nail beds and blistering in his napkin area.

Atypically of children with this diagnosis baby D ate very well and thrived. He had minimal laryngeal involvement. He required regular blood transfusions but little other medical intervention.

In common with other longer-term survivors of JEB-GS baby D developed wounds over his face, ears and the back of his head. These wounds became over granulated and the fragile tissue bled readily.

Due to the difficulty in retention of dressings and risk of self-removal resulting in trauma and possible risk to covering his airway, these wounds were treated topically and left exposed.

Wounds were treated with an antimicrobial (Flaminal Forte, Crawford Healthcare) and a very potent steroid ointment (Dermovate, GSK). Good healing was achieved over a time scale of several weeks and the skin remained intact.

The back of his head and ears were more resistant to healing and treatment was changed to topical piscine collagen (Helisorb Particles, Medira) with good results.

Sadly, Baby D passed away shortly before his third birthday following viral gastroenteritis.

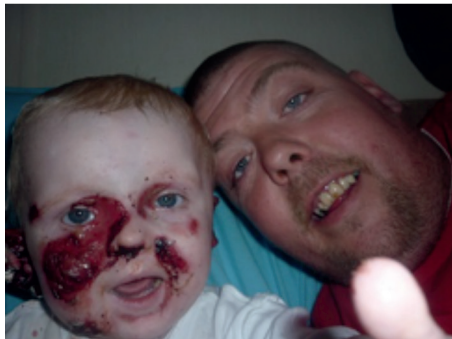

Figure 1: Pre-treatment baby D with his father

References

- Abercrombie E, Mather C and Hon J (2008) Recessive dystrophic epidermolysis bullosa, part 2: care of the adult patient. *Br J of Nurs* 17(6).
- Adni T, Martin K and Mudge E (2012) The psychosocial impact of chronic wounds on patients with severe epidermolysis bullosa. *J of Wound Care* 21(11): 528.
- Amirthalingam S, Yi KS, Ching LT and Mun NY (2015) Topical antibacterials and global challenges on resistance development. *Tropical Journal of Pharmaceutical Research* 14(5): 919-924.
- Angelis A, Kanavos P, López-Bastida PJ et al (2016) Social/economic costs and health-related quality of life in patients with epidermolysis bullosa in Europe. *The European journal of health economics: HEPAC: health economics in prevention and care* 17: 31.
- Arbuckle HA (2010). Bathing for individuals with epidermolysis bullosa. *Dermatologic Clinics* 28(2):265-268.
- Azizkhan RG, Denyer JE, Mellerio JE et al (2007) Surgical management of epidermolysis bullosa: Proceedings of the 11th International Symposium on Epidermolysis Bullosa, Santiago, Chile, 2005. *International Journal of Dermatology* 46(8): 801-808.
- Azizkhan RG, Stehr W, Cohen AP et al (2006) Esophageal strictures in children with recessive dystrophic epidermolysis bullosa: An 11-year experience with fluoroscopically guided balloon dilatation. *Journal of Pediatric Surgery* 41(1): 55-60.
- Badger KS, O'Haver J and Price H (2013) Recommendations for a comprehensive management plan for the child diagnosed with epidermolysis bullosa. *Journal of the Dermatology Nurses' Association* 5(2):72-78.
- Bauer J, Diem A, Ploder M (2013) *Efficiency and safety of using polymeric membrane wound dressing in patients with epidermolysis bullosa after a release operation*. Poster. EWMA
- Beele H, Durante C and Kerihuel JC (2012) Expert consensus on a new enzyme alginate. *Wounds UK* 8(1):64-73.
- Bernardis C and Box R (2010) Surgery of the hand in recessive dystrophic epidermolysis bullosa. *Dermatologic Clinics* 28(2):335-343.
- Blanchet-Bardon C and Bohbot S (2005) Using Urgotul dressing for the management of epidermolysis bullosa skin lesions. *Journal of Wound Care* 14(10):490.
- Blanchet-Bardon C and Bohbot S (2007) Using a novel contact layer for the management of epidermolysis Bullosa skin lesions 1409. *Journal of Wound Ostomy & Continence Nursing* 34(35):S61.
- Breitenbach JC, Gruber A, Trost B et al (2012) Deciphering the mechanism of pseudosyndactyly in recessive dystrophic epidermolysis bullosa. *Experimental Dermatology* 21(3).
- Buonocore SD and Ariyan S (2009) Cadaveric allograft for wound closure after resection of squamous cell carcinoma in patients with recessive dystrophic epidermolysis bullosa: A report of 32 resections and repairs in 2 patients. *Annals of Plastic Surgery* 63(3):297-299.
- Carbone A, Goncalves M, Grandi M, Desbordes P (2013) *Evaluation of Polymem in Chronic Wounds In Two Chilean Patients with Epidermolysis Bullosa (EB)*. Available from: <http://bit.ly/2qEjs7n> (accessed 03.05.17).
- Chiaverini C, Roger C, Fontas E et al (2016) Oral epigallocatechin-3-gallate for treatment of dystrophic epidermolysis bullosa: a multicentre, randomized, crossover, double-blind, placebo-controlled clinical trial. *Orphanet journal of rare diseases* 11:31.
- Clapham J, Pillay E (2011) *Polymeric membrane dressings contributes to improved quality of life of a patient with severe recessive dystrophic epidermolysis bullosa*. Poster. EWMA.
- del Pilar Ampuero Carbone A, Gonclaves M, Grandi MJ, Desbordes P (2013) *Evaluation of PolyMem in chronic wounds in two Chilean patients with epidermolysis bullosa*. Poster. PolyMem Chile.
- Colomb V, Bourdon-Lannoy E, Lambe C et al (2012) Nutritional outcome in children with severe generalized recessive dystrophic epidermolysis bullosa: A short- and long-term evaluation of gastrostomy and enteral feeding. *British Journal of Dermatology* 166(2):354-361.
- Daniel C, Adeduntan R, Gorell E et al (2013) Patients with epidermolysis bullosa identify pruritus as a greater problem than pain. *Pediatric Dermatology* 30(5):642-643.
- Daniel C, Adeduntan R, Gorell S, et al (2015) Prevalence and characterization of pruritus in epidermolysis bullosa. *Pediatric dermatology* 32(1):53.
- Daniel C, Adeduntan R, Gorell S et al (2015) Evaluation of Treatments for Pruritus in Epidermolysis Bullosa. *Pediatric dermatology* 32(5):628.
- Dellambra E, Vailly J, Pellegrini G et al (1998) Corrective transduction of human epidermal stem cells in laminin-5-dependent junctional epidermolysis bullosa. *Human gene therapy* 9(9):1359.
- Denyer J (2000) Management of severe blistering disorders. *Seminars in Neonatology* 5(4):321-324.
- Denyer J (2009) Management of the infant with epidermolysis bullosa. *Infant* 5(6): 185.
- Denyer J (2009) *Polymeric membrane dressings in the management of infants with epidermolysis bullosa*. Poster. EWMA
- Denyer J (2010) *Polymeric membrane dressings in the management of neonates and infants with severe forms of epidermolysis bullosa*. Poster. EWMA
- Denyer J (2010) Wound management for children with epidermolysis bullosa. *Dermatologic Clinics* 28(2):257-264.
- Denyer J (2011). Reducing pain during the removal of adhesive and adherent products. *British Journal of Nursing* 20(15).
- Denyer J (2012) Managing pain in children with epidermolysis bullosa. *Nursing Times* 108(29): 21.
- Denyer J and Stevens L (2010) Bathing in epidermolysis bullosa: Benefit over trauma? *Wounds UK* 6(2):79-84.
- Denyer J, Foster L, Turner J (2013) *Practical management of the newborn infant with severe epidermolysis bullosa*. Poster. EWMA.
- Denyer J, Foster L, Sheehan F (2014) *Epidermolysis bullosa (EB): management of the newborn infant with epidermolysis bullosa*. Available at www.gosh.nhs.uk > Health professionals > Clinical guidelines.
- Denyer J, Marsh C, Kirsner RS (2015) Keratin gel in the management of Epidermolysis bullosa. *Journal of wound care* 24(10):446.
- Dowsett C (2008) Using the TIME framework in wound bed preparation. *British journal of community nursing* 13(6):S15-16, S18, S20 passim.
- Dures E, Morris M, Gleeson K and Rumsey N (2010) You're whatever the patient needs at the time; The impact on health and social care professionals of supporting people with epidermolysis bullosa. *Chronic Illness* 6(3):215-227.
- El HM, Zambruno G, Bourdon-Lanoy E et al (2014) Multicentre consensus recommendations for skin care in inherited epidermolysis bullosa. *Orphanet journal of rare diseases* 9:76.
- Elluru G, M. Contreras M and Albert M (2013) Management of manifestations of epidermolysis bullosa. *Current opinion in otolaryngology & head and neck surgery* 21(6):588.
- Enoch S and Price P (2004) Should alternative endpoints be considered to evaluate outcomes in chronic recalcitrant wounds? *World Wide Wounds*. Available from: <http://www.worldwidewounds.com/2004/october/Enoch-Part2/Alternative-Endpoints-To-Healing.html>
- European Wound Management Association (EWMA) (2004) *Position Document: Wound Bed Preparation in Practice*. MEP Ltd: London. Available from: www.woundsinternational.com
- Falabella AF, Valencia IC, Eaglstein WH and Schachner LA (2000) Tissue-engineered skin (Apligraf) in the healing of patients with epidermolysis bullosa wounds. *Archives of Dermatology* 136(10):1225-1230.
- Fine JD (2004) Possible role for sentinel node biopsy in the management of squamous cell carcinomas in inherited epidermolysis bullosa. *Archives of dermatology* 140(8):1012.
- Fine JD, Bruckner-Tuderman L, Eady AJ, Bauer A, Bauer W, et al (2014) Inherited epidermolysis bullosa: updated recommendations on diagnosis and classification. *Journal of the American Academy of Dermatology* 70(6):1103.
- Fine JD, Johnson B, Weiner M, Stein A, Cash S et al (2004) Genitourinary complications of inherited epidermolysis bullosa: experience of the national epidermolysis bullosa registry and review of the literature. *The Journal of urology* 172(5):2040.
- Fine JD, Manes B and Frangoul H (2015) Systemic granulocyte colony-stimulating factor (G-CSF) enhances wound healing in dystrophic epidermolysis bullosa (DEB): Results of a pilot trial. *Journal of the American Academy of Dermatology* 73(1):56.
- Fine JD and Mellerio E (2009) Extracutaneous manifestations and complications of inherited epidermolysis bullosa: part I. Epithelial associated

- tissues. *Journal of the American Academy of Dermatology* 61(3):367.
- Fine JD and Mellerio E (2009) Extracutaneous manifestations and complications of inherited epidermolysis bullosa: part II. Other organs. *Journal of the American Academy of Dermatology* 61(3):387.
- Fine JD (2010) Inherited epidermolysis bullosa. *Orphanet journal of rare diseases* 5(1).
- Fine JD, Johnson LB, Weiner M, Li KP and Suchindran C (2009) Epidermolysis bullosa and the risk of life-threatening cancers: The National EB Registry experience, 1986–2006. *Journal of the American Academy of Dermatology* 60(2):203–211.
- Fine JD, Johnson LB, Weiner M, Stein A, Cash S et al (2005) Pseudosyndactyly and musculoskeletal contractures in inherited epidermolysis bullosa: Experience of the national epidermolysis bullosa registry, 1986–2002. *Journal of Hand Surgery* 30(1):14–22.
- Fine JD, Johnson LB, Weiner M and Suchindran C (2004) Assessment of mobility, activities and pain in different subtypes of epidermolysis bullosa. *Clinical & Experimental Dermatology* 29(2):122–127.
- Fivenson DP, Scherschun L, Choucair M, KuKuruga D, Young J and Shwayder T (2003). Graftskin therapy in epidermolysis bullosa. *Journal of the American Academy of Dermatology* 48(6):886–892.
- Formsma SA, Maathuis CBG, Robinson PH and Monkman MF (2008). Postoperative hand treatment in epidermolysis bullosa. *Journal of Hand Therapy* 21(1):80–86.
- Gethin G, Grocott P, Probst S and Clarke E (2014) Current practice in the management of wound odour: an international survey. *International journal of nursing studies* 51(6): 865.
- Glaziou P, Nyguyen LN, Moulia-Pelat JP, Cartel JL and Martin PM (1994) Efficacy of ivermectin for the treatment of head lice (*Pediculus capitis*). *Tropical medicine and parasitology* 45(3):253–4.
- Goldschneider K, Lucky AW, Mellerio JE, Palisson F, Del MM and Azizkhan RG (2010) Perioperative care of patients with epidermolysis bullosa: Proceedings of the 5th international symposium on epidermolysis bullosa, Santiago Chile, December 4–6, 2008. *Paediatric Anaesthesia* 20(9):797–804.
- Goldschneider KR and Lucky AW (2010). Pain management in epidermolysis bullosa. *Dermatologic clinics* 30;28(2):273–82.
- Goldschneider R, Good J, Harrop E, Lioffi C, Lynch-Jordan A et al (2014) Pain care for patients with epidermolysis bullosa: best care practice guidelines. *BMC medicine* 12:178.
- Gonzalez E (2013) Evaluation and treatment of the newborn with epidermolysis bullosa. *Seminars in Perinatology* 37(1):32–40.
- Gorell S, Leung H, Khuu P and Lane T (2015) Purified type I collagen wound matrix improves chronic wound healing in patients with recessive dystrophic epidermolysis bullosa. *Pediatric dermatology* 32(2):220.
- Grocott P (2000). The palliative management of fungating malignant wounds. *Journal of wound care* 9(1): 4.
- Grocott P, Blackwell R, Currie C, Pillay E, Clapham J et al (2013) Woundcare Research for Epidermolysis Bullosa: Designing Products with the Users. *Dermatological Nursing* 12(1):30.
- Grocott P, Gethin G and Probst S (2013) Malignant wound management in advanced illness: new insights. *Current opinion in supportive and palliative care* 7(1): 101.
- Hasegawa T, Mizoguchi M, Haruna K, Mizuno Y, Muramatsu S et al (2007) Amnion for intractable skin ulcers with recessive dystrophic epidermolysis bullosa: Report of three cases. *Journal of Dermatology* 34(5):328–332.
- Haynes L (2010). Nutrition for children with epidermolysis bullosa. *Dermatologic clinics* 28(2):289.
- Haynes L, Mellerio JE and Martinez AE (2012) Gastrostomy tube feeding in children with epidermolysis bullosa: Consideration of key issues. *Pediatric Dermatology* 29(3):277–284.
- Haynes L (2010) Nutrition for children with epidermolysis bullosa. *Dermatologic Clinics* 28(2):289–303.
- Herod J, Denyer J, Goldman A and Howard R (2002) Epidermolysis bullosa in children: Pathophysiology, anaesthesia and pain management. *Paediatric Anaesthesia* 12(5):388–397.
- Hollinworth H (2009) Challenges in protecting peri-wound skin. *Nursing Standard* 24(7): pp53–62.
- Hon J (2005) Using honey to heal a chronic wound in a patient with epidermolysis bullosa. *British Journal of Nursing* 14(19).
- Huang T, Abrams M, Tlougan B, Rademaker A and Paller S (2009) Treatment of *Staphylococcus aureus* colonization in atopic dermatitis decreases disease severity. *Pediatrics* 123(5).
- Hubbard L, Haynes L, Sklar M, Martinez AE and Mellerio JE (2011) The challenges of meeting nutritional requirements in children and adults with epidermolysis bullosa: Proceedings of a multidisciplinary team study day. *Clinical and Experimental Dermatology* 36(6):579–584.
- Jain S S and De Lisa JA (1988) Successful prosthetic fitting of a patient with epidermolysis bullosa dystrophica. Case report. *American Journal of Physical Medicine and Rehabilitation* 67(3):104–107.
- Jeon IK, On HR and Kim SC (2016) Quality of Life and Economic Burden in Recessive Dystrophic Epidermolysis Bullosa. *Annals of dermatology* 28(1):6.
- Khan MT (2010) Podiatric management in epidermolysis bullosa. *Dermatologic Clinics* 28(2):325–336.
- Kirkorian AY, Weitz A, Tlougan B and Morel D (2014) Evaluation of wound care options in patients with recessive dystrophic epidermolysis bullosa: a costly necessity. *Pediatric dermatology* 31(1):33.
- Kirsner S, Cassidy S, Marsh C, Vivas A and Kelly J(2012) Use of a keratin-based wound dressing in the management of wounds in a patient with recessive dystrophic epidermolysis bullosa. *Advances in skin & wound care* 25(9):400.
- Krämer SM et al (2012) Oral Health Care for Patients with Epidermolysis Bullosa - Best Clinical Practice Guidelines. *International Journal of Paediatric Dentistry* (2012) 22, 1–35
- Krakowski C and Ghasri P (2015) Case report: rapidly healing epidermolysis bullosa wound after ablative fractional resurfacing. *Pediatrics* 135(1).
- Kurgys Z, Eros G, Nemeth IB, Csizmazia E, Berko S et al (2013) The irritant effects of pharmaceutical excipients used in topical formulations. *Journal of Investigative Dermatology* 133:ppS124–S124.
- Lai-Cheong E and McGrath A (2010) Kindler syndrome. *Dermatologic clinics* 28(1):119.
- Lai-Cheong E and McGrath A (2011) What is Kindler syndrome? *Skinmed* 9(3):145.
- Laimer M, Lanschuetzer M, Diem A and Bauer W (2010) Herlitz junctional epidermolysis bullosa. *Dermatologic clinics* 28(1):55–60.
- Lara-Corrales I, Arbuckle A, Zarinehbab S and Pope E (2010) Principles of wound care in patients with epidermolysis bullosa. *Pediatric Dermatology* 27(3): 229–237.
- Lara-Corrales I, Parkin C, Stephens D, JHamilton J, Koren G et al (2012) The efficacy of trimethoprim in wound healing of patients with epidermolysis bullosa: a feasibility trial. *Journal of the American Academy of Dermatology* 66(2):264–70.
- Lo V, Lara-Corrales I, Stuparich A and Pope E (2010) Amniotic membrane grafting in patients with epidermolysis bullosa with chronic wounds. *Journal of the American Academy of Dermatology* 62(6): 1038–44.
- Ly L and Su JC (2008) Dressings used in epidermolysis bullosa blister wounds: a review. *Journal of wound care* 17(11):482, 484–6, 488.
- Martinez A E and JMellerio JE (2010) Osteopenia and osteoporosis in epidermolysis bullosa. *Dermatologic Clinics* 28(2):353–55.
- Mather C and Denyer J (2008) Removing dressings in epidermolysis bullosa. *Nursing Times* 104(14):46.
- McGrath JA, Schofield OM, Ishida-Yamamoto A, O'Grady A, Mayou BJ et al (1993) Cultured keratinocyte allografts and wound healing in severe recessive dystrophic epidermolysis bullosa. *Journal of the American Academy of Dermatology* 29(3):407–19.
- Mellerio JE (2010) Infection and colonization in epidermolysis bullosa. *Dermatologic Clinics* 28(2):267–9
- Mellerio JE, Robertson SJ, Bernardis C, Diem A, Fine JD et al (2016) Management of cutaneous squamous cell carcinoma in patients with epidermolysis bullosa: best clinical practice guidelines. *The British journal of dermatology* 174(1):56.
- Mellerio JE, Weiner M, Denyer J, Pillay E, Lucky AW et al (2007) Medical management of epidermolysis bullosa: Proceedings of the 2nd International Symposium on Epidermolysis Bullosa, Santiago, Chile, 2005. *International*

References

- Journal of Dermatology* 46(8):795–800.
- Montaudie H, Chiaverini C, Sbidian E, Charlesworth A and Lacour JP (2016) Inherited epidermolysis bullosa and squamous cell carcinoma: a systematic review of 117 cases. *Orphanet J Rare Dis* 11(1):117.
- Morash D and Fowler K (2004) An evidence-based approach to changing practice: using sucrose for infant analgesia. *Journal of pediatric nursing* 19(5):366.
- Moss K (2008) Contact at the borderline: psychoanalytic psychotherapy with EB patients. *British Journal of Nursing* 17(7):449.
- Moy JA, Caldwell-Brown D, Lin AN, Pappa KA and Carter DM (1990) Mupirocin-resistant *Staphylococcus aureus* after long-term treatment of patients with epidermolysis bullosa. *Journal of the American Academy of Dermatology* 22(5 1):893–5.
- Nagoba B, Wadher B, Kulkarni P and Kolhe S (2008) Acetic acid treatment of pseudomonal wound infections. *European Journal of General Medicine* 5(2):104–6.
- Nagoba BS, Selkar SP, Wadher BJ and Gandhi RC (2013) Acetic acid treatment of pseudomonal wound infections: A review. *Journal of Infection and Public Health* 6(6):410–5.
- Nakano A, Chao SC, Pulkkinen L, Murrell D, Bruckner-Tuderman L, Pfendner E and Uitto J (2002) Laminin 5 mutations in junctional epidermolysis bullosa: molecular basis of Herlitz vs. non-Herlitz phenotypes. *Human genetics* 110(1):41.
- Ng FYH, Nguyen C and Curtin CM (2014) Squamous Cell Carcinoma in a Patient With Dystrophic Epidermolysis Bullosa: A Wound Management Strategy. *Dermatologic Surgery* 40(8): pp918–920.
- National Eczema Society. *Ask-the-experts session*. NES Conference, 2010. <http://www.eczema.org>
- National Institute of Health and Care Excellence (NICE) (2014) *Pressure ulcers: prevention and management*. NICE guideline [179]
- Naylor W (2000) Symptom self-assessment in the management of fungating wounds: Part 2. *World Wide Wounds*. Available from: <http://www.worldwidewounds.com/2002/july/Naylor-Part2/Wound-Assessment-Tool>.
- Pereira J and Phan T (2004) Management of bleeding in patients with advanced cancer. *The oncologist* 9(5):561.
- Petersen B W, Arbuckle A and Berman S (2015) Effectiveness of saltwater baths in the treatment of epidermolysis bullosa. *Pediatric dermatology* 32(1):60.
- Petrof G, Martinez-Queipo M, Mellerio JE, Kemp P and McGrath JA (2013) Fibroblast cell therapy enhances initial healing in recessive dystrophic epidermolysis bullosa wounds: results of a randomized, vehicle-controlled trial. *The British journal of dermatology* 169(5):1025.
- Phillips PL, Wolcott RD, Fletcher J, Schultz GS (2010) *Biofilms Made Easy*. Wounds International 1(3). Available from: www.woundsinternational.com
- Pillay E, Hon J (2007) *The use of a low-air loss pressure relieving surface in the management of epidermolysis bullosa*. Poster. Wounds UK, Harrogate, UK.
- Pillay E (2008). Epidermolysis bullosa, part 1: causes, presentation and complications. *British Journal of Nursing* 17(5):292.
- Pillay E (2009) *Investigating the use of polymeric membrane dressings on recalcitrant wounds in epidermolysis bullosa*. Poster. EWMA
- Pope E, Lara-Corrales I, Mellerio JE, Martinez A, Schultz G et al (2012) A consensus approach to wound care in epidermolysis bullosa. *Journal of the American Academy of Dermatology* 67(5):904–17.
- Pope E, Lara-Corrales I, Mellerio JE, Martinez AE, Sibbald C and Sibbald RG (2013) Epidermolysis Bullosa and Chronic Wounds: A Model for Wound Bed Preparation of Fragile Skin. *Advances in Skin & Wound Care* 26(4):177–189.
- Ranugha PS, Mohanan S, Chandrashekar L, Basu D, Thappa DM and Rajesh NG (2014) Epidermolysis bullosa pruriginosa showing good response to low-dose thalidomide — a report of two cases. *Dermatologic therapy* 27(1):60.
- Schober-Flores C (2003) Epidermolysis bullosa: the challenges of wound care. *Dermatology nursing* 15(2):135–8, 141–4.
- Schober-Flores C (2009) Epidermolysis Bullosa: Wound Care Pearls for the Noninfected and Infected Wound. *Journal of the Dermatology* 1(1):21–8.
- Schober-Flores C (2014) Epidermolysis Bullosa: The Challenges of a Chronic Wound. *Journal of the Dermatology* 6(4):199–205.
- Schultz G, Sibbald RG, Falanga V, Ayello EA, Dowsett C et al (2003) Wound bed preparation: A systematic approach to wound management. *Wound Repair Regen* 11(Suppl1):S1–S28.
- Sibbald RG, Elliott A, Ayello A and Somayaji R (2015) Optimizing the Moisture Management Tightrope with Wound Bed Preparation 2015. *Advances in skin & wound care* 28(10):466.
- Sibbald RG, Zuker R, Coutts P, Coelho S, Williamson D and Queen D (2005) Using a dermal skin substitute in the treatment of chronic wounds secondary to recessive dystrophic epidermolysis bullosa: a case series. *Ostomy wound management* 51(11):22–46.
- Snauwaert J, Morren MA and Moons P (2011) Characteristics of itch in the different populations with epidermolysis bullosa using the Leuven itch scale. *Acta Dermato-Venereologica* 91(5).
- Snauwaert J, Yuen WY, Jonkman MF, Moons P, Naulaers G and Morren MA (2014) Burden of itch in epidermolysis bullosa. *The British journal of dermatology* 171(1):73.
- Snelson K, Clapham J (2011) *Guidelines for the practical care of adult patients with epidermolysis bullosa during surgical procedures*. DEBRA.
- Spiliopoulos S, Sabharwal T, Krokidis M, Gkoutzios P, Mellerio JE, Dourado R and Adam A (2012) Fluoroscopically guided dilation of esophageal strictures in patients with dystrophic epidermolysis bullosa: long-term results. *American journal of roentgenology* 199(1):208.
- Stephen-Haynes J (2008) Skin integrity and silicone: Appeal 'no-sting' medical adhesive remover. *British journal of nursing* 17(12):792.
- Stevens J (2014) Access to wound dressings for patients living with epidermolysis bullosa — an Australian perspective. *International wound journal* 11(5):505.
- Stevens J (2009). Management of epidermolysis bullosa (EB) skin lesions with a non-adherent dressing, UrgoTul. *Wound Practice & Research* 17(2):72–6.
- Swartling C, Karlqvist M, Hymnelius K, Weis J and Vahlquist A (2010) Botulinum toxin in the treatment of sweat-worsened foot problems in patients with epidermolysis bullosa simplex and pachyonychia congenita. *The British journal of dermatology* 163(5):1072.
- Tadini G, Pezzani L, Ghirardello S, Rebulli P, Esposito S and Mosca F (2015) Cord blood platelet gel treatment of dystrophic recessive epidermolysis bullosa. *BMJ case reports*.
- Than P, Smith RA, Cassidy S, Kelly R, Marsh C, Maderal A and Kirsner S (2013) Use of a keratin-based hydrogel in the management of recessive dystrophic epidermolysis bullosa. *The Journal of dermatological treatment* 24(4):290.
- Thomas D R, McCarroll L, Roberts R, Karunaratne P, Roberts C et al (2006) Surveillance of insecticide resistance in head lice using biochemical and molecular methods. *Archives of disease in childhood* 91(9):777.
- Uitto J, Richard G and McGrath A (2007) Diseases of epidermal keratins and their linker proteins. *Experimental cell research* 313(10):1995.
- Van C, Lettinga AT, Duipmans JC, Maathuis CGB and Jonkman MF (2008) Main problems experienced by children with epidermolysis bullosa: A qualitative study with semi-structured interviews. *Acta Dermato-Venereologica* 88(2):143–150.
- Van den Bergh F and Giudice GJ (2002) BP180 (type XVII collagen) and its role in cutaneous biology and disease. *Advances in dermatology* 19: 37–71.
- van der Kooi-Pol MM, Duipmans JC, Jonkman MF and van Dijk JM (2014) Host-pathogen interactions in epidermolysis bullosa patients colonized with *Staphylococcus aureus*. *International Journal of Medical Microbiology* 304(2):195–203.
- van Scheppingen C, Lettinga AT, Duipmans JC, Maathuis KG and Jonkman MF (2008) The main problems of parents of a child with epidermolysis bullosa. *Qualitative health research* 18(4):545–556.
- Vandenbulcke K (2006) Evaluation of the antibacterial activity and toxicity of two new hydrogels: A pilot study. *Int J Lower Extrem Wounds* 5(2):109–114.
- Velarde C, Demaria M, Melov S and Campisi J (2015) Pleiotropic age-dependent effects of mitochondrial dysfunction on epidermal stem cells. *Proceedings of the National Academy of Sciences of the United States of America* 112(33):10407.
- Venugopal S, Intong RA, Cohn I, Mather-Hillon J and Murrell F (2010) Responsiveness of non-Herlitz junctional epidermolysis bullosa to topical gentian violet. *International journal of dermatology* 49(11):1282.
- Venugopal S S and Murrell DF (2010) Treatment of skin cancers in

epidermolysis bullosa. *Dermatologic Clinics* 28(2):283-7.

Wally V, Kitzmueller S, Lagler F, Moder A, Hitzl W et al (2013) Topical diacerein for epidermolysis bullosa: a randomized controlled pilot study. *Orphanet journal of rare diseases* 8:69.

Watterson G, Howard R and Goldman A (2004) Peripheral opioids in inflammatory pain. *Archives of Disease in Childhood* 89(7):679-681.

Weiner M S (2004) Pain management in epidermolysis bullosa: an intractable problem. *Ostomy wound management* 50(8):13-14.

Westgate S, Cutting KF, DeLuca G, Asaad K (2012) Collagen dressings Made Easy. *Wounds UK* 8:1.

World Union of Wound Healing Societies (WUWHS) (2007) *Principles of best practice: Wound Exudate and the Role of Dressings. A Consensus Document*. MEP Ltd. London. Available from: www.woundsinternational.com

World Union of Wound Healing Societies (WUWHS) (2016), *Florence Congress Position Document. Management of Biofilm*. Wounds International. London.

Yuen W Y, Huizinga J and Jonkman F (2013) Punch grafting of chronic ulcers in patients with laminin-332-deficient, non-Herlitz junctional epidermolysis bullosa. *Journal of the American Academy of Dermatology* 68(1):93.

Notes



Wounds_{UK}

A Wounds UK publication

www.wounds-uk.com